

Catechin Hydrate Improves Hypertrophic Scar in Rabbit Ear Model via Reduction of Collagen Synthesis

Sina Goudarzi Afshar¹, Pari Tamri*¹, Alireza Nourian², Ayoub Moahmoudi¹

Abstract

Background: Hypertrophic scar (HS) is a cutaneous condition results from abnormal wound healing following deep tissue injury. To date, there is no optimal treatment for this skin disorder. Catechins possess anti-inflammatory, antioxidant and anti-fibrotic properties. In this study we investigated the effects of catechin hydrate (CH) in rabbit ear model of HS.

Methods: A rabbit ear model of hypertrophic scar was set up. Ten New Zealand white rabbit were divided into 5 equal groups: non-treatment group, vehicle control, treated with intralesional injection of dimethyl sulfoxide (DMSO), and test groups, received intralesional injection of CH/DMSO solution at concentration of 0.25, 1.25 and, 2.5 mg/ml, respectively. The treatments were initiated 35 days after wounding once a week for 4 weeks. The scar elevation index (SEI) and the epidermal thickness index (ETI) were measured using Hematoxylin and Eosin (H&E) staining and the amount of collagen deposition were determined after Masson' trichrome staining. In addition, the enzyme-linked immunosorbent assay (ELISA) method was used to determine the levels of type I and III collagen and matrix metalloproteinase 1 (MMP1) in scar tissues.

Results: CH improved abnormal scarring at concentrations of 1.25 and 2.5 mg/ml and significantly ($P<0.001$) reduced the SEI and ETI. The levels of collagen type I and type III, and total collagen deposition were significantly ($P<0.05$) decreased in scar tissues of CH treated groups and no significant effect on MMP1 levels.

Conclusion: Our findings demonstrated that CH has the potential for the treatment of HSs.

Keywords: Catechin, Collagen, Hypertrophic scar, Rabbit, Wound healing.

Introduction

Hypertrophic scars (HSs) are proliferative skin disorders that occur after abnormal wound healing in inclined individuals following surgery, trauma, inflammation, and especially burns. HSs are raised, itchy, inflamed, red or purple in color, and may be painful (1). HSs are recognized as difficult to treat, and are at high risk of relapse (2).

In predisposed individuals, the most important cause of hypertrophic scar is damage to reticular dermis by trauma, burns or surgery. The reticular dermis in hypertrophic scar demonstrates chronic

inflammation, notable angiogenesis and copious amount of collagen (3). The total collagen content is increased in HSs (4). It has been shown that collagen type I and type III are both increased in hypertrophic scars comparing to normal skin (5, 6).

The physical characteristics of hypertrophic scars are the result of disordered organization of narrow collagen fibers. In HS collagen fibers are arranged in a more disorganized manner, whereas in normal skin and normotrophic scars, the collagen fibers are bundled and are paralleled with the

1: Department of Pharmacology & Toxicology, School of Pharmacy, Hamadan University of Medical Sciences, Hamadan, Iran.

2: Department of Laboratory Sciences, Faculty of Para-Veterinary Sciences, Bu-Ali Sina University, Hamadan, Iran.

*Corresponding author: Pari Tamri; Tel: +98 8138381590; E-mail: p.tamri@umsha.ac.ir.

Received: 5 Feb, 2024; Accepted: 3 Mar, 2024

epithelial surface (7).

Inflammation is one of the most important factors influencing wound healing process. Persistent inflammation is one of the HS characteristics (8). According to findings of many studies, inflammation modulates collagen synthesis, and the severity of inflammation has a direct relationship with the final size of the scar (9-11). Considering the contribution of inflammation in the HS formation, it seems logical to use agents that target inflammation to treat and prevent abnormal scar formation. The anti-scarring effects of many anti-inflammatory compounds such as Pirfenidone, epigallocatechin-3-gallate have been reported (12).

Although there are several clinical treatments for HS such as intralesional and topical steroid, radiation therapy, Silicone gel sheet, topical and intralesional 5-fluorouracil and surgery (13), all these treatments are associated with possible side effects and they have some limitation: medications are not specific for HS, the rate of scar recurrence after surgery is high, and a more severe scar may occur after surgery, hyperpigmentation, skin atrophy and telangiectasia following intralesional injection of steroids and 5-fluorouracil and radiotherapy (14, 15). That being so, finding new treatments for the rapid and effective improvement of hypertrophic scars is absolutely necessary.

Catechin is a flavan-3-ol occurs naturally in many plants including green tea, persimmons, apples, beans, peaches, berries, and black grapes. The antioxidant activity, anticancer and anti-inflammation effects of catechins have been reported (16, 17). In addition, the anti-fibrotic effects of catechins have been shown in several studies (18-20).

This work aimed to investigate the effects of intralesional injection of CH on hypertrophic scar in rabbit ear model.

Materials and Methods

Animals and reagents

Ten New Zealand white rabbits including male and female animals with weight of 2.5 to 3 kg

were used in this experimental research. The rabbits were housed individually in standard cages, a week before and during experiment. Standard conditions of temperature (22±2), relative humidity (55% ±2%) and 12:12 h dark/light cycle was provided, and animals accessed to standard food and water *ad libitum*. The experimental protocol was approved by the research ethics committee of Hamadan University of Medical Sciences (IR.UMSHA.REC.1399.944).

Catechin hydrate (≥96% pure, CAS Number: 225937-10-0) and Dimethyl Sulfoxide (DMSO) (CAS number 68-67-5) were purchased from Sigma-Aldrich, USA.

Hypertrophic scarring in rabbit ear

The hypertrophic scars were induced in rabbits' ears by biopsy punch (10 mm diameter) (21). Before wound creation, ketamine (80 mg/ml) and xylazine (10 mg/kg) were injected intraperitoneally to anesthetize the rabbits, the hairs in the wound area were shaved and the wounds sites were disinfected by ethanol 70%. Four wounds were created in each rabbit ear (8 wounds in each rabbit)

Animal groups and treatments

Animals randomly, divided into five equal groups as follow: non-treatment group, vehicle control group, received weekly intralesional injection of DMSO (50 µl) for four weeks and test groups, received weekly intralesional injection of 0.25, 1.25 and 2.5 mg/ml (50 µl) solutions of CH/DMSO, respectively, for four weeks (22, 23). The treatments were initiated 35 days after wound creation and when hypertrophic scar formation was confirmed through macroscopic and histological evaluation. The CH doses were selected on the basis of a pilot study. There were 1 male and 1 female rabbit in each group.

The scar tissue samples were taken from each group one week after last injection. Samples obtained from all wounds. A half of samples were maintained in formalin 10% and the remaining samples were kept at -80 °C after being frozen in liquid nitrogen until use.

Measurement of epidermal thickness index (ETI) and Scar elevation index (SEI)

For measurement of ETI and SEI the samples were stained using hematoxylin-eosin (H&E) method (24) and were studied using a light microscope to ensure that each sample have some unwounded tissue adjacent to scar tissue. Micrographs (400X) were taken from samples by using a digital camera. The epidermal thickness was calculated as micrometer using ImageJ^R software. ETI was the ratio of epidermal thickness of scar tissue to that of adjacent unwounded tissue. The $ETI > 1$ indicated the epidermal hypertrophy (25). Scar elevation index (SEI) was measured as the ratio of wound tissue height to adjacent unwounded tissue height in each sample. $SEI > 1$ showed the hypertrophic scar formation (26). The tissue height was measured using ImageJ^R software.

Collagen type I and type III and MMP1 assay

The collagen type I and type III and MMP1 concentrations in tissue samples obtained from experimental groups were measured by ELISA method using rabbit collagen type I and type III and MMP1 ELISA kits (Shanghai Crystal day Biotech Co. China) using manufacturer's instructions.

Estimation of collagen deposition

Masson's trichrome staining method was performed to evaluate collagen deposition in

scar tissues obtained from experimental groups. In this staining method, the collagen fibers turn in blue color. ImageJ^R software was use to quantification of collagen fibers in scar tissue samples as described previously (27). Briefly, microphotographs of scar tissue were converted to RGB (red, green, blue) layers by ImageJ^R program and the average percentage of collagen deposition was calculated for each group. The percentage of collagen deposition is defined as the ratio of blue area pixels to total area pixels.

Statistical analysis

The results were shown as Mean \pm Standard Error of mean. Statistical data analysis was conducted using one- way Analysis of variance (ANOVA) following multiple comparisons test with GraphPad Prism 8. P values less than 0.05 were deemed to be statistically significant.

Results

Macroscopic evaluation of hypertrophic scars

On day 63 (7 days after last injection), the scar tissues of non-treatment and DMSO treated groups were raised, showing red-brown color and a tensile texture, while in CH 1.25 and 2.5 mg/ml treated groups the scars were almost the same level as normal skin, their color was similar to normal skin and they had a softer texture. CH 0.25 mg/ml was not so effective to change the scar tissue appearance (Fig. 1).

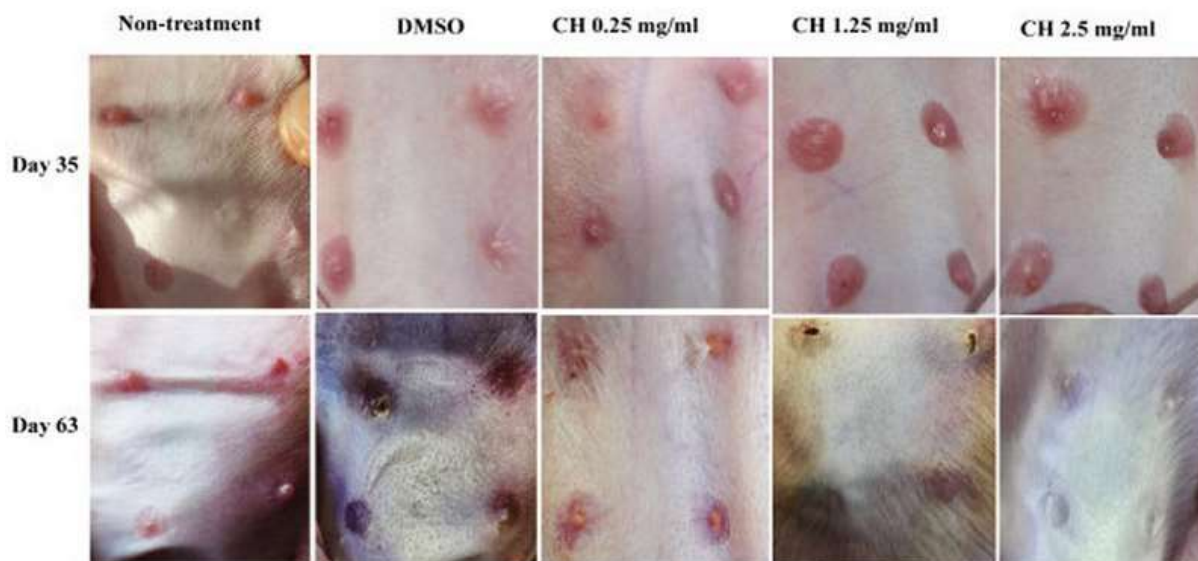


Fig. 1. Images of hypertrophic scars on day 35 post wounding (before treatment initiation), and on day 63 (one week after last injection).

Microscopic evaluation of scar tissue

Histopathological study of the scar tissue samples obtained from non-treatment, DMSO and CH 0.25 mg/ml treated groups indicated the thicker epidermis and dermis layers, more edema, presence of inflammatory cells and vertical oriented blood vessels comparing with

those of CH 1.25 and 2.5 mg/ml treated groups which had significant reduced edema and inflammation. In addition, the arrangement of collagen fibers in the samples obtained from CH 1.25 and 2.5 mg/ml groups was more regular compared with non-treatment and vehicle control groups (Fig. 2).

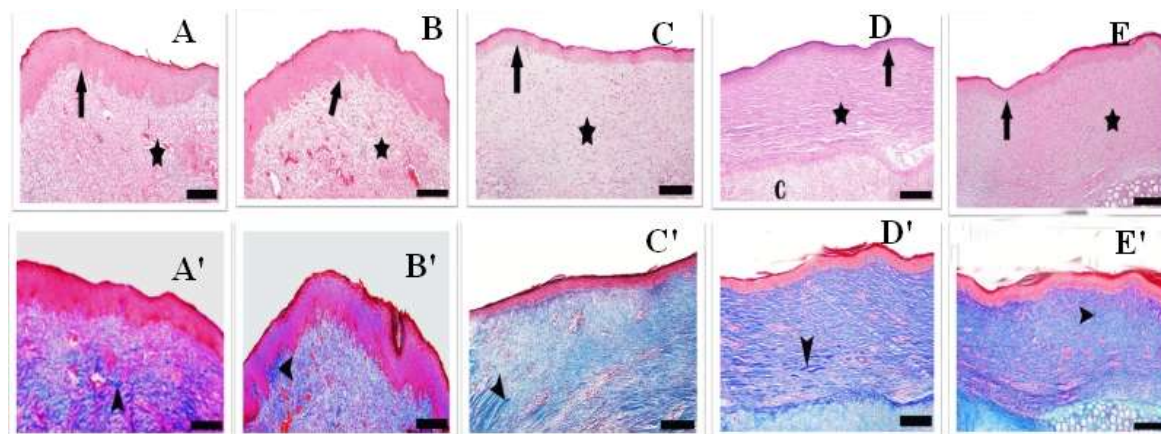


Fig. 2. Micrographs of hypertrophic scar tissues. A-E represent the H&E staining images of hypertrophic scar tissues of control, DMSO, CH 0.25 mg/ml, 1.25 mg/ml and 2.5 mg/ml treated groups, respectively. A'-E' represent Masson's trichrome staining images of control, DMSO, CH 0.25 mg/ml, 1.25 mg/ml and 2.5 mg/ml treated groups, respectively. Magnification: 100X, Scale bar: 200 μ m, Asterisk: granulation tissue, Arrow tip: collagen, Arrow: epidermis.

Effects of CH on ETI and SEI

Evaluation of the effect of CH on ETI and SEI showed that intralesional injection of CH 1.25 and 2.5 mg/ml significantly ($P < 0.001$) reduced the ETI comparing to non-treatment and vehicle control groups (Fig. 3A). The results of the SEI measurement showed that averages

SEI of CH 1.25 and 2.5 mg/ml treated groups were significantly ($P < 0.001$) lower than those of non-treatment and vehicle control groups (Fig. 3B). There were no significant differences in the averages of ETI and SEI among non-treatment, vehicle control and CH 0.25 mg/ml treated groups.

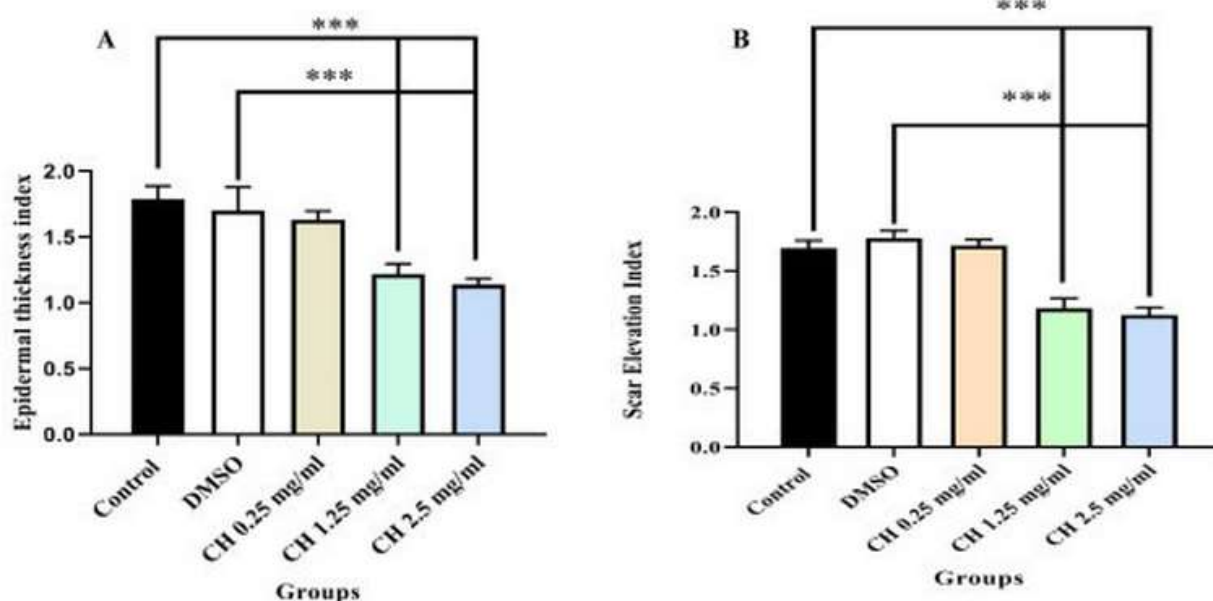


Fig. 3. A. Epidermal thickness index and B. Scar elevation index in studied groups. Data are shown as Mean \pm SEM, *** ($P < 0.001$) indicates the statistically significant difference ($n = 4$).

Effect of CH on collagen type I and type III levels

The collagen type I (Fig. 4) and type III (Fig. 5) concentrations in scar tissue samples obtained from CH 1.25 and 2.5 mg/ml treated scars were significantly ($P < 0.05$) lower than

those of non-treatment and vehicle control groups. No significant differences were observed in collagen type I and type III concentrations among CH .0.25 mg/ml, non-treatment and vehicle control groups.

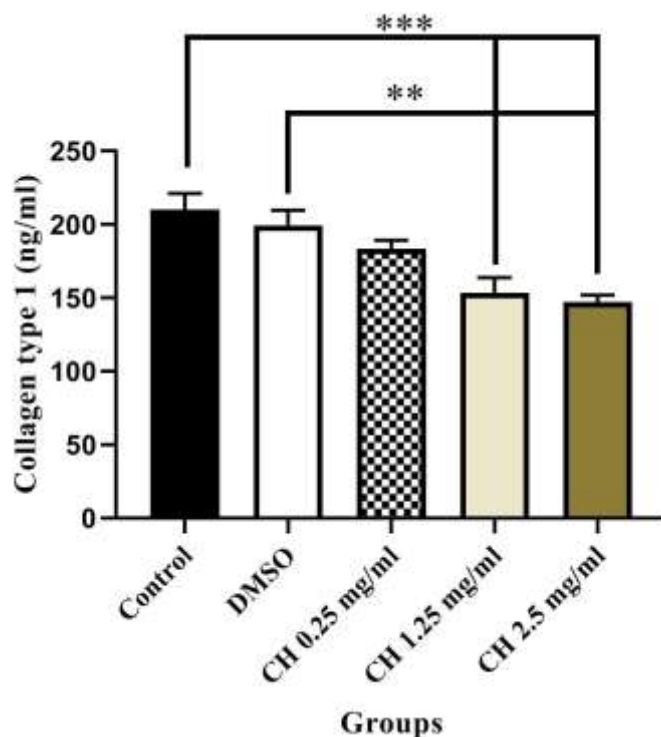


Fig. 4. The average levels of collagen type I in experimental groups. Data are shown as Mean±SEM, *** ($P < 0.001$) and ** ($P < 0.01$) indicates statistically significant difference ($n=4$).

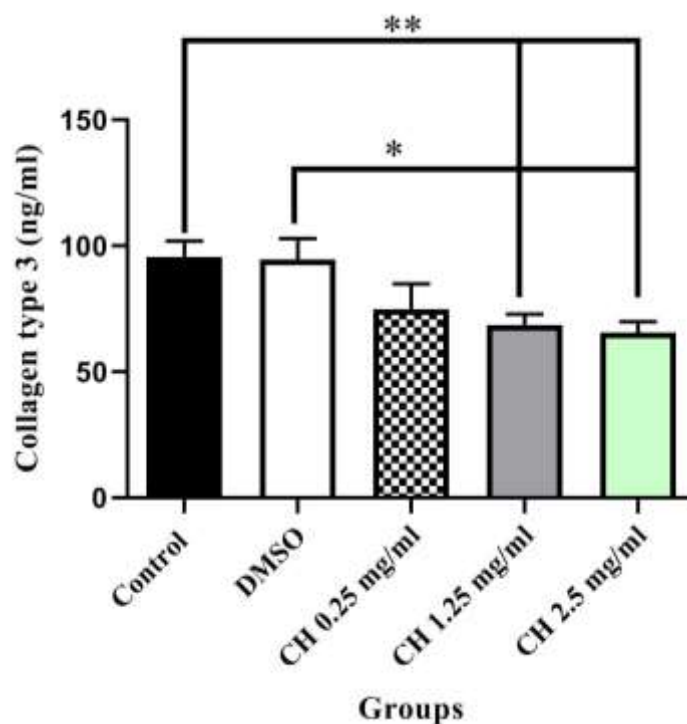


Fig. 5. The average levels of collagen type III in experimental groups. Data are shown as Mean±SEM, * ($P < 0.05$), ** ($P < 0.01$) indicates statistically significant difference ($n=4$).

Effect of CH on collagen deposition

The results of collagen deposition evaluation using Masson's trichrome staining revealed that CH 1.25 and 2.5 mg/ml, significantly ($P < 0.01$) reduced the amount of collagen deposition comparing to non-treatment and

vehicle control group. No statistically significant differences were observed in the amount of collagen deposition among CH. 0.25 mg/ml, non-treatment, and vehicle control groups (Fig. 6).

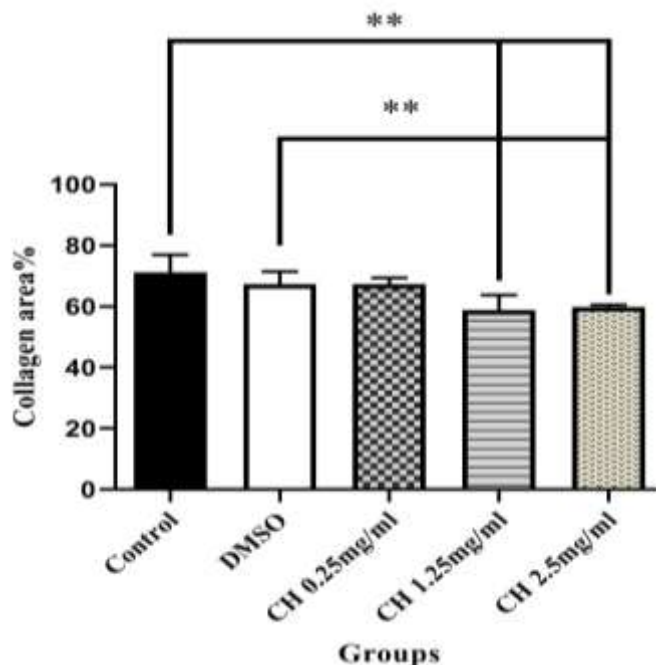


Fig. 6. Collagen deposition quantification. Data are shown as Mean±SEM, ** ($P < 0.01$) indicates statistically significant difference, (n=4).

Effect of CH on MMP1 levels

Evaluation of the effect of intralesional injection of CH on MMP1 levels in scar tissues

revealed that CH had no significant effect on MMP1 levels (Fig. 7).

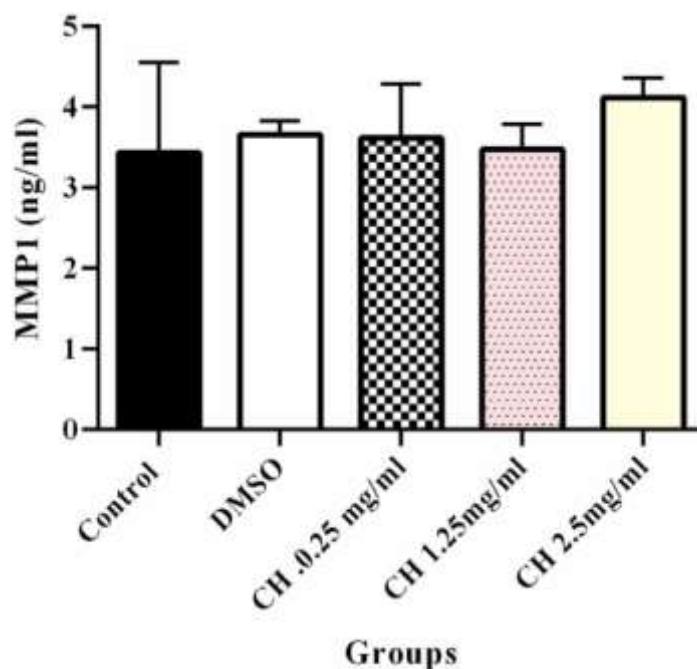


Fig. 7. The average levels of MMP1 in experimental groups. Data are shown as Mean±SEM, (n=3).

Discussion

In this study we examined the therapeutic potential of intralesional injection of CH on hypertrophic scar in rabbit ear model and we found that CH improved the pathological scars.

Our finding revealed that the scar tissue treated with CH had almost normal appearance. Epidermal hypertrophy was evaluated by ETI measurement. The epidermis thickness of scar tissue reduced in CH (1.25 and 2.5 mg/ml) treated groups. The degree of scar formation quantification was performed by measurement of SEI, and our findings indicated that CH injection is capable to reduce the hypertrophic scar formation.

The anti-inflammatory, antioxidant and anti-fibrotic effects of CH were the reasons for choosing CH to be evaluated for its anti-scarring properties. In addition, the safety of catechins have been studied and confirmed in several studies (28-30). This study did not include investigating the mechanism of the anti-scarring effect of CH, however, the results of studies, that have previously examined the anti-fibrotic effects of catechins, suggest the possible mechanisms of catechins in hypertrophic scars, and the results of these studies were consistent with our study. For example, Abe et al. studied the anti-fibrotic effects of green tea (a rich source of catechins) in hepatitis and their findings indicated that green tea suppressed the gene expression of alpha 1 chain of collagen type I and TGF- β 1 that had been increased in injured liver following galactosamine injection (18). Moreover, Wang et al. investigated the anti-fibrogenic potential of three catechins in rat model of liver fibrosis induced by CCL4, and their results revealed that catechins reduced liver fibrosis as demonstrated by suppression of TGF- β , α -smooth muscle actin and desmin expression and by inhibition of phosphorylation of ERK1/2 and Smad1/2 (20). In addition, Song et al. (2023) studied the anti-scarring effect of epigallocatechin gallate (EGCG) in rabbit ear model of hypertrophic scar and they found that EGCG inhibited

fibrotic gene expression and suppressed angiogenesis (22).

One of the most important results of this study was the reduction of collagen production in scar tissue treated with CH, as abnormal extracellular matrix (ECM) remodeling is another feature of hypertrophic scar which is displayed by collagen overproduction. The findings of our study indicated that CH decreased the amount of collagen deposition, and the collagen fibers were thinner and well organized in scar tissue samples obtained from CH treated groups compared with those of non-treatment and DMSO treated groups. The measurement of collagen type I and type III revealed that CH reduced their concentrations in scar tissue. Collagen production is vital for wound healing but overabundance deposition of collagen can lead to abnormal scarring. Thereby, the appropriate production of collagen is needed for normal wound healing.

In this experimental study the effect of CH on MMP1 levels in scar tissue was also evaluated and our findings indicated that CH had no significant effect on MMP1 levels. Matrix metalloproteinases (MMPs) are zinc-containing proteases, which are responsible for ECM degradation (31). MMPs play a crucial role during wound healing process by degradation of collagen, regulation of cell to cell and cell to matrix communication and tissue remodeling. It has been found that MMP1 (collagenase) activity and mRNA are decreased in hypertrophic scars. MMP1 degrades collagen type I and approach of many new therapeutics aim to increase MMPs activity and concentrations, in an effort to decrease excessive deposited collagen (32). The MMP1 expression occurs rapidly in response to loss of ECM during wound healing. Binding of type I collagen to integrin controls the expression of MMP1 (33). The maximum MMP1 expression occurs on 1 day after wounding and its expression gradually decreased until completion of re-epithelialization. MMP1 downregulation appears to be necessary for normal remodeling

of tissue and high levels of MMP1 has been found in chronic non-healing wounds (34). However, the role of MMP1 in wound healing process is complex and it seems that induction of this enzyme after scar formation is difficult and our results indicated that increasing the level of this enzyme is not one of the underlying mechanisms of CH anti-scarring effects.

Sicard *et al.* evaluated the effects of catechins on cell migration mediated by TGF- β 1 and epithelial-mesenchymal transitions (EMT) biomarkers induction and they concluded that diet-derived catechins can circumvent TGF- β 1 mediated signaling that is a contributor of metastatic ovarian cancer (35). TGF- β 1 mediated signaling involved in wound healing by regulation of cell differentiation, collagen synthesis and ECM degradation. It has been accepted that continuous expression of TGF- β 1 contributes in hypertrophic scar formation and TGF- β 1 signaling pathway inhibition is a strategy for prevention of abnormal scarring (36). Therefore, it is possible that the inhibition of this signaling pathway plays a role in the anti-scarring effect of CH. However, further studies are required to confirm this hypothesis.

Catechins possess anti-inflammatory properties (37) and it has been known that

prolong inflammation contributes to hypertrophic scar formation (8), therefore another possible mechanism underlying anti-scarring effect of CH is its anti-inflammatory activity.

In summary, the results of this study revealed that intralesional injection of CH could improve the hypertrophic scar by decreasing collagen synthesis and collagen deposition. The anti-scarring properties of CH could be due to its anti-inflammatory effects, but further studies is needed to elucidate its precise mechanism of action.

Acknowledgements

We would like to express our gratitude to Vice-Chancellor of Research and Technology of Hamadan University of Medical Sciences for their financial support of this study.

Funding

This study was funded by Vice-Chancellor of Research and Technology, Hamadan University of Medical Sciences (grant number: 9912199289).

Conflicts of Interest

The authors declare there is no conflict of interest.

References

1. Coughlin MJ, Dockery GD, Craford ME, Hansen ST. Chapter 28 - Scars. In: Dockery Lower Extremity Soft Tissue & Cutaneous Plastic Surgery (Second Edition). Oxford: Saunders LTD; 2012:389-410.
2. Berman B, Maderal A, Raphael B. Keloids and Hypertrophic Scars: Pathophysiology, Classification, and Treatment. *Dermatol Surg.* 2017;43 Suppl 1:S3-S18.
3. Ogawa R. Keloid and Hypertrophic Scars Are the Result of Chronic Inflammation in the Reticular Dermis. *Int J Mol Sci.* 2017;18(3):606.
4. Grieb G, Steffens G, Pallua N, Bernhagen J, Bucala R. Circulating fibrocytes--biology and

- mechanisms in wound healing and scar formation. *Int Rev Cell Mol Biol.* 2011;291:1-19.
5. Zhang K, Garner W, Cohen L, Rodriguez J, Phan S. Increased types I and III collagen and transforming growth factor-beta 1 mRNA and protein in hypertrophic burn scar. *J Invest Dermatol.* 1995;104(5):750-4.
6. Kim HY, Im HY, Chang HK, Jeong HD, Park JH, Kim HI, *et al.* Correlation between Collagen Type I/III Ratio and Scar Formation in Patients Undergoing Immediate Reconstruction with the Round Block Technique after Breast-Conserving Surgery. *Biomedicine.* 2023;11(4):1089.
7. Tripathi S, Soni K, Agrawal P, Gour V, Mondal R, Soni V. Hypertrophic scars and

- keloids: a review and current treatment modalities. *Biomed Dermatol.* 2020;4(1):1-11.
8. Wang ZC, Zhao WY, Cao Y, Liu YQ, Sun Q, Shi P, et al. The Roles of Inflammation in Keloid and Hypertrophic Scars. *Front Immunol.* 2020;11:603187.
9. Mak K, Manji A, Gallant-Behm C, Wiebe C, Hart DA, Larjava H, Häkkinen L. Scarless healing of oral mucosa is characterized by faster resolution of inflammation and control of myofibroblast action compared to skin wounds in the red Duroc pig model. *J Dermatol Sci.* 2009;56(3):168-80.
10. Rodrigues M, Kosaric N, Bonham CA, Gurtner GC. Wound Healing: A Cellular Perspective. *Physiol Rev.* 2019 ;99(1):665-706.
11. Huang C, Akaishi S, Hyakusoku H, Ogawa R. Are keloid and hypertrophic scar different forms of the same disorder? A fibroproliferative skin disorder hypothesis based on keloid findings. *Int Wound J.* 2014;11(5):517-22.
12. Traci AW. Inflammation as an orchestrator of cutaneous scar formation: a review of the literature. *Plast Aesthet Res.* 2020;7:54.
13. Qu Z, Chen Y, Du K, Qiao J, Chen L, Chen J, et al. ALA-PDT promotes the death and contractile capacity of hypertrophic scar fibroblasts through inhibiting the TGF- β 1/Smad2/3/4 signaling pathway. *Photodiagnosis Photodyn Ther.* 2024;45:103915.
14. Tosa M, Ogawa R. Photodynamic therapy for keloids and hypertrophic scars: a review. *Scars Burn Heal.* 2020;6:2059513120932059.
15. Reinholz M, Guertler A, Schwaiger H, Poetschke J, Gauglitz GG. Treatment of keloids using 5-fluorouracil in combination with crystalline triamcinolone acetonide suspension: evaluating therapeutic effects by using non-invasive objective measures. *J Eur Acad Dermatol Venereol.* 2020;34(10):2436-2444.
16. Nair A, Gopi S. Chapter 2. Natural products with antiinflammatory activities against autoimmune myocarditis. In: Gopi S, Amalraj A, Kunnumakkara A, Thomas S, editors. *Inflammation and Natural Products: Academic Press; 2021:65-82.*
17. Kim JM, Heo HJ. The roles of catechins in regulation of systemic inflammation. *Food Sci Biotechnol.* 2022;31(8):957-970.
18. Abe K, Suzuki T, Ijiri M, Koyama Y, Isemura M, Kinane N. The anti-fibrotic effect of green tea with a high catechin content in the galactosamine-injured rat liver. *Biomed Res.* 2007;28(1):43-8.
19. Desdiani D, Rengganis I, Djauzi S, Setiyono A, Sadikin M, Jusman SWA. Fibropreventive and Antifibrotic Effects of *Uncaria gambir* on Rats with Pulmonary Fibrosis. *Evid Based Complement Alternat Med.* 2022;2022:6721958.
20. Wang L, Yang G, Yuan L, Yang Y, Zhao H, Ho CT, Li S. Green Tea Catechins Effectively Altered Hepatic Fibrogenesis in Rats by Inhibiting ERK and Smad1/2 Phosphorylation. *J Agric Food Chem.* 2019;67(19):5437-5445.
21. Zarei H, Tamri P, Asl SS, Soleimani M, Moradkhani S. Hydroalcoholic Extract of *Scrophularia Striata* Attenuates Hypertrophic Scar, Suppresses Collagen Synthesis, and Stimulates MMP2 and 9 Gene Expression in Rabbit Ear Model. *J Pharmacopuncture.* 2022;25(3):258-267.
22. Song Y, Wang T, Yang L, Wu J, Chen L, Fan X, et al. EGCG inhibits hypertrophic scar formation in a rabbit ear model. *J Cosmet Dermatol.* 2023;22(4):1382-1391.
23. Song Y, Yu Z, Song B, Guo S, Lei L, Ma X, Su Y. Usnic acid inhibits hypertrophic scarring in a rabbit ear model by suppressing scar tissue angiogenesis. *Biomed Pharmacother.* 2018;108:524-30.
24. Zare R, Abdolsamadi H, Soleimani Asl S, Radi S, Bahrami H, Jamshidi S. The bFGF Can Improve Angiogenesis in Oral Mucosa and Accelerate Wound Healing. *Rep Biochem Mol Biol.* 2023;11(4):547-552.

25. Oltulu P, Ince B, Kokbudak N, Findik S, Kilinc F. Measurement of Epidermis, Dermis, and Total Skin Thicknesses from Six Different Body Regions with a New Ethical Histometric Technique. *Turk J Plast Surg.* 2018;26(2):56-61.
26. Shi HX, Lin C, Lin BB, Wang ZG, Zhang HY, Wu FZ, et al. The anti-scar effects of basic fibroblast growth factor on the wound repair in vitro and in vivo. *PLoS One.* 2013;8(4):e59966.
27. Gratz D, Winkle AJ, Dalic A, Unudurthi SD, Hund TJ. Computational tools for automated histological image analysis and quantification in cardiac tissue. *MethodsX.* 2019;7:22-34.
28. Takahashi T, Yokoo Y, Inoue T, Ishii A. Toxicological studies on procyanidin B-2 for external application as a hair growing agent. *Food Chem Toxicol.* 1999;37(5):545-52.
29. Moulton MC, Braydich-Stolle LK, Nadagouda MN, Kunzelman S, Hussain SM, Varma RS. Synthesis, characterization and biocompatibility of "green" synthesized silver nanoparticles using tea polyphenols. *Nanoscale.* 2010;2:763-70.
30. Hu J, Webster D, Cao J, Shao A. The safety of green tea and green tea extract consumption in adults - Results of a systematic review. *Regul Toxicol Pharmacol.* 2018;95:412-433.
31. Razavi P, Rezaee SA, Akhondian S, Asgari N, Fatemi K, Mohajertehran* F. Matrix Metalloproteinase-3 but Not Matrix Metalloproteinase-9, Implicated in the Manifestation of Chronic Periodontitis. *rbmb.* 2023;11(4):656-62.
32. Lee DE, Trowbridge RM, Ayoub NT, Agrawal DK. High-mobility Group Box Protein-1, Matrix Metalloproteinases, and Vitamin D in Keloids and Hypertrophic Scars. *Plast Reconstr Surg Glob Open.* 2015;3(6):e425.
33. Pilcher BK, Dumin JA, Sudbeck BD, Krane SM, Welgus HG, Parks WC. The activity of collagenase-1 is required for keratinocyte migration on a type I collagen matrix. *J Cell Biol.* 1997;137(6):1445-57.
34. Danielsen PL, Holst AV, Maltesen HR, Bassi MR, Holst PJ, Heinemeier KM, et al. Matrix metalloproteinase-8 overexpression prevents proper tissue repair. *Surgery.* 2011;150(5):897-906.
35. Sicard A-A, Dao T, Suarez NG, Annabi B. Diet-Derived Gallated Catechins Prevent TGF- β -Mediated Epithelial-Mesenchymal Transition, Cell Migration and Vasculogenic Mimicry in Chemosensitive ES-2 Ovarian Cancer Cells. *Nutr Cancer.* 2021;73(1):169-80.
36. Nong X, Rajbanshi G, Chen L, Li J, Li Z, Liu T, et al. Effect of artesunate and relation with TGF- β 1 and SMAD3 signaling on experimental hypertrophic scar model in rabbit ear. *Arch Dermatol Res.* 2019;311(10):761-72.
37. Fan FY, Sang LX, Jiang M. Catechins and Their Therapeutic Benefits to Inflammatory Bowel Disease. *Molecules.* 2017;22(3).
38. Wang Z-C, Zhao W-Y, Cao Y, Liu Y-Q, Sun Q, Shi P, et al. The Roles of Inflammation in Keloid and Hypertrophic Scars. *Front Immunol.* 2020;11.