

Protocatechuic Acid Protects Mice Against Non-Alcoholic Fatty Liver Disease by Attenuating Oxidative Stress and Improving Lipid Profile

Zeinab Zeinalian Boroujeni^{1,2}, Layasadat Khorsandi³, Leila Zeidooni^{2,4},
Mahdiah Sadat Badiie^{2,4}, Mohammad Javad Khodayar^{*2,5}

Abstract

Background: Non-alcoholic fatty liver disease (NAFLD) is a general term encompassing many conditions from simple fatty liver to cirrhosis and hepatocellular carcinoma. In this research, we aimed to investigate the effect of the antioxidant protocatechuic acid (PCA) in preventing the development of fatty liver induced by high-fat diet (HFD) in male mice.

Methods: Mice (NMRI) were randomly divided into five groups. The groups were as follows: the control received the standard diet, HFD received 20 ml/kg of HFD, HFD containing PCA received HFD containing 200 mg/kg/20 ml of PCA, HFD containing fenofibrate (FENO) received HFD containing 150 mg/kg/20 ml of FENO, and PCA received 200 mg/kg/20 ml of PCA alone for six weeks. Mice were anesthetized after overnight fasting on the 43rd day, and the blood sample was collected from their hearts. The levels of serum, antioxidants and pro-inflammatory factors were measured, and histological studies were performed.

Results: The results showed that HFD containing PCA decreased liver enzymes, cholesterol (Chol), and thiobarbituric acid reactive substances (TBARS) levels and increased high-density lipoprotein (HDL), and total thiol levels in the liver compared to the HFD group alone ($P < 0.001$). The histopathological examinations of the liver tissue confirmed the biochemical results. High-fat diet (HFD) containing PCA showed no significant effect on the levels of triglyceride (TG), low-density lipoprotein (LDL), catalase, and superoxide dismutase (SOD). The histopathological examinations of the liver tissue confirmed the biochemical results.

Conclusion: The findings of this study demonstrated that PCA is reasonably effective in preventing NAFLD in mice.

Keywords: High-fat diet, Mice, Non-alcoholic fatty liver, Oxidative stress, Protocatechuic acid.

Introduction

Fatty liver is an excessive accumulation of fat in the liver tissue, which may cause a variety of hepatic problems, including liver inflammation. The excess fat accumulated in the fatty liver can disrupt the normal function

of the liver tissue and even progress into liver failure or cirrhosis. Although the leading cause of fatty liver disease is unclear, it appears to be closely related to several metabolic diseases, including obesity, high

1: Medicinal Plant Research Center, Ahvaz Jundishapur University of Medical Sciences, Ahvaz, Iran.

2: Department of Toxicology, Faculty of Pharmacy, Ahvaz Jundishapur University of Medical Sciences, Ahvaz, Iran.

3: Cellular and Molecular Research Center, Ahvaz Jundishapur University of Medical Sciences, Ahvaz, Iran.

4: Student Research Committee, Ahvaz Jundishapur University of Medical Sciences, Ahvaz, Iran.

5: Toxicology Research Center, Ahvaz Jundishapur University of Medical Sciences, Ahvaz, Iran.

*Corresponding author: Mohammad Javad Khodayar; Tel: +98 613 3738378; E-mail: khodayar-mj@ajums.ac.ir.

Received: 27 Apr, 2024; Accepted: 10 June, 2024

blood cholesterol and triglycerides, and diabetes. Perhaps the most critical treatment approach for fatty liver is to control these underlying conditions. It is believed that high energy intake leads to disruption of liver metabolism due to the storage of energy in the form of fat in the liver (1). Fatty liver disease is often common in middle-aged people with high blood fat, diabetes and overweight (especially in cases of abdominal obesity). There are two main categories of fatty liver disease: alcoholic fatty liver disease and non-alcoholic fatty liver disease (2). Alcoholic fatty liver disease is caused by long-term alcohol consumption, but it is also related to gender and race. Asians are more prone to alcohol-induced liver damage and fatty liver, and this condition is more common in women than in men (3). The second type of fatty liver disease, which has a high prevalence in the Iranian population, is called non-alcoholic fatty liver disease or NAFLD. It is classified into primary and secondary types based on etiology: the primary type is related to gender, lifestyle, dietary habits, and obstructive sleep apnea. The secondary type may be caused by hepatotoxic drugs, autoimmune diseases, infectious diseases, heart disease, diabetes, chemotherapy agents, and parenteral nutrition (4,5). The modern lifestyle in developing countries in terms of diet and physical activity has led to an increase in the prevalence of fatty liver disease in these countries (6). The prevalence of NAFLD seems closely related to several metabolic diseases, including obesity, type 2 diabetes, dyslipidemia, hypertension, and cardiovascular disease. Obesity is the most important cause of NAFLD, although genetic factors are also involved in the development of this disease. Activation of hepatic stellate cells and mitochondrial dysfunction in NAFLD leads to severe inflammation, cell damage, and fibrosis (7). Reactive oxygen species (ROS) are destructive factors in liver damage. One of the important methods of treating fatty liver is the use of antioxidant substances (8). Antioxidants are compounds that protect cells from oxidative damage. However, early

treatment may provide time for liver regeneration (9,10). An antioxidant with significant potential in this regard is protocatechuic acid (PCA) (11), which is structurally similar to anti-Known oxidants such as gallic acid, caffeic acid, vanillic acid and syringic acid (12). PCA is widely found in common vegetables, fruits, cereals, tea and more than 500 plant species (13,14). The most important anti-inflammatory plants that contain this antioxidant are: *Cinnamomum aromaticum*, *Prunus domestica* L. (plum), *Vitis vinifera* (grape), *Prunus amygdalus* (almond), *Ginkgo biloba* L. (ginkgo), *Hypericum perforatum* L, *Cibotium barometz*, *Euterpe oleracea* (Acai) (15). The most important benefits of PCA include anti-inflammatory, antioxidant, antidiabetic, anticancer, antiviral, antiparasitic, antibacterial effects and helping to treat cirrhosis and neurological disorders (16,17). PCA may play a bidirectional role in regulating many pharmacological activities. For example, it may act as an antioxidant and an oxidant and stimulate apoptosis and cell proliferation (18-20). Considering the antioxidant effects of PCA and its preventive role in reducing the activity of liver enzymes, in this study we investigated the effect of PCA in preventing fatty liver disease caused by high-fat diet in male mice.

Materials and Methods

Chemicals

Protocatechuic acid (CAS: 99-50-3) was purchased from Sigma Aldrich (St Louis, Missouri, USA). Fenofibrate was donated by Aburaihan Pharmaceutical Company, Tehran, Iran. The assay kits of cholesterol (Cho), triglyceride (TG), low-density lipoprotein (LDL), high-density lipoprotein (HDL), very low-density lipoprotein (VLDL), alkaline phosphatase (ALP), alanine aminotransferase (ALT), and aspartate aminotransferase (AST) were purchased from Pars Azmoon Company, Iran. Thiobarbituric acid reactive substances (TBARS), total thiol, superoxide dismutase (SOD), and catalase (CAT) assay kits were

purchased from the ZellBio Company, Germany.

Animals

This study was conducted on 60 NMRI male mice, weighing 18-22 g. Care conditions were the same for all animals. The animals were placed in units with 12 h/12 h light/dark cycle, temperature 25±2 °C, relative humidity, with free access to sufficient food and water. All the ethical principles for the use and care of animals were based on the Ahvaz Jundishapur University of Medical Sciences (AJUMS) Protocols (ethics number: IR. AJUMS. REC. 1396.696), which is in accordance with National Institutes of Health.

Experimental design

This study was conducted for six weeks. The mice were randomly divided into five groups (12 in each). The groups were as follows: The control group received the standard diet, HFD group received 20 ml/kg of HFD for six weeks, HFD containing PCA group received HFD containing 200 mg/kg/20 ml of PCA for

six weeks, HFD containing fenofibrate (FENO) group received HFD containing 150 mg/kg/20 ml of FENO for six weeks, and PCA group received 200 mg/kg/20 ml of PCA alone for six weeks (21-24). On the first day, all mice were weighed and numbered (Table 1). Fatty liver was created using high-fat emulsion (25). The high-fat emulsion was administered by gavage daily at 8 am. The control group similarly received normal saline. At the end of each week, the animals were accurately weighed. Approximately 24 h after the last administration, animals were anesthetized with ketamine (90 mg/kg)/xylazine (10 mg/kg). Blood samples were collected directly from the heart and stored in gel-barrier plastic tubes. After separating the serum, the samples were kept at -20 °C until the tests. The liver tissue was extracted and washed with normal saline, then divided into two parts. One part was placed in 10% formalin solution for histopathological examination, and another part was placed at -70 °C to assay oxidative, inflammatory, and fibrotic factors.

Table 1. The composition of the high-fat emulsion diet and caloric content with a total energy of 4342 kcal/l (25).

Component	Content
Corn oil (g)	400
Saccharose (g)	150
Total milk powder	80
Cholesterol (g)	100
Sodium deoxycholate (g)	10
Tween 80 (g)	36.4
Propylene glycol (g)	31.1
Vitamin mixture (g)	2.5
Cooking salt (g)	10
Mineral mixture (g)	1.5
Distilled water (ml)	300

Mice were weighed at the end of each week. Liver weight was measured at the end of week six. The percentage ratio of liver weight (grams) to body weight (grams) was reported as liver index.

Histopathological study of the liver

A part of the liver tissue was fixed in 10% formalin. After processing and preparing the tissue block, thin sections with a thickness of 5 microns were obtained from these blocks and stained with hematoxylin-eosin method (26). The slides were examined by light microscope for histological changes such as red blood cell accumulation, inflammatory cell infiltration and fat deposition in liver cells. The histological features were graded into four categories: normal (0), weak (1), moderate (2) or, severe (3) and the averages were considered. For each slide, the average of six fields was calculated, and the slides were read in a “blind” fashion (27).

Preparation of liver tissue homogenate

For this purpose, a piece of liver tissue was homogenized in a 0.1 M phosphate buffer with a pH=7.4 and a concentration of 10% v/w, using a homogenizer and centrifuged at a speed of 12,000×g at 4 °C for 20 minutes. The supernatant was separated and placed in separate microtubes and stored in a freezer at –70 °C until TBARS, total thiol, superoxide dismutase and catalase tests were performed.

Biochemical analysis of the serum and tissue homogenates

The levels of triglyceride, cholesterol, LDL, HDL, VLDL, ALT, AST, and ALP in the serum samples were measured with Pars Azmoon assay kits by Hitachi 912 auto-analyzer (Japan).

Determination of total thiol (TT)

The total thiol level of the liver tissue measurement is based on Ellman's reagent (DTNB), and the formation of yellow TNB. For this purpose, 40 µl of the homogeneous tissue was mixed with 2 ml of phosphate buffer and then with 40 µl of 10 mM Ellman's

reagent, and the yellow color was read at 412 nm with a spectrophotometer and expressed as nmol/mg protein. The calibration curve was plotted for concentrations of 5, 10, 20 and 40 mg/L (µg/ml).

Determination of thiobarbituric acid reactive substances (TBARS)

The number of substances reactive with thiobarbituric acid (TBA) was measured to indicate lipid peroxidation. In this study, the level of TBARS was measured using the Kei method (28). For this purpose, 0.5 ml of the homogeneous tissue was mixed with 0.5 ml of 10% trichloroacetic acid, and the resulting solution was centrifuged for 10 min at 4000×g. After separating the supernatant, 0.5 ml was mixed with 0.5 ml of 0.67% thiobarbituric acid solution and then incubated in a hot water bath for 30 min. The pink color absorbance was measured with a microplate reader at 532 nm, and the amount of TBARS was reported as nmol/mg protein.

Determination of catalase (CAT) activity

The activity of catalase (CAT) was determined by the Shangari method (29). For this purpose, 100 µl of liver tissue extract (in 50 mM phosphate buffer with pH=7) was placed in the cuvette and the reaction was started by adding freshly prepared 30 mM H₂O₂. The remaining H₂O₂ in the sample reacts with ammonium molybdate. The absorbance in 60 second was read with a microplate reader at 410 nm as IU/mg protein (30).

Determination of superoxide dismutase (SOD) activity

The activity of superoxide dismutase (SOD) was measured colorimetrically using an enzymatic assay ZellBio (Germany) kit and was recorded as IU/mg protein.

Statistical analysis

For statistical analysis, the normality of the data was tested using the Kolmogorov Smirnov test. The mean ± SEM of the data about each group was calculated. Comparison of the means was performed by analysis of

variance (ANOVA) and determine the difference between the means and the significance of the ANOVA analysis, Tukey's post hoc supplementary test in GraphPad Prism version 8 statistical software. For all the tests, significance was defined at $P < 0.05$.

Results

Effect of diets on body weight

The weight gain in the HFD group was significantly higher than the control group ($P < 0.001$) in the fifth and sixth weeks. While the HFD groups receiving PCA or FENO had no significant weight gain compared to the HFD group. The weight gain in the HFD+PCA group was more than the HFD+FENO group, which indicates the better effect of FENO compared to PCA in improving fatty liver (Fig. 1).

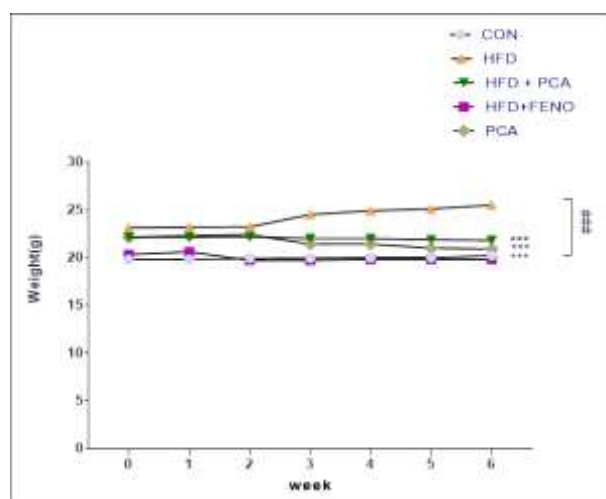


Fig. 1. Mean weight gain in the Control (CON) group and the treatment groups. For six weeks, mice received the HFD alone, HFD with PCA, or HFD with fenofibrate (FENO), and were weighed at the end of each week.

Data are expressed as mean \pm SEM ($n=5-15$).

(*** $P < 0.001$) Comparison with the control group.

(### $P < 0.001$) Comparison of the HFD groups receiving PCA or FENO with the HFD group.

Effect of PCA on liver function enzymes

Elevated serum levels of functional liver enzymes, including ALT, AST, and ALP, could be a symptom of liver damage. HFD consumption increased the activities of ALT, AST, and ALP compared to the control group ($P < 0.001$) (Fig. 2). However, HFD supplemented with FENO or PCA significantly

decreased the activities of these enzymes compared to HFD alone ($P < 0.001$). Receiving PCA alone showed a slight increase in serum ALT and ALP levels compared to the control group. HFD with FENO compared to HFD with PCA, resulted in a significant decrease in liver enzymes, which indicates the better effect of FENO compared to PCA in improving fatty liver ($P < 0.001$).

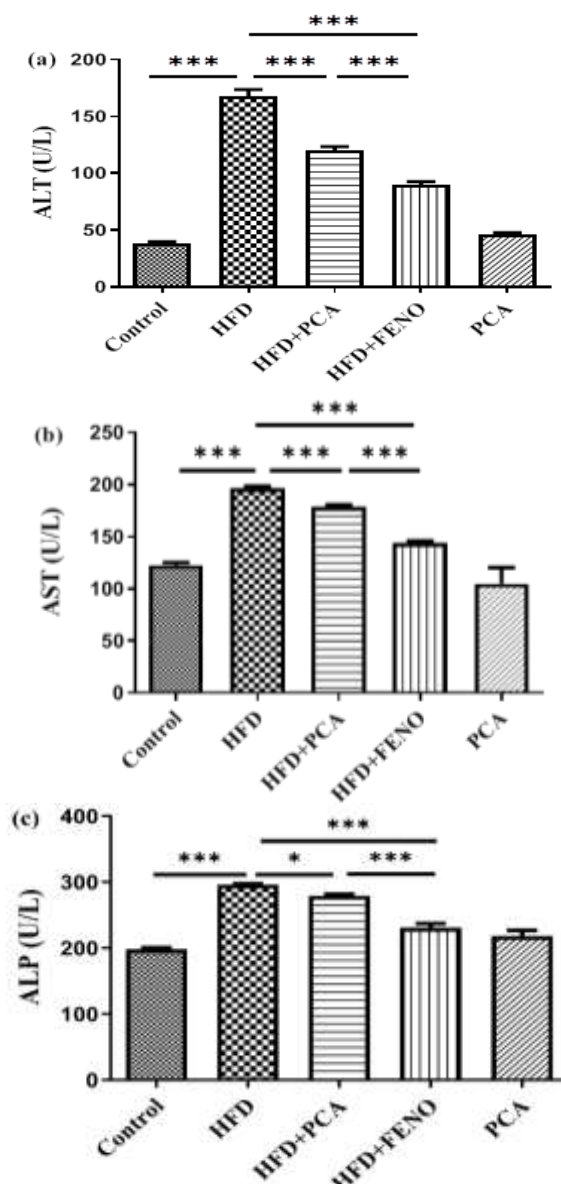


Fig. 2. The effects of PCA (protocatechuic acid) on serum activity level of (a) ALT; (b) AST; and (c) ALP in HFD (high-fat diet)-induced fatty liver in mice. For six weeks, mice received the HFD alone, HFD with PCA, or HFD with fenofibrate (FENO).

Data are expressed as mean \pm SEM ($n=5-15$). (* $P < 0.05$, and *** $P < 0.001$).

AST: Aspartate aminotransferase, ALT: Alanine aminotransferase, ALP: Alkaline phosphatase.

Effect of PCA on lipid profile

Lipid profiles in the HFD group increased significantly compared to the control group ($P < 0.001$), which indicates the success in creating fatty liver in mice. In the HFD with PCA group, a significant decrease in the serum level of Chol ($P < 0.001$) and an increase in the serum level of HDL ($P < 0.001$), which indicated improvement of fatty liver in mice (Fig. 3). In contrast, receiving FENO with HFD led to a significant decrease ($P < 0.001$) in Chol, TG, and LDL compared to the HFD group. Eventually, in HFD with FENO group compared to HFD with PCA group, a further reduction in Chol, TG, and LDL, and a further increase in HDL was observed, which shows the better effect of FENO compared to PCA in improving fatty liver in mice.

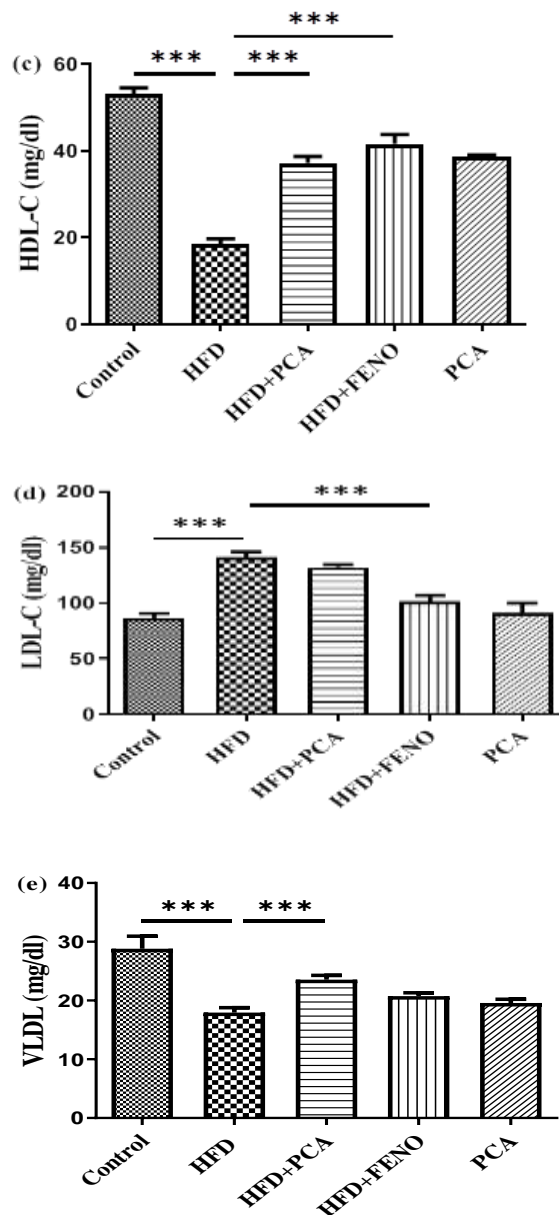
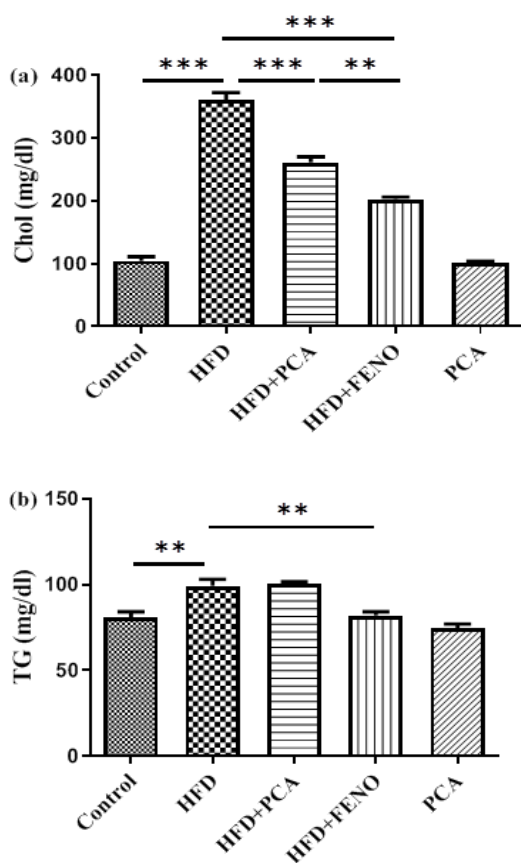


Fig. 3. The effects of PCA (protocatechuic acid) on serum levels of (a) Cholesterol; (b) Triglyceride; (c) HDL; (d) LDL; and (e) VLDL in HFD (high-fat diet)-induced fatty liver in mice. For six weeks, mice received the HFD alone, HFD with PCA, or HFD with fenofibrate (FENO). Data are expressed as mean \pm SEM (n=5-15). (** $P < 0.01$ and *** $P < 0.001$). Chol: cholesterol, TG: triglyceride, HDL-C: high-density lipoprotein-cholesterol, LDL-C: low-density lipoprotein-cholesterol, VLDL: very low-density lipoprotein.

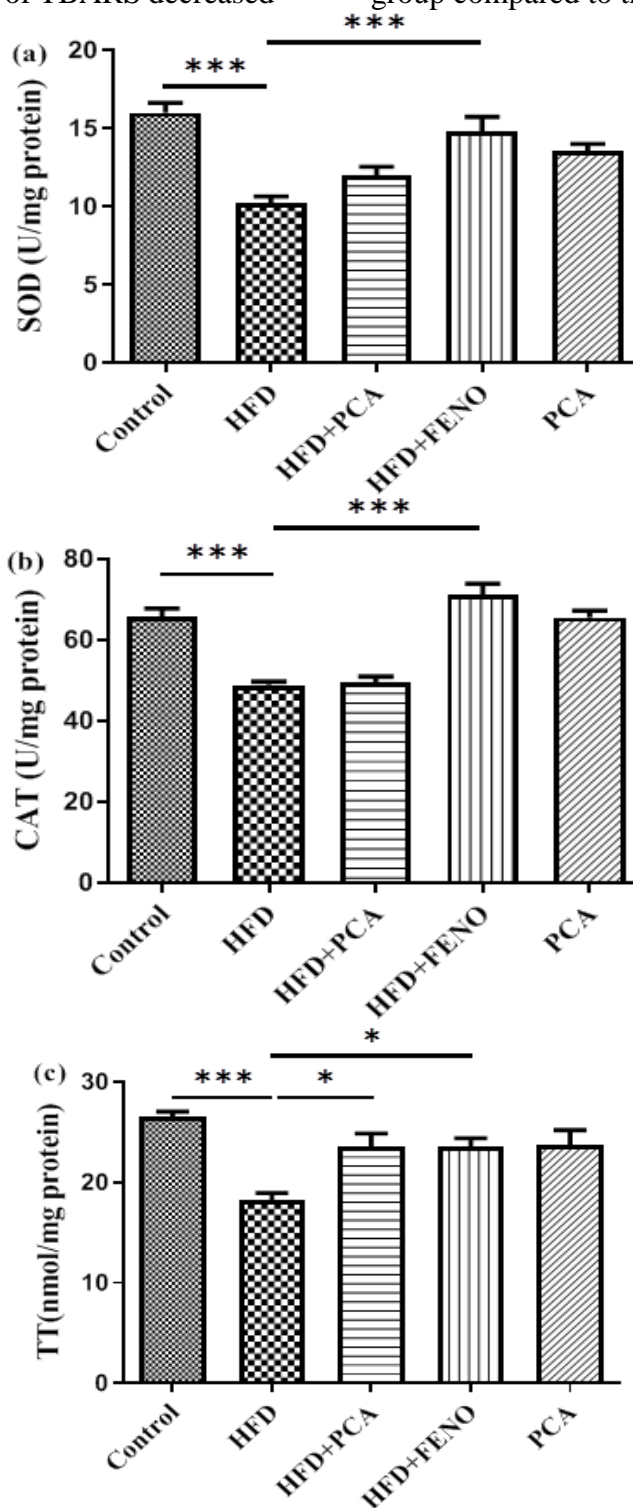
Effect of PCA on oxidative stress parameters

The levels of SOD, and CAT in the HFD group were significantly lower than the control group ($P < 0.001$) (Fig. 4). However, in the group

receiving FENO with HFD, compared to the HFD group, the levels of SOD and CAT were significantly higher ($P < 0.001$). Finally, in the HFD with FENO group compared to the HFD

with PCA group, a greater increase in SOD and CAT was observed, which indicates a better effect of FENO than PCA in improving fatty liver in mice. HFD led to an increase in TBARS levels compared to the control group ($P < 0.001$). However, in the groups that received HFD with PCA or FENO supplements, the amount of TBARS decreased

significantly ($P < 0.001$). Total thiol was significantly lower in the HFD group than the control group ($P < 0.001$). However, receiving PCA or FENO with HFD resulted in a significant increase in total thiol levels ($P < 0.05$). Oxidative stress parameters were not significantly different in the HFD with FENO group compared to the HFD with PCA group.



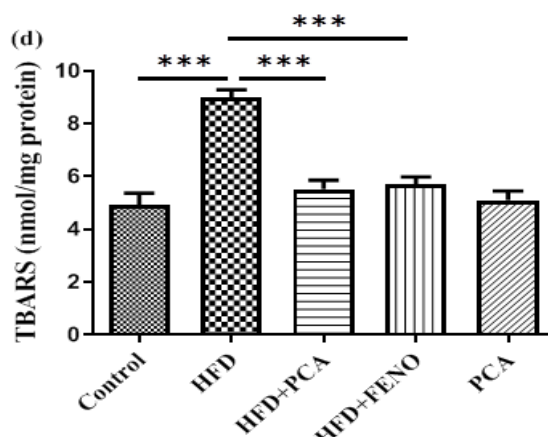


Fig. 4. The effects of PCA (protocatechuic acid) on the levels of (a) SOD; (b) CAT; (c) TT and (d) TBARS in HFD (high-fat diet)-induced fatty liver in mice. For six weeks, mice received the HFD alone, HFD with PCA, or HFD with fenofibrate (FENO). Data are expressed as mean \pm SEM (n=5-15). (*P<0.05, and *** P<0.001). SOD: superoxide dismutase, CAT: catalase, TT: total thiol, TBARS: thiobarbituric acid reactive substances.

Effect of PCA on histopathological examination

A distinct difference can be seen between the liver of the HFD-fed subject and the liver with the standard diet (Fig. 5). This macroscopic finding is consistent with microscopic results. Microscopic examination of liver tissue with hematoxylin-eosin staining in the treatment groups and the control group showed that the liver of the control group mice had a normal structure with normal cytoplasm and cores without any signs of damage (Fig. 6). While mice fed with HFD for six weeks showed significant histopathological changes in the liver in the form of microvesicular and macrovesicular lipid accumulation and hepatocellular swelling. The semi-quantitative analysis of liver tissue damage in the treated

groups and the control group showed, in the control group, it revealed no abnormality in the liver tissue (Table 2). In the mice that received the HFD alone, hepatocytes underwent a transparent change, and most of the cell were saturated with adipose tissue. These samples also showed the accumulation of red blood cells, and inflammatory cells infiltration in the liver tissue. In the mice that received the HFD with PCA or FENO, the liver tissue was significantly less damaged than those that received the HFD alone. These samples also showed lower fat deposition, accumulation of red blood cells and inflammatory cells infiltration than the HFD group, which shows the improvement of fatty liver in PCA and FENO groups.

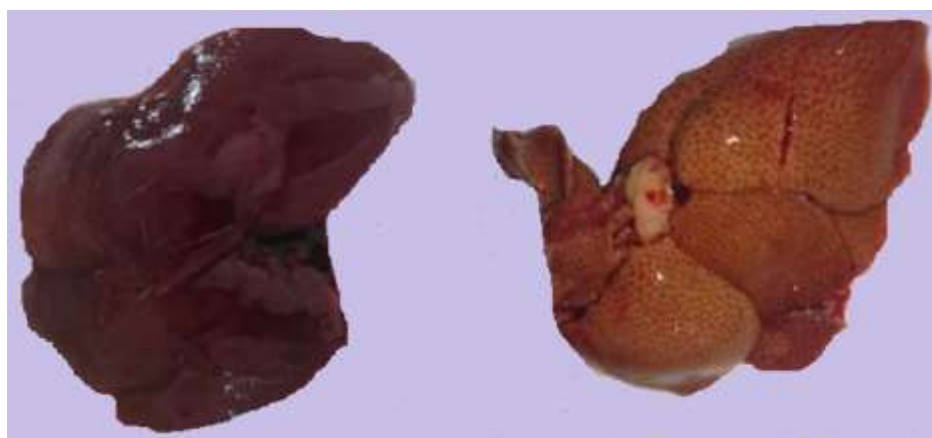


Fig. 5. Macroscopic image shows the normal liver (left) and fatty liver caused by high fat diet (right) in mice.

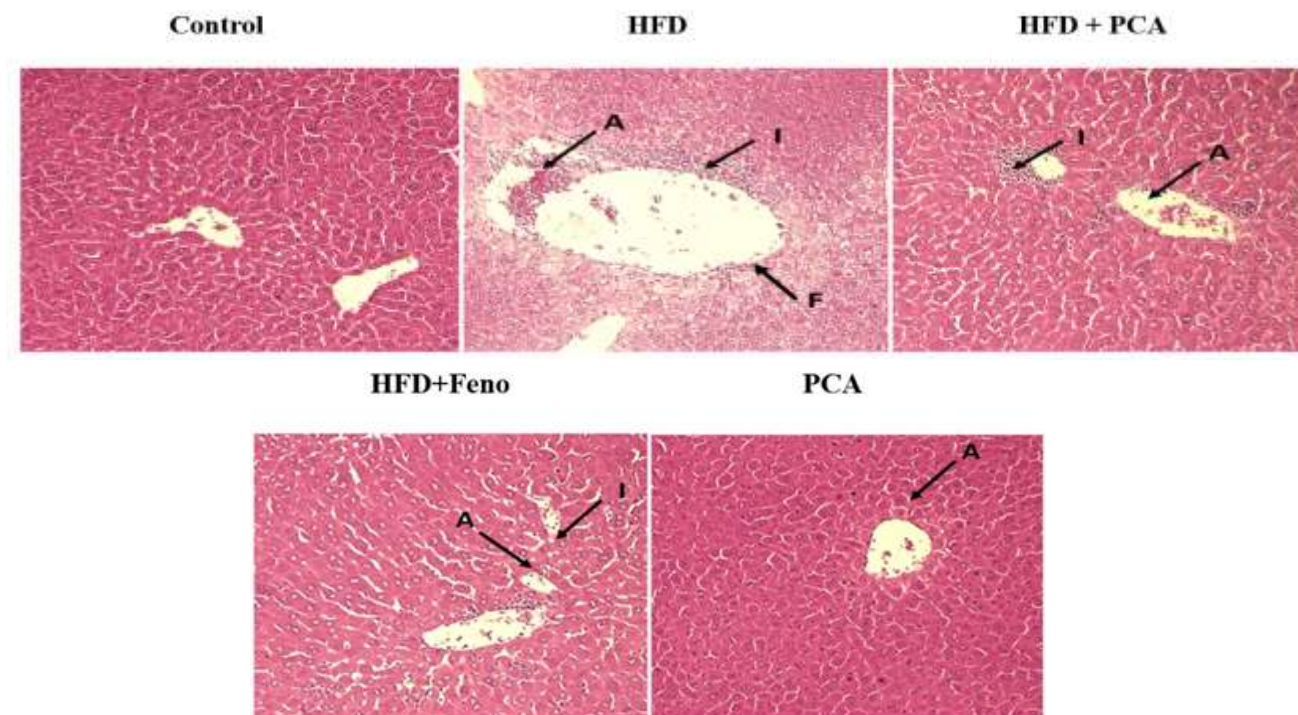


Fig. 6. Hematoxylin-eosin staining of the liver tissue in the treated groups in HFD (high-fat diet)-induced fatty liver in mice. (magnification: 100x). For six weeks, mice received the high-fat diet (HFD) alone, HFD with protocatechuic acid (PCA), or HFD with fenofibrate (FENO). I: Inflammation, A: RBC accumulation, F: Fat deposition.

Table 2. A semi-quantitative analysis of liver tissue damage in the treatment groups and the control group.

Data are expressed as mean \pm SEM (n=5-15).

(**P<0.01) and (***)P<0.001) Comparison with the control group. (#P<0.05) and (##P<0.01) Comparison of the HFD groups receiving protocatechuic acid (PCA) or fenofibrate (FENO) with the high-fat diet (HFD) group (P<0.001).

Groups	RBCs accumulation	Inflammation	Fat deposit
Control	0.02 \pm 0.00	0.03 \pm 0.00	0.00 \pm 0.00
HFD	1.25 \pm 0.04 ^{***}	1.95 \pm 0.02 ^{***}	1.93 \pm 0.23 ^{***}
HFD + PCA	0.44 \pm 0.16 ^{***##}	0.67 \pm 0.15 ^{***#}	0.09 \pm 0.02 ^{***##}
HFD + FENO	0.33 \pm 0.08 ^{***##}	0.43 \pm 0.00 ^{***#}	0.13 \pm 0.03 ^{***##}
PCA	0.01 \pm 0.00	0.02 \pm 0.00	0.00 \pm 0.00

Discussion

The present study showed that HFD containing PCA could prevent NAFLD by decreasing the serum levels of ALT, AST, and ALP, also, decreasing of TBARS level as the endpoint of lipid peroxidation, and increasing of total thiol level as the most antioxidant in hepatocytes. Obesity is associated with NAFLD and other metabolic syndromes. Metabolic syndrome is one of the most issues in the growth of NAFLD. Obesity, hypertriglyceridemia, and

low levels of HDL are components of the metabolic syndrome (25,31). In this study, the HFD caused a significant increase in body weight compared to the control group. Also, serum levels of cholesterol, triglyceride, and LDL significantly increased and serum levels of HDL and VLDL significantly decreased compared to the control group. Many studies similar to our study have shown that rats became obese after being fed with a high-fat

diet and showed symptoms of metabolic syndrome (25,32). Previous studies demonstrated that PCA, significantly decreased lipogenic factors and liver fat accumulation (33). A similar study, showed that doses of 50 and 100 mg/kg PCA, ameliorated liver injury induced by tert-butyl hydroperoxide in rats (34). A previous study reported that administration of PCA (500 mg/kg) significantly decreased GSH levels in mouse liver and caused mild hepatotoxicity by increasing serum ALT activity (35). In another study, the administration of a high dose of PCA (>1 μ mol) in mice increased skin tumor promotion, oxidative stress and inflammation, whereas a lower dose (16 nmol) reduced these reactions (36). In our study, the administration of PCA (200 mg/kg), did not lead to toxicity in mice. The increase in the serum levels of ALP, ALT, and AST in the HFD group demonstrated the effect of this diet on the development of fatty liver and, therefore, the development of NAFLD. Examination of the groups that received the HFD with FENO or PCA showed a significant decrease in the activity of the mentioned enzymes, which indicates the improving effect of both substances on the development of the fatty liver. Similar to our study, administration of high-fat diet increased liver function enzymes in mice (25). After measuring the serum levels of cholesterol, triglyceride, LDL, HDL, and VLDL in the groups, significant differences were observed in terms of these factors between the HFD group and the control group. In the group receiving the HFD with FENO, all lipid profiles significantly decreased, but in the group of HFD with PCA, observed a significant decrease in the serum levels of cholesterol, and an increase in the serum levels of HDL, which indicated the improvement of the fatty liver in mice. The present study confirms that HFD can cause oxidative damage to the liver. Our findings showed that TBARS concentration increased and total thiol, SOD, and CAT levels decreased after HFD administration for six weeks, and showed that the imbalance between oxidant and antioxidant in liver tissue leads to oxidative

damage. A previous study demonstrated that oxidative stress and following lipid peroxidation play a vital role in the pathogenesis of NAFLD. As an endpoint of lipid peroxidation, TBARS plays a vital role in all the typical histological features observed in NAFLD (25,34). The biochemical and histopathological findings of this study suggested that treatment with PCA reduced liver steatosis and prevented peroxidation, and these effects were comparable to the effect of FENO. Although in the group that received PCA alone, red blood cell aggregation was observed. Histopathological and microscopic examinations and macroscopic images of the liver tissue clearly showed that administration of PCA with HFD, had the desired effect on the liver tissue, and the added antioxidant and medicine standard improved the condition of the fatty liver. This suggests that PCA can prevent hepatic steatosis by reducing the accumulation of fat in the serum and the liver. The liver plays a significant role in the body's fat metabolism, and liver steatosis signifies excessive fat accumulation in hepatocytes because of an imbalance between fat formation and fat degradation. The therapeutic effects of PCA on the fatty liver have been shown in previous studies (37). Previous studies have shown that PCA prevents the activation of NF- κ B caused by TNF- α and has an anti-inflammatory effect by reducing the levels of TNF- α and IL-6 and ultimately leads to the improvement of hepatic steatosis (38). The study of PCA ameliorates high fat diet-induced obesity and insulin resistance in Mice, is similar to our study, with the difference that male mice were fed with HFD for 4 weeks and were randomly divided into two groups, and the performance hepatic and peripheral insulin were evaluated (39).

Biochemical and histopathological evidence of this study have shown that PCA can prevent fat accumulation in the liver and provide protective effects by regulating the serum levels of cholesterol, HDL, and VLDL. These changes were accompanied by a reduction in oxidative stress and activity of liver function markers, which can lead to the

prevention of development of fatty liver. Biochemical and histopathological studies showed that although the PCA was not as effective as FENO, it had a significant effect in improving and preventing the development of fatty liver disease in mice.

Funding

This research was funded by the Toxicology Research Center, Medical Basic Sciences Research Institute of AJUMS, grant number: TRC-9704. We would like to express our sincere gratitude to the Deputy Director of Research of AJUMS for supporting this research.

References

1. Paschos P, Paletas K. Non alcoholic fatty liver disease and metabolic syndrome. *Hippokratia*. 2009;13(1):9-19.
2. Williams CD, Stengel J, Asike MI, Torres DM, Shaw J, Contreras M, Landt CL, Harrison SA. Prevalence of nonalcoholic fatty liver disease and nonalcoholic steatohepatitis among a largely middle-aged population utilizing ultrasound and liver biopsy: a prospective study. *Gastroenterology*. 2011;140(1):124-31.
3. Puri P, Sanyal AJ. Nonalcoholic fatty liver disease: Definitions, risk factors, and workup. *Clin Liver Dis (Hoboken)*. 2012;1(4):99-103.
4. Papadopoulos C, Mimidis K, Papazoglou D, Kolios G, Tentis I, Anagnostopoulos K. Red Blood Cell-Conditioned Media from Non-Alcoholic Fatty Liver Disease Patients Contain Increased MCP1 and Induce TNF- α Release. *Rep Biochem Mol Biol*. 2022;11(1):54-62.
5. Alshawsh MA, Alsalahi A, Alshehade SA, Saghier SAM, Ahmeda AF, Al Zarzour RH, Mahmoud AM. A Comparison of the Gene Expression Profiles of Non-Alcoholic Fatty Liver Disease between Animal Models of a High-Fat Diet and Methionine-Choline-Deficient Diet. *Molecules*. 2022;27(3):858.
6. Abdelgwad M, Zakaria R, Marzouk S, Sabry D, Ahmed R, Badary HA, Samir M. The Emerging Role of Circular RNA Homeodomain Interacting Protein Kinase 3 and Circular RNA 0046367 through Wnt/Beta-Catenin Pathway on

Acknowledgments

All the ethical principles for the use and care of animals were based on the Ahvaz Jundishapur University of Medical Sciences (AJUMS) Protocols (ethics number: IR. AJUMS. REC. 1396.696), which is in accordance with National Institutes of Health.

Conflicts of interest

The authors have declared that there is no conflict of interest.

the Pathogenesis of Nonalcoholic Steatohepatitis in Egyptian Patients. *Rep Biochem Mol Biol*. 2023;11(4):614-625.

7. de Castro GS, Calder PC. Non-alcoholic fatty liver disease and its treatment with n-3 polyunsaturated fatty acids. *Clin Nutr*. 2018;37(1):37-55.

8. Trush MA, Kensler TW. An overview of the relationship between oxidative stress and chemical carcinogenesis. *Free Radic Biol Med*. 1991;10(3-4):201-9.

9. Nazarinia D, Sharifi M, Dolatshahi M, Nasseri Maleki S, Madani Neishaboori A, Aboutaleb N. FoxO1 and Wnt/ β -catenin signaling pathway: Molecular targets of human amniotic mesenchymal stem cells-derived conditioned medium (hAMSC-CM) in protection against cerebral ischemia/reperfusion injury. *J Chem Neuroanat*. 2021;112:101918.

10. D'Oria R, Schipani R, Leonardini A, Natalicchio A, Perrini S, Cignarelli A, et al. The Role of Oxidative Stress in Cardiac Disease: From Physiological Response to Injury Factor. *Oxid Med Cell Longev*. 2020 ;2020:5732956.

11. Rice-Evans CA, Miller NJ, Paganga G. Structure-antioxidant activity relationships of flavonoids and phenolic acids. *Free Radic Biol Med*. 1996;20(7):933-56.

12. Huang C, Ma T, Meng X, Lv X, Zhang L, Wang J, Li J. Potential protective effects of a traditional Chinese herb, *Litsea coreana* Levl., on liver fibrosis in rats. *J Pharm Pharmacol*. 2010;62(2):223-30.

13. Ryu JY, Kang HR, Cho SK. Changes Over the Fermentation Period in Phenolic Compounds and Antioxidant and Anticancer Activities of Blueberries Fermented by *Lactobacillus plantarum*. *J Food Sci*. 2019;84(8):2347-2356.
14. Lee SH, Choi BY, Kho AR, Jeong JH, Hong DK, Lee SH, et al. Protective Effects of Protocatechuic Acid on Seizure-Induced Neuronal Death. *Int J Mol Sci*. 2018;19(1):187.
15. Kakkar S, Bais S. A review on protocatechuic Acid and its pharmacological potential. *ISRN Pharmacol*. 2014;2014:952943.
16. Takeda Y, Okuyama Y, Nakano H, Yaoita Y, Machida K, Ogawa H, Imai K. Antiviral Activities of *Hibiscus sabdariffa* L. Tea Extract Against Human Influenza A Virus Rely Largely on Acidic pH but Partially on a Low-pH-Independent Mechanism. *Food Environ Virol*. 2020;12(1):9-19.
17. Habib SA, Suddek GM, Abdel Rahim M, Abdelrahman RS. The protective effect of protocatechuic acid on hepatotoxicity induced by cisplatin in mice. *Life Sci*. 2021;277:119485.
18. Gao Y, Tian R, Liu H, Xue H, Zhang R, Han S, et al. Research progress on intervention effect and mechanism of protocatechuic acid on nonalcoholic fatty liver disease. *Crit Rev Food Sci Nutr*. 2022;62(32):9053-9075.
19. Ji L, Deng H, Xue H, Wang J, Hong K, Gao Y, et al. Research progress regarding the effect and mechanism of dietary phenolic acids for improving nonalcoholic fatty liver disease via gut microbiota. *Compr Rev Food Sci Food Saf*. 2023;22(2):1128-1147.
20. Xiang Y, Huang R, Wang Y, Han S, Qin X, Li Z, et al. Protocatechuic Acid Ameliorates High Fat Diet-Induced Obesity and Insulin Resistance in Mice. *Mol Nutr Food Res*. 2023;67(3):e2200244.
21. Chang CJ, Tzeng TF, Liou SS, Chang YS, Liu IM. Kaempferol regulates the lipid-profile in high-fat diet-fed rats through an increase in hepatic PPAR α levels. *Planta Med*. 2011;77(17):1876-82.
22. Lin CY, Huang CS, Huang CY, Yin MC. Anticoagulatory, antiinflammatory, and antioxidative effects of protocatechuic acid in diabetic mice. *J Agric Food Chem*. 2009;57(15):6661-7.
23. Tsai SJ, Yin MC. Anti-glycative and anti-inflammatory effects of protocatechuic acid in brain of mice treated by D-galactose. *Food Chem Toxicol*. 2012;50(9):3198-205.
24. van der Veen JN, Lingrell S, Gao X, Takawale A, Kassiri Z, Vance DE, Jacobs RL. Fenofibrate, but not ezetimibe, prevents fatty liver disease in mice lacking phosphatidylethanolamine *N*-methyltransferase. *J Lipid Res*. 2017;58(4):656-667.
25. Zou Y, Li J, Lu C, Wang J, Ge J, Huang Y, et al. High-fat emulsion-induced rat model of nonalcoholic steatohepatitis. *Life Sci*. 2006;79(11):1100-7.
26. Luna, LG, Manual of histologic staining methods of the Armed Forces Institute of Pathology, in Manual of histologic staining methods of the Armed Forces Institute of Pathology. 1968; Blakiston Division, McGraw-Hill, New York.
27. Brunt EM, Janney CG, Di Bisceglie AM, Neuschwander-Tetri BA, Bacon BR. Nonalcoholic steatohepatitis: a proposal for grading and staging the histological lesions. *Am J Gastroenterol*. 1999;94(9):2467-74.
28. Satoh K. Serum lipid peroxide in cerebrovascular disorders determined by a new colorimetric method. *Clin Chim Acta*. 1978;90(1):37-43.
29. Shangari N, O'Brien PJ. Catalase activity assays. *Curr Protoc Toxicol*. 2006;Chapter 7:Unit 7.7.1-15.
30. van der Kamp MW, Mulholland AJ. Combined quantum mechanics/molecular mechanics (QM/MM) methods in computational enzymology. *Biochemistry*. 2013;52(16):2708-28.
31. Kim J, Lee H, Lim J, Lee H, Yoon S, Shin SS, Yoon M. The lemon balm extract ALS-L1023 inhibits obesity and nonalcoholic fatty liver disease in female ovariectomized mice. *Food Chem Toxicol*. 2017;106(Pt A):292-305.
32. Harris RB. Factors influencing energy intake of rats fed either a high-fat or a fat mimetic diet. *Int J Obes Relat Metab Disord*. 1994;18(9):632-40.
33. Liu WH, Lin CC, Wang ZH, Mong MC, Yin MC. Effects of protocatechuic acid on trans fat induced hepatic steatosis in mice. *J Agric Food Chem*. 2010;58(18):10247-52.

34. Liu CL, Wang JM, Chu CY, Cheng MT, Tseng TH. In vivo protective effect of protocatechuic acid on tert-butyl hydroperoxide-induced rat hepatotoxicity. *Food Chem Toxicol.* 2002;40(5):635-41.
35. Nakamura Y, Torikai K, Ohigashi H. Toxic dose of a simple phenolic antioxidant, protocatechuic acid, attenuates the glutathione level in ICR mouse liver and kidney. *J Agric Food Chem.* 2001;49(11):5674-8.
36. Nakamura Y, Torikai K, Ohto Y, Murakami A, Tanaka T, Ohigashi H. A simple phenolic antioxidant protocatechuic acid enhances tumor promotion and oxidative stress in female ICR mouse skin: dose- and timing-dependent enhancement and involvement of bioactivation by tyrosinase. *Carcinogenesis.* 2000;21(10):1899-907.
37. Sun R, Kang X, Zhao Y, Wang Z, Wang R, Fu R, et al. Sirtuin 3-mediated deacetylation of acyl-CoA synthetase family member 3 by protocatechuic acid attenuates non-alcoholic fatty liver disease. *Br J Pharmacol.* 2020;177(18):4166-4180.
38. Wu H, Wang J, Zhao Q, Ding Y, Zhang B, Kong L. Protocatechuic acid inhibits proliferation, migration and inflammatory response in rheumatoid arthritis fibroblast-like synoviocytes. *Artif Cells Nanomed Biotechnol.* 2020;48(1):969-976.
39. Xiang Y, Huang R, Wang Y, Han S, Qin X, Li Z, et al. Protocatechuic Acid Ameliorates High Fat Diet-Induced Obesity and Insulin Resistance in Mice. *Mol Nutr Food Res.* 2023;67(3):e2200244.