

Ischemia-Modified Albumin, Creatinine, And Paraoxonase-1 Levels in Serum of Patients Undergoing Intravenous Contrast-Enhanced Computed Tomography and Its Association with Contrast-Induced Nephropathy

Chanda Jha¹, Shobha Ullas Kamath*¹, Sambit Dash², Ravindra Prabhu Attur³,
Lingadakai Ramachandra⁴, Rajgopal Shenoy Kallya⁴

Abstract

Background: Following contrast-enhanced computed tomography (CECT) contrast-induced nephropathy (CIN) may occur in patients with renal insufficiency or diabetes. Creatinine, the most common marker of CIN, may not be an accurate measure of damage and is affected by many non-renal factors. Our aim was to evaluate ischemia-modified albumin (IMA) as an early CIN marker and correlate it with paraoxonase-1 (PON-1) and creatinine before and after CECT.

Methods: Forty-eight adult patients scheduled for intravenous CECT, regardless of indication or body region for CECT, were included in this prospective study. Venous blood samples were obtained 12-24 hours before and after contrast media (CM) administration. Ischemia-modified albumin and PON-1 were estimated using methods described by Bar-Or et al. and Dantoine et.al., respectively. Creatinine was estimated on an automated analyzer.

Results: Significant differences in IMA ($P < 0.001$) and PON-1 ($P < 0.001$) levels were found between pre- and post-CECT samples, while the difference for creatinine was not significant ($p = 0.073$). No correlation was found between IMA and PON-1 or IMA and creatinine in either the pre- or post-CECT samples.

Conclusions: After CM administration patients are subjected to oxidative stress and/or ischemia, as revealed by elevated IMA and decreased PON-1 levels; however, creatinine levels, most commonly estimated to assess reduced renal function, did not reflect the condition accurately. IMA may be a sensitive marker for CIN but further studies are required to confirm its usefulness.

Keywords: Contrast media (CM), Contrast-enhanced computed tomography (CECT), Contrast-induced nephropathy (CIN), Creatinine, Ischemia-modified albumin (IMA), Paraoxonase-1 (PON-1).

Introduction

Contrast-enhanced computed tomography (CECT) is an imaging technique involving the administration of a contrast medium (CM) used to visualize and characterize internal organs and structures. Adverse allergic or physiologic reactions, including contrast-

induced nephropathy (CIN), may follow CM administration (1). More than 10% of patients undergoing CECT develop CIN (2), thereby establishing it as the third-most common cause of iatrogenic acute renal failure (3, 4). Further, in a

1: Department of Biochemistry, Kasturba Medical College, Manipal University, Manipal, India.

2: Department of Biochemistry, Melaka Manipal Medical College, Manipal University, Manipal, India.

3: Department of Nephrology, Kasturba Hospital, Manipal, India.

4: Department of Surgery, Kasturba Hospital, Manipal, India.

*Corresponding author: Shobha Ullas Kamath; Tel: +91 9986104763, Fax: +91 9986104763, E-mail: shobha.kamath@manipaledu.

Received: 21 May, 2018; Accepted: 17 Jul, 2018

meta-analysis, CIN incidence was 6% (5). The iodinated contrast agents used for imaging studies, including CECT, are principally of three types; low, high, and iso-osmolar based on their osmolality. Although a potential relationship between contrast media osmolality/ionicity and nephrotoxicity is dubious, in a recent study no significant association was found between the two (6). Contrast media can injure the renal medulla due to direct tubular cell toxicity resulting from free radical release and decreased renal perfusion with consequent ischemia, and thus may be involved in the pathogenesis of CIN (7, 8). In addition, animal studies suggest that CM reduces antioxidant enzyme activities and the cytotoxic effects are mediated by oxygen free radicals (9-11). Although many studies have investigated ischemia-modified albumin (IMA) in various disorders including end stage renal disease, diabetes mellitus, and hyperlipidemia, to the best of our knowledge, none have examined it in CECT patients, who are at risk for contrast-induced renal ischemia and/or CIN. Ischemia-modified albumin is human serum albumin, wherein the N-terminal end, which is responsible for temporary binding of metal ions including Co^{2+} , Ni^{2+} , and Cu^{2+} , gets modified under oxidative or ischemic conditions resulting in reduced binding affinity (12). Thus, we investigated IMA serum levels to test its efficacy in identifying ischemia after CM administration.

In clinical settings, before CM administration, serum creatinine is frequently used as a marker for overall renal function, despite the fact that this conventional biomarker may be affected by various non-renal factors, and the levels may vary with age, gender, muscle mass, weight, diet, and ethnicity (13-15). Further, serum creatinine is a marker of renal function and not renal damage, such that creatinine is elevated only at advanced stages of renal dysfunction, and only after approximately two-thirds of renal biomass has been lost (16). Because damage precedes functional alterations, estimation of IMA, an acute ischemia marker, can delineate renal damage at a much earlier stage than creatinine. Moreover, the current practice to define CIN is “reduction in renal function following contrast media administration, characterized by a ≥ 0.5 mg/dL or $\geq 25\%$ increase in serum creatinine level

from baseline, within 48–72 hours after CM administration” (17,18). This could lead to under-estimation of CIN, which could be greater when IMA is used as a marker, either alone or in combination with creatinine. This is because an IMA increase was found to be a significant predictor of ischemic damage (19).

In addition, we studied the potential correlation between IMA and PON-1, a calcium-dependent esterase associated with HDL sub-fractions containing apo A-I and clusterin, which protects against oxidation. Studies have revealed reduced PON-1 levels in end-stage renal disease, obesity, and cardiovascular diseases, suggesting that HDL is altered under oxidative stress conditions, resulting in reduced PON-1 activity. This leads to increased oxidative stress and favors IMA formation (20). Because CECT patients are at risk for oxidative damage post-CM administration, estimating PON-1 activity in these patients may add to information regarding patient status post-CECT. Contrast-induced nephropathy is also referred to as contrast-induced acute kidney injury (CIAKI) as per the Kidney Disease Initiative Global Outcome (KDIGO) guidelines in 2012.

Materials and methods

Study population

In this prospective study, 48 adult inpatients scheduled for intravenous CM administration for CECT at Kasturba hospital (located in Manipal, Karnataka, India) were enrolled, regardless of the body region and indication for CECT. The enrollment period was February to May 2017. Twenty-six (54%) of the subjects were males and 22 (46%) were females. Their average age was 53 ± 14 years (range, 28-76 years). Each subject received an intravenous injection of an iodinated, non-ionic contrast medium (Ultravist or Omnipaque) just before the procedure. Patients with advanced renal, liver, or heart failure, HIV, age < 18 or > 70 years, those who refused to participate, and pregnant or breast-feeding females were excluded. Written informed consent was obtained from all the patients and this study was approved by the Institutional Ethics Committee. The study protocol was in accordance with Helsinki Declaration.

Sample collection

Blood was collected by venous puncture from all study participants 12-24 hours both before and after CM administration into red-top vacutainer tubes (BD Diagnostics). The blood samples were centrifuged within 1 hr of collection for 10 min at 2500 x g. Sera were aliquoted into Eppendorf tubes and stored at -20 °C until analysis (less than 8 weeks).

Biochemical analysis

Serum IMA and PON-1 activity were estimated according to manual colorimetric methods described by Bar-Or et al. (21) and Dantoine et al. (22) respectively. For IMA, 50 μ l of cobalt chloride ($\text{CoCl}_2 \cdot 6\text{H}_2\text{O}$; 1 gm/L) was added to 200 μ l of serum, gently mixed, and incubated at room temperature for 10 min to allow adequate cobalt-albumin binding. Subsequently, 50 μ l of dithiothreitol (DTT; 1.5 gm/L) was added as a colorizing agent, followed by the addition of 1 ml of NaCl (9 gm/L) 2 minutes later. A blank was prepared without DTT. Color developed was measured spectrophotometrically (Genesys 10 UV) at 470 nm and expressed as absorbance units (ABSU).

For PON-1, 250 μ l of 1/20 prediluted serum was added to 2 ml of Tris-HCl buffer (25 mM, pH 7.4) containing 1 mM CaCl_2 , 2.5% methanol, and 0.625 mM p-nitrophenyl acetate. The rate of p-nitrophenol generation was determined spectrophotometrically at 402 nm ($\epsilon_{402} = 14,000 \text{ M}^{-1}\text{Cm}^{-1}$ at pH 7.4) and the enzyme activity was expressed in U/mL of serum (1 U of the paraoxonase activity produces 1 μ mol of p-nitrophenol per min).

Creatinine was estimated by the Jaffes method in a Cobas® 6000 analyzer (Roche Diagnostics).

Statistical analysis

Data with Gaussian distributions were expressed as means \pm SDs. For the non-Gaussian data, Wilcoxon's Signed Ranks test was used and differences in the IMA, PON-1, and creatinine levels between pre- and post-CECT groups were evaluated. Pearson's correlation was used to evaluate relationships between parameters. Statistical significance was assumed at $p < 0.05$ and all tests were two-tailed. Statistics were analyzed using SPSS package version 16.

Results

The IMA values were significantly greater ($p < 0.001$) (Fig. 1) and PON-1 values were significantly less ($p < 0.001$) (Fig. 2) in post- than in pre-CECT patients. No significant differences were seen between pre- and post-CECT creatinine levels ($p = 0.073$) (Fig. 3). No correlation was found between IMA and PON-1 or IMA and creatinine in either the pre- or post-CECT samples (Table 1). The median difference in serum IMA between the pre- and post-CECT samples was 0.147 ABSU (0.098-0.210).

Table 1. Correlation of IMA with PON-1 and creatinine in CECT patients

| | | r | p |
|-----------|------------|--------|-------|
| Pre -CECT | PON-1 | -0.142 | 0.337 |
| | creatinine | -0.158 | 0.284 |
| Post-CECT | PON-1 | -0.195 | 0.183 |
| | creatinine | 0.124 | 0.401 |

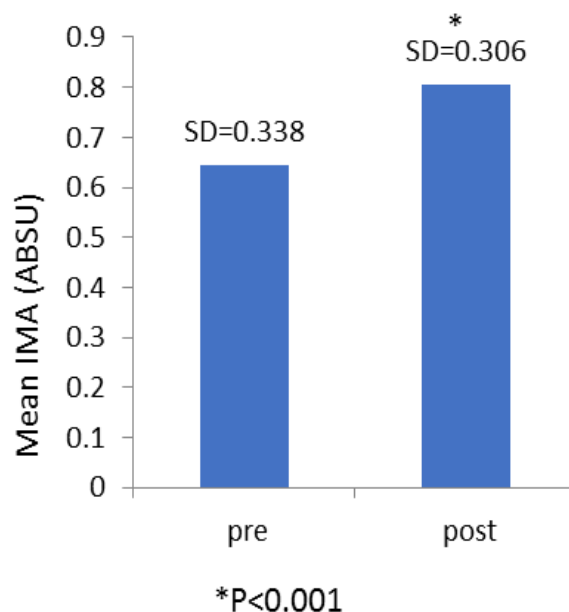


Fig. 1. IMA – ischemia modified albumin; pre – IMA value prior to CM administration; post – IMA value post CM administration; SD – standard deviation; p = significance) Mean IMA levels in pre- and post-CECT samples. Serum samples were collected 12-24 hr both pre- and post-CECT. Ischemia-modified albumin (IMA) was measured in serum samples by spectrophotometry at 470 nm and expressed as absorbance unites (ABSU) after cobalt binding.

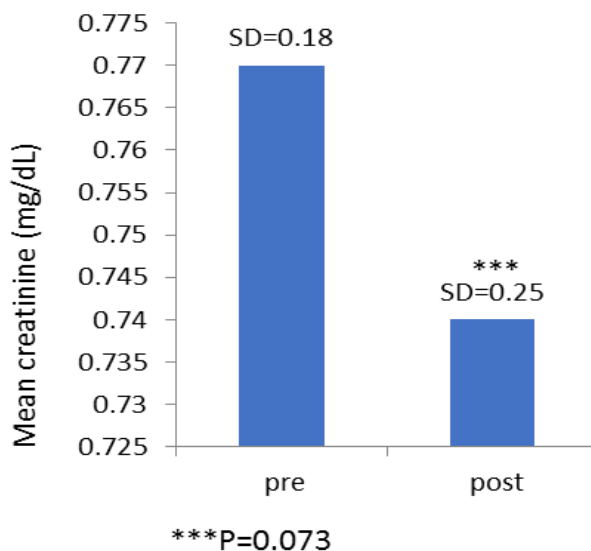


Fig. 2. PON – serum paraoxanase; pre – IMA value prior to CM administration; post – IMA value post CM administration; SD – standard deviation; p = significance) Mean PON-1 levels in pre- and post-CECT samples. Serum samples were collected 12-24 hr pre- and post-CECT. PON-1 activity, expressed as U/mL of serum, was determined spectrophotometrically at 402 nm via p-nitrophenol generation.

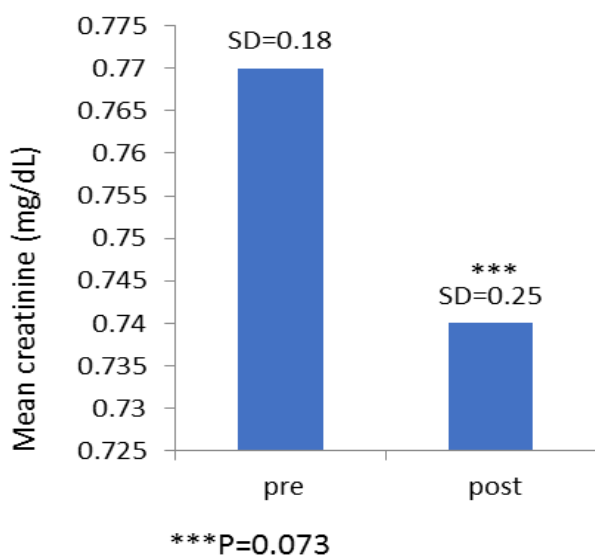


Fig. 3. pre – IMA value prior to CM administration; post – IMA value post CM administration; SD – standard deviation; p = significance) Mean creatinine concentrations in pre- and post-CECT samples. Serum samples were collected 12-24 hr pre- and post CECT. Serum creatinine concentrations were determined by the Jaffes method a Cobas® 6000 analyzer (Roche Diagnostics).

Discussion

The use of CM for radiographic procedures is ever-expanding, such that approximately 70 million CT scans are performed annually in the United States alone (23), and the global market is expected to

reach USD 5.44 billion by 2021, from USD 4.46 billion in 2016. Globally, North America is the largest CM market, followed by Europe and Asia-Pacific (24). Such comprehensive data in the Indian context is scarce, although CECT is a fairly common procedure, especially for detecting lesions in cancer patients. Although in recent decades, significant attempts have been made to make CM safer and more tolerable, its use is not yet devoid of risks, and adverse effects, ranging from minor physiological to severe anaphylactic reactions, have occurred following intravenous CM administration. Of these adverse effects, CIN is well known (1).

The current clinical practice to estimate CIN cases is based on serum creatinine measurement, which is not an ideal marker of renal injury. It does not allow differentiation between pre-renal and renal causes of kidney injury and is affected by physiologic factors including age, gender, and hydration status. Following CM administration, serum creatinine concentration begins rise within 24 hr, peaks in 2-5 days, and returns to baseline in 1-3 weeks. This implies that follow-up creatinine should be obtained 48-72 h following CM exposure in all at-risk patients, thus delaying treatment for patients who might develop CIN and, on the contrary, prolonging hospital stays for patients who would not develop CIN (25, 26). Also, creatinine concentrations can vary day-to-day despite any underlying pathology (27). Because CECT is usually performed to detect malignant lesions, creatinine levels can be significantly altered depending on the patient's anti-cancer therapy. These limitations have inspired researchers to seek novel CIN markers not affected by confounders that can indicate early-stage renal damage.

In this study, we evaluated serum IMA, which could be one such marker. Ischemia-modified albumin has been extensively studied as an oxidative stress marker in pregnancy, pre-eclampsia, and multiple sclerosis, and also as a marker of acute ischemia (28-33). Such a biomarker may be helpful in identifying ischemia subsequent to CECT, which is missed with current diagnostic strategies. The structure of normal serum albumin changes in ischemia and this structural change can be detected by the albumin cobalt-binding method used in this study to measure IMA (34). Moreover, the major advantage of IMA as a marker is that its

elevation does not require necrosis; rather, elevated levels are achieved in early stages of ischemia. Ischemia-modified albumin rises within minutes of an ischemic event, peaks within 2-4 hours, and returns to baseline within 6-12 hours (33, 34).

In this study, the serum IMA levels were greater in post- than in pre-CECT samples, suggesting that CM induced ischemic/hypoxic events. This result could be due to free radical release during ischemia directly associated with elevated IMA (35). This idea was further supported by the reduced PON-1 levels in post-CECT patients in this study. We studied PON-1 to investigate the relevance of IMA. PON-1 contributes to the anti-oxidative activity of HDL, so that its level may be reduced in various oxidative stress conditions owing to its consumption for the prevention of oxidation (36, 37). Additionally, PON-1 is considered a negative acute-phase protein, such that its level may fall under ongoing inflammatory processes in the body (38), and CM injection could induce the process. The

relatively small study population and investigation at a single center were the limitations of this study.

Our study showed that IMA increases and PON-1 decreases after CM was injected into patients undergoing CECT. Such altered levels could be associated with ischemia or oxidative activity. Although creatinine is the gold standard for overall renal function assessment, early stages of renal damage may be missed by this marker. A combined estimation of these parameters may aid in identifying patients at risk for CIN and its early diagnosis, and even guide therapeutic interventions. Further detailed large-scale and multi-centric studies are required to validate the use of IMA as a diagnostic tool in CECT patients.

Acknowledgment

We would like to acknowledge department of Biochemistry, KMC, Manipal, MAHE for the infrastructural support provided.

References

- Rose TA, Choi JW. Intravenous imaging contrast media complications: the basics that every clinician needs to know. *The American journal of medicine*. 2015;128(9):943-9.
- Mitchell AM, Jones AE, Tumlin JA, Kline JA. Incidence of contrast-induced nephropathy after contrast-enhanced computed tomography in the outpatient setting. *Clinical Journal of the American Society of Nephrology*. 2010;5(1):4-9.
- Hou SH, Bushinsky DA, Wish JB, Cohen JJ, Harrington JT. Hospital-acquired renal insufficiency: a prospective study. *The American journal of medicine*. 1983;74(2):243-8.
- Nash K, Hafeez A, Hou S. Hospital-acquired renal insufficiency. *American Journal of Kidney Diseases*. 2002;39(5):930-6.
- Kooiman J, Pasha SM, Zondag W, Sijpkens YW, van der Molen AJ, Huisman MV, et al. Meta-analysis: serum creatinine changes following contrast enhanced CT imaging. *European journal of radiology*. 2012;81(10):2554-61.
- Solomon R. Contrast media: are there differences in nephrotoxicity among contrast media? *BioMed research international*. 2014;2014.
- Bakris GL, Lass N, Gaber AO, Jones JD, Burnett JC. Radiocontrast medium-induced declines in renal function: a role for oxygen free radicals. *American Journal of Physiology-Renal Physiology*. 1990;258(1):115-20.
- Sendeski MM. Pathophysiology of renal tissue damage by iodinated contrast media. *Clinical and Experimental Pharmacology and Physiology*. 2011;38(5):292-9.
- Ueda J, Nygren A, Hansell P, Ulfendahl H. Effect of intravenous contrast media on proximal and distal tubular hydrostatic pressure in the rat kidney. *Acta Radiologica*. 1993;34(1):83-7.
- Katholi RE, Woods W, Taylor GJ, Deitrick CL, Womack KA, Katholi CR, et al. Oxygen free radicals and contrast nephropathy. *American Journal of Kidney Diseases*. 1998;32(1):64-71.

11. Hizoh I, Haller C. Radiocontrast-induced renal tubular cell apoptosis: hypertonic versus oxidative stress. *Investigative radiology*. 2002;37(8):428-34.
12. Ukinc K, Eminagaoglu S, Ersoz HO, Erem C, Karahan C, Hacıhasanoglu AB, et al. A novel indicator of widespread endothelial damage and ischemia in diabetic patients: ischemia-modified albumin. *Endocrine*. 2009;36(3):425-32.
13. Shemesh O GH, Kriss JP, Myers BD. Limitations of creatinine as a filtration marker in glomerulopathic patients. *Kidney Int*. 1985;28:830-8.
14. Rule AD, Bailey KR, Schwartz GL, Khosla S, Lieske JC, Melton LJ. For estimating creatinine clearance measuring muscle mass gives better results than those based on demographics. *Kidney international*. 2009;75(10):1071-8.
15. Fuchs TC, Hewitt P. Biomarkers for drug-induced renal damage and nephrotoxicity—an overview for applied toxicology. *The AAPS journal*. 2011;13(4):615-31.
16. Pfaller W, Gstraunthaler G. Nephrotoxicity testing in vitro—what we know and what we need to know. *Environmental health perspectives*. 1998;106(Suppl 2):559.
17. Mehran R, Nikolsky E. Contrast-induced nephropathy: definition, epidemiology, and patients at risk. *Kidney International*. 2006;69:S11-S5.
18. Ludwig U, Keller F. Prophylaxis of contrast-induced nephrotoxicity. *BioMed research international*. 2014;2014.
19. Sharma R, Gaze DC, Pellerin D, Mehta RL, Gregson H, Streather CP, et al. Evaluation of ischaemia-modified albumin as a marker of myocardial ischaemia in end-stage renal disease. *Clinical Science*. 2007;113(1):25-32.
20. Kotani K, Kimura S, Gugliucci A. Paraoxonase-1 and ischemia-modified albumin in patients with end-stage renal disease. *Journal of physiology and biochemistry*. 2011;67(3):437-41.
21. Bar-Or D, Lau E, Winkler JV. A novel assay for cobalt-albumin binding and its potential as a marker for myocardial ischemia—a preliminary report. *The Journal of emergency medicine*. 2000;19(4):311-5.
22. Dantoine TF, Debord J, Charnes J-P, Merle L, Marquet P, Lachatre G, et al. Decrease of serum paraoxonase activity in chronic renal failure. *Journal of the American Society of Nephrology*. 1998;9(11):2082-8.
23. Mettler Jr FA, Thomadsen BR, Bhargavan M, Gilley DB, Gray JE, Lipoti JA, et al. Medical radiation exposure in the US in 2006: preliminary results. *Health Physics*. 2008;95(5):502-7.
24. Contrast Media/Contrast Agent Market by Type (Iodinated, Gadolinium, Barium, & Microbubble), Procedure (X-Ray/CT, MRI, & Ultrasound) & Application (Radiology, Interventional Radiology, & Interventional Cardiology) - Global Forecasts to 2021 [marketsandmarkets.com](http://www.marketsandmarkets.com); 2016. Available from: <http://www.marketsandmarkets.com / Market-Reports/contrast-media-market-911.html>.
25. Briguori C, Quintavalle C, Donnarumma E, Condorelli G. Novel Biomarkers for Contrast-Induced Acute Kidney Injury. *BioMed Research International*. 2014;2014:5.
26. Wybraniec MT, Mizia-Stec K. Renalase and Biomarkers of Contrast-Induced Acute Kidney Injury. *Cardiorenal Medicine*. 2015 09/19;6(1):25-36.
27. Newhouse JH, Kho D, Rao QA, Starren J. Frequency of serum creatinine changes in the absence of iodinated contrast material: implications for studies of contrast nephrotoxicity. *American Journal of Roentgenology*. 2008;191(2):376-82.
28. Aydin O, Ellidag HY, Eren E, Kurtulus F, Yaman A, Yilmaz N. Ischemia modified albumin is an indicator of oxidative stress in multiple sclerosis. *Biochimica Medica*. 2014;24(3):383-9.
29. Bahinipati J, Mohapatra PC. Ischemia Modified Albumin as a Marker of Oxidative Stress in Normal Pregnancy. *Journal of Clinical and Diagnostic Research : JCDR*. 2016;10(9):15-17.
30. Üstün Y, Engin-Üstün Y, Öztürk Ö, Alanbay I, Yaman H. Ischemia-modified albumin as an oxidative stress marker in preeclampsia. *The Journal of*

Maternal-Fetal & Neonatal Medicine. 2011;24(3):418-21.

31. Abboud H, Labreuche J, Meseguer E, Lavallee PC, Simon O, Olivot JM, et al. Ischemia-Modified Albumin in Acute Stroke. *Cerebrovascular Diseases*. 2007;23(2-3):216-20.

32. Gunduz A, Turedi S, Mentese A, Karahan SC, Hos G, Tatli O, et al. Ischemia-modified albumin in the diagnosis of acute mesenteric ischemia: a preliminary study. *The American Journal of Emergency Medicine*. 2008 2008/02/01;26(2):202-5.

33. Sinha MK, Gaze DC, Tippins JR, Collinson PO, Kaski JC. Ischemia Modified Albumin Is a Sensitive Marker of Myocardial Ischemia After Percutaneous Coronary Intervention. *Circulation*. 2003;107(19):2403-5.

34. Bar-Or D, Winkler JV, VanBenthuyzen K, Harris L, Lau E, Hetzel FW. Reduced albumin-cobalt binding with transient myocardial ischemia after elective percutaneous transluminal coronary angioplasty: a preliminary comparison to creatine

kinase-MB, myoglobin, and troponin I. *American heart journal*. 2001;141(6):985-91.

35. Roy D, Quiles J, Gaze D, Collinson P, Kaski J, Baxter G. Role of reactive oxygen species on the formation of the novel diagnostic marker ischaemia modified albumin. *Heart*. 2006;92(1):113-4.

36. Aviram M, Kaplan M, Rosenblat M, Fuhrman B. Dietary antioxidants and paraoxonases against LDL oxidation and atherosclerosis development. *Atherosclerosis: Diet and Drugs*: Springer; 2005. p. 263-300.

37. Razavi AE, Ani M, Pourfarzam M, Naderi GA. Associations between high density lipoprotein mean particle size and serum paraoxonase-1 activity. *Journal of Research in Medical Sciences*. 2012;17(11):1020-6.

38. Novak F, Vavrova L, Kodydkova J, Novak F Sr, Hynkova M, Zak A, Novakova O: Decreased paraoxonase activity in critically ill patients with sepsis. *Clin Exp Med*. 2010;10:21-25.