

Partial Distal 10q Trisomy Due to De Novo Amplification: A new Case Without Furrows or Ridges in Fingers and Palms

Aliakbar Rahbarimanesh¹, Pupak Derakhshandeh-Peykar*^{1,2,3}, Amirhassan Barkhordari¹, Reza Ebrahimzadeh-Vesal², Soja Shamizadeh Kalkhoran¹

Abstract

Background: Here we describe a new case of partial distal 10q trisomy in a 6-year-old Iranian girl from healthy parents with mental, growth, and psychomotor retardations.

Methods: Additional clinical features include dysmorphic craniofacial features, microcephaly, bilateral hydronephrosis without heart problems, small and rotated low-set ears, bow-shaped mouth, abnormal teeth, short neck, and as a first case reported, fingers with camptodactyly (i.e., without any furrows or ridges in the palms and fingers).

Results: Cytogenetic analysis (GTG-banding) revealed an unbalanced female karyotype with additional bands at the end of the long arm of chromosome 10, karyotype: 46,XX,dup(10)(q25q26).

Conclusion: According to the banding pattern it is most likely that a duplication of the distal part of the long arm of chromosome 10 occurred.

Keywords: De novo, Distal, Trisomy, 10q

Introduction

Trisomy is a genetic abnormality in which there are three copies, instead of the normal two, of a particular chromosome. Trisomies can occur for any chromosome, but often result in miscarriages. Trisomy 10 is a rare and lethal condition, which accounts for about 1.8% of all spontaneous abortions (1-2).

Partial duplications of chromosome 10 (partial trisomies) are rare and result in a pattern of malformations and dysmorphic features (3). In this paper a child with a trisomy of 10q25 is presented.

Methods

Index Case

A 6-year-old Iranian girl with mental retardation, abnormal appearance, hypertelorism, dental deformity, gastroenteritis, and respiratory distress was presented to us

(Fig. 1). She was born by Caesarian section. Her parents were non-consanguineous and both were apparently healthy and normal. Birth weight and height were 3,100 gm and 50 cm, respectively. After birth, the girl was hospitalized for a week in neonatal intensive care unit for sepsis. No history of neonatal jaundice has been reported. At the age of 12 days, she was admitted for fever and malaise in Taleghani Hospital. She had a history of seizures since the age of 2 (medication: Valproate and Clobazam). The patient had no heart murmurs. However, pectus excavatum, as well as severe muscle atrophy and a short Achilles tendon were noticeable. Hydronephrosis and bilateral urothelium hyperplasia in the kidneys was found. The patient has neither abdominal distension nor skin pigmentation, and no specific lesions or organomegaly were seen. All fingers of the patient had hyperextension (Fig. 1A) and exhibited camptodactyly, and lack of any furrows in the palms and fingers (Fig. 1C).

1: Bahrami hospital, Medical Sciences/University of Tehran, Iran, PO Box 14155-1595.

2: Department of Medical Genetics, Medical Sciences/University of Tehran, Iran, PO Box 14155-1595

3: Medizinisch Genetisches Zentrum (MGZ), Munich, Germany, P.O. Box 201412

*Corresponding author. Tel.: +49 89- 15254230228; Fax: +49 89- 309088666, Email: derakhshandeh@tums.ac.ir

Received: Oct 28, 2012; Accepted: Jan 21, 2013

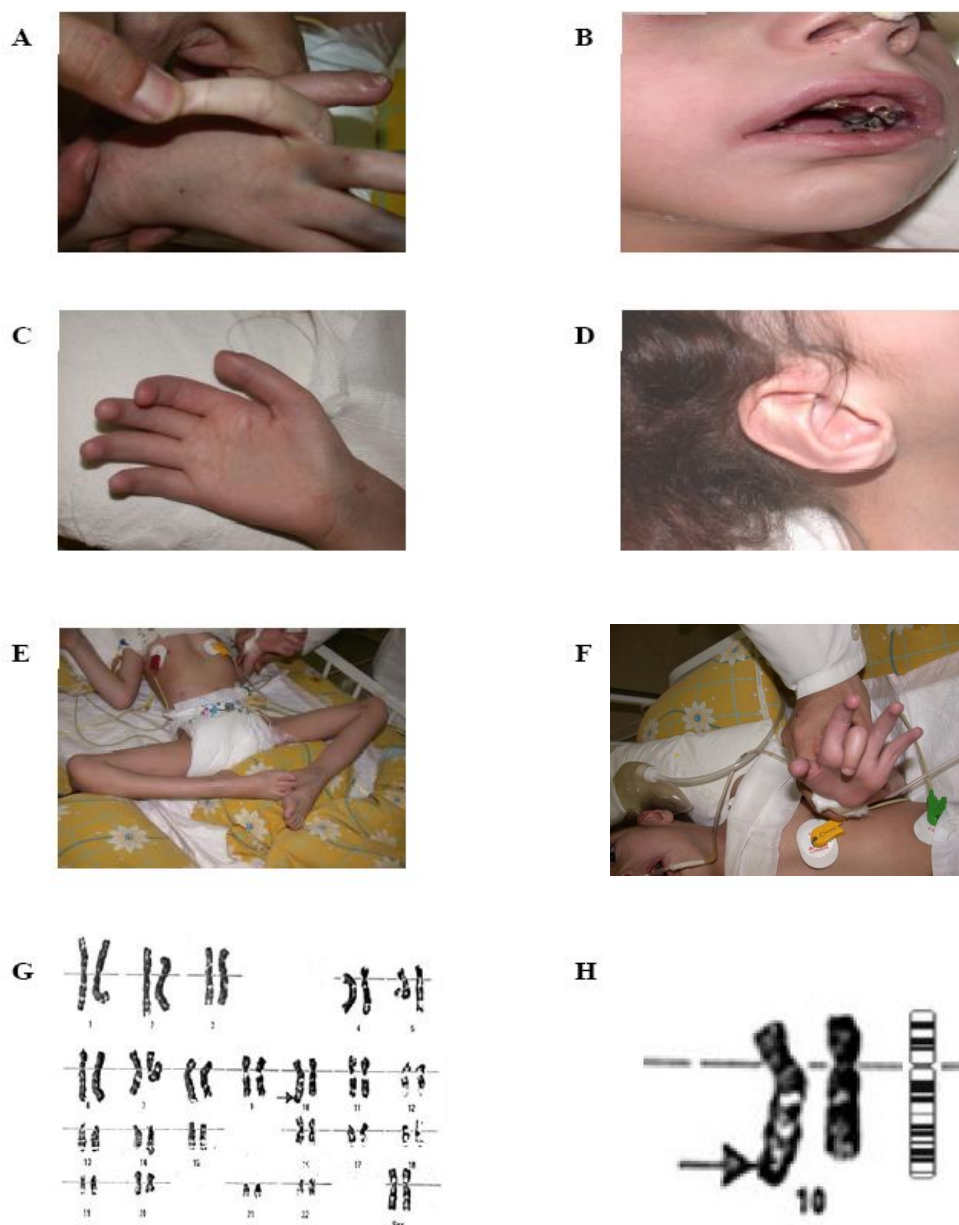


Fig. 1. The proband with 46, XX,dup(10)(q25q26) showing global abnormal appearance and dysmorphic features: fingers with hyperextension (A); bow-shaped mouth, as well as dental deformity (B); camptodactyly and loss of palmar lines (C); small, low set, flat, and thick ears with rotation in ear helix (D); pectus excavatum in addition to slender limbs with severe muscle atrophy (E); Crossed finger (F); GTG banded karyotype with 46, XX,dup(10)(q25q26) (arrows) (G), and a larger version of partial distal trisomy of 10q (H).

She has shown a number of developmental delays, started heading at the age of 2, sitting at the age 3, and walking at the age of 4.5 years. She now walks with an aid, is able to speak a few words, and presents with feeding problems. Patient's head is microcephalic with low-set ears. Ultrasound of the kidneys shows bilateral hydronephrosis. Ultrasound imaging of the chest showed no particular problems. The characteristic

features of our case are compared with some previously reported cases of trisomy 10 in Table 1. Microbial blood culture test, cerebrospinal fluid (CSF), and urine cultures gave negative results. Biochemical, hematological test results, and amino acid chromatographies of serum and urine were within the reference ranges.

Cytogenetic Study

A total of 20 metaphase chromosome spreads from peripheral blood lymphocytes were analyzed using GTG banding at 400 band resolution, revealing a

46,XX,dup(10)(q25q26) karyotype, with an extra unidentified segment on the long arm of chromosome 10 (Fig. 1G and 1H).

Table 1. Comparison of the main clinical features with five previously reported cases of partial Trisomy 10.

Characteristics	de France et al. (1985) (4)	Mielke et al. (1997) (5)	Knoblauch et al. (1999) (2)	Brizot et al. (2001) (6)	Our Case
Birth weight/ week (g/week)	1,930/41	1,930/41	ND	1,020/35	3.100/38
Feeding problems	+	+	+	+	+
Developmental delay	+	+	+	+	+
Skull abnormality (Microcephaly)	+	+	+	+	+
Hypertelorism	+	+	+	+	+
High arched palate	ND	+	ND		+
Cleft lip/Palate	ND	ND	ND	+	-
Low-set malformed large ears	+	+	+	+	+
Short neck	+	ND	ND	+	+
Micrognathia	+	ND	+	+	+
Cardiac malformations	+	+	+	+	-
Renal agenesis	ND	+	ND	+	+
Deformity of hands	ND	+	ND	+	+
Deformity of feet	ND	ND	+	+	+
Seizure	+	ND	ND	ND	+
Marked plantar and palmar furrows	+	ND	ND	ND	-

Results and Discussion

Partial autosomal trisomies have been suggested to possibly occur from unequal crossing overs or spontaneous reciprocal translocations during meiosis, involving homologous chromosomes (7). Complete trisomy for chromosome 10, which has been associated with increased maternal age, is not viable and leads to abortion (1, 8). Similar to the present case, in previously reported live-born infants with trisomy 10, usually mosaics or partial 10q trisomy has been detected (4, 9-10).

Liver agenesis has not been previously reported in the literature. However, renal agenesis has been described (Table 1).

Lam and colleagues reported a Chinese girl with a de novo duplication of 10q11.2-q22.3 who displayed not only common features of the previously reported cases but also had anal

atresia, which was distinctive (3). Recently, a case of severe central hypotonia, bifid scrotum, cryptorchidism, and deep palmar creases of the hands and feet has been identified by a CGH (dup(10)(q11.1q11.21) (11).

Our patient has a de novo duplication 46,XX,dup(10)(q25q26), exhibiting finger hyperextension without palm lines, in addition to common abnormal features. Although genetic analysis revealed no additional rearrangements other than the 10(q25) duplication, it has not been confirmed whether the additional clinical features in this case are due only to the partial 10q trisomy. A study by Hahnemann and colleagues reported a maternal trisomy 10 mosaicism and uniparental disomy 10 in a live-born infant, with a novel aplasia of the optic nerve, who died in early infancy due to severe congenital

malformations (2). In a recent case report (12) an isolated trisomy 10 in an infant with a rare incidence of acute myeloid leukemia was observed. In brief, the patient presented here, with autosomal XX,dup(10)(q25q26) displays not only common features of some previously reported cases but also a rare different abnormal phenotype, the loss of the palmar furrows and ridges, which has not been previously reported.

References

1. Hassold T, Merrill M, Adkins K, Freeman S, Sherman S. Recombination and maternal age-dependent nondisjunction: molecular studies of trisomy 16. *Am J Hum Genet.* 1995 Oct;57(4):867-74.
2. Knoblauch H, Sommer D, Zimmer C, Tennstedt C, Heling K, Bollmann R, et al. Fetal trisomy 10 mosaicism: ultrasound, cytogenetic and morphologic findings in early pregnancy. *Prenat Diagn.* 1999 Apr;19(4):379-82.
3. Lam FW, Chan WK, Lam ST, Chu WP, Kwong NS. Proximal 10q trisomy: a new case with anal atresia. *J Med Genet.* 2000 Sep;37(9):E24.
4. de France HF, Beemer FA, Senders RC, Schaminee-Main SC. Trisomy 10 mosaicism in a newborn boy; delineation of the syndrome. *Clin Genet.* 1985 Jan;27(1):92-6.
5. Mielke G, Enders H, Goelz R, Klein-Vogler U, Ulmer R, Trautmann U. Prenatal detection of double aneuploidy trisomy 10/monosomy X in a liveborn twin with exclusively monosomy X in blood. *Clin Genet.* 1997 Apr;51(4):275-7.
6. Brizot ML, Schultz R, Patroni LT, Lopes LM, Armbruster-Moraes E, Zugaib M. Trisomy 10: ultrasound features and natural history after first trimester diagnosis. *Prenat Diagn.* 2001 Aug;21(8):672-5.

Acknowledgments

We duly acknowledge the family who cooperated with this study. We also would like to thank Dr. Mehrdad Pedram (Dept. of Medical Genetics, TUMS) and Dr. Udo Koehler (MGZ) for his careful proofreading of the manuscript and helpful comments and suggestions.

7. Vogel W, Back E, Imm W. Serial duplication of 10 (q11 leads to q22) in a patient with minor congenital malformations. *Clin Genet.* 1978 Feb;13(2):159-63.
- 8 Gardner RJ, Sutherland GR. *Chromosome Abnormalities and Genetic Counselling.* 2nd ed. New York: Oxford University Press; 1997.
9. Hahnemann JM, Nir M, Friberg M, Engel U, Bugge M. Trisomy 10 mosaicism and maternal uniparental disomy 10 in a liveborn infant with severe congenital malformations. *Am J Med Genet A.* 2005 Oct 1;138A(2):150-4.
10. Mahjoubi F, Akbari MT, Babamohammadi G. Clinical features of a case with trisomy 10q and monosomy 3p resulting from a maternal balanced translocation *Journal of Pediatric Neurology.* 2008;6(3):273-6.
11. Manolakos E, Vetro A, Kefalas K, Rapti SM, Louizou E, Garas A, et al. The use of array-CGH in a cohort of Greek children with developmental delay. *Mol Cytogenet.* 2010;3:22.
12. Yuan J, McDonough C, Kulharya A, Ramalingam P, Manaloor E. Isolated trisomy 10 in an infant with acute myeloid leukemia: a case report and review of literature. *Int J Clin Exp Pathol.* 2010;3(7):718-22.