

A genetic Assay of Three Patients in the Same Family with Holt-Oram Syndrome; a Case Report

Reza Ebrahimzadeh-Vesal¹, Seyed kianush Hosseini²,
Fereshteh Rezakhanlu², Pupak Derakhshandeh-Peykar^{*1,3}

Abstract

Holt-Oram syndrome (HOS) is a developmental disorder inherited in an autosomal-dominant pattern. Affected organs are the heart and forelimbs with upper extremity skeletal defects and congenital heart malformation. In this study we present three cases of HOS in the same family. In one of these three individuals we detected a transition of C to T (CTG-GTT, V205V) in exon 7 of the TBX5 gene. This nucleotide change causes no amino acid change and potential pathologic effects remain unknown.

Keywords: Congenital heart malformation, Holt-Oram syndrome, TBX5 gene

Introduction

Holt-Oram syndrome (HOS) is a developmental disorder inherited in an autosomal-dominant pattern. Affected organs are the heart and forelimbs with upper extremity skeletal defects and congenital heart malformation. This syndrome was first described by Holt and Oram (1), who observed atrial septal defect in members of four generations of a family associated with a congenital anomaly of the thumbs.

Haploinsufficiency of TBX5 on the human chromosome 12 (12q24.1) is the cause of HOS (2, 3).

Holt-Oram syndrome is the most common heart-hand syndrome with an estimated frequency of about one in 100,000 live births (4). This syndrome has been reported from various racial and ethnic groups worldwide (5).

The upper-limb malformations in HOS are fully penetrant, but congenital heart malformations occur in approximately 75% of affected individuals (6).

Materials and Methods

In this study we present three cases of HOS in the same family:

Patient 1 was 23-year-old female who presented with palpitations. The electrocardiogram revealed sinus pauses with junctional escape rhythm. The echocardiogram revealed a 45 mm atrial septal defect of the ostium secundum type with enlarged right chambers, moderate pulmonary arterial hypertension (systolic pressure: 53 mmHg), mild tricuspid regurgitation, and inferior vena cava (IVC) dilation of 24 mm. These findings were confirmed during surgery.

Patient 2 was a 25-year-old male who presented with palpitations and syncope with onset at age nine. The echocardiogram revealed a large atrial septal defect of the ostium secundum type and multiple ventricular septal defects. Surgery was first performed at age nine.

Patient 3 was a 27-year-old male who presented with palpitations, dyspnea, and syncope. The echocardiogram revealed two atrial septal defects of the ostium secundum type, enlarged right chambers, and mild tricuspid and mitral regurgitation.

Peripheral blood samples of these patients were collected in EDTA anticoagulant tubes and DNA

1: Department of Medical Genetics, Medical Sciences, University of Tehran, Iran

2: Tehran Heart Center, Medical Sciences, University of Tehran, Iran

3: Medizinisch Genetisches Zentrum (MGZ), Munich, Germany

*Corresponding author: Pupak Derakhshandeh-Peykar; Tel: +49 15254230228; Fax: +49 89-309088666; E-mail: derakhshandeh@mgz-muenchen.de

Received: May 10, 2013; Accepted: July 12, 2013

was extracted using the salting out method, with modifications described previously (Fig. 1) (7).

Genomic DNA of exons 2-9 of the TBX5 gene, with NC_000012.11 as the NCBI reference sequence, was sequenced using the primers listed in Table 1.

Each exon was amplified under the following conditions: one cycle at 94 °C for 5 min, followed by 30 cycles of denaturation at 94 °C for 30 sec, annealing at 60 °C for 30 sec, and extension at 72 °C for 30 sec, and one cycle of post-elongation at 72 °C for 7 min. Each 25 µL reaction contained 20 mmol/L Tris-HCl pH 8.4, 50 mmol/L KCl, 2 mmol/L MgCl₂, 10 pmol of each primer, 0.2 mmol/L of each dNTP mix, 1.25 units of Smart Taq DNA polymerase, and 100-200 ng of genomic DNA.

Table 1. Primers used to amplify exons 2-9 of the TBX5 gene.

Exon	Primer	Size (bp)
2	Forward 5'-GCTTCTTGCTCCTCAGAGCAGAACCT-3'	277
	Reverse 5'-GCAAGAGAAGCCGAGCAGGAAAGCCA-3'	
3	Forward 5'-AGTTTGGGGAAGGAATGCCCACTAC-3'	200
	Reverse 5'-TTCTCCTCGTCCCTCTCTCTACA-3'	
4	Forward 5'-AACGGGGCTAGTTTCCGTTCCACG-3'	307
	Reverse 5'-CTTTTGGGAGAAGGTTCCACTTTT-3'	
5	Forward 5'-CCCTTAAATGGATGGAGGC-3'	261
	Reverse 5'-CTTTTGGGAGAAGGTTCCACTTTT-3'	
6	Forward 5'-CCTGGTGCCTGAACTGAAGCAGCT-3'	340
	Reverse 5'-CTGCCATTGAGAGGAGCAAGTTCC-3'	
7	Forward 5'-GAGGGAGACAAGGCGGGAATCCAG-3'	250
	Reverse 5'-GGAGGTGCTGGGTTGCTGCT-3'	
8	Forward 5'-CTTTCTGGTGGATTCTCTCACACC-3'	515
	Reverse 5'-GGGTAGGAACATGTCAAGGGAAGT-3'	
9	Forward 5'-TACTTTGGCCAAATAACTGTCTCC-3'	802
	Reverse 5'-CGACCTTGAGTGCAGATGTG-3'	

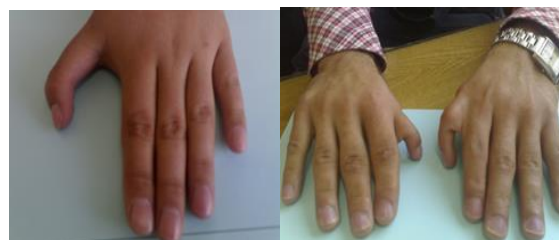

Fig. 1. Hands of patients with Holt-Oram or heart-hand syndrome. Both thumbs are abnormally short and curved.

Results

Sequence analysis of the TBX5 gene in two of our three patients identified no nucleotide changes, but in one patient we detected a C to T transition (CTG>GTT, V205V) in exon 7 of the TBX5 gene (Fig.2). This nucleotide change is at codon 205 of TBX5. This transition causes no amino acid change and potential pathologic effects remain unknown.

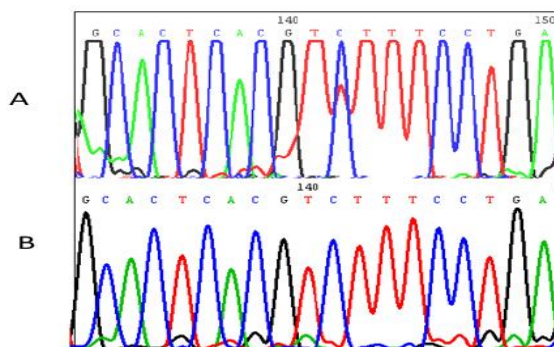


Fig. 2. Panel A shows a chromatogram of the C to T transition (GTC>GTT), c.615C>T, V205V in TBX5 gene. Panel B shows the normal sequence of the same region.

Discussion

TBX5 is a member of the T-Box gene family required in vertebrate cardiogenesis and normal heart development (8, 9). Holt-Oram syndrome is a developmental disorder with full penetrance caused by haploinsufficiency in the TBX5 gene (3). This syndrome shows variable expression as a spectrum of mutations and thereby genotype-phenotype correlation. In this syndrome cardiac involvement may be absent in patients with upper limb defects. Immunohistochemical studies with anti-human TBX5 protein antibodies demonstrated cardiac expression during embryogenesis throughout the epicardium and in cardiomyocyte nuclei in the myocardia of all four cardiac chambers (10, 11).

Clinical manifestations generally present as malformations of the upper limbs, cardiac septation defects such as atrial and ventricular septal defects (ASD and VSD, respectively), and disruption of normal cardiac conduction system development (12). Wide varieties of skeletal defects and congenital heart disease were observed; however, the severity of skeletal involvement did not parallel that of cardiac disease. Smith et al. (1979) reported five of 39 affected patients had normal EKGs despite typical limb defects (13), Basson et al. (1997) reported a nonsense mutation (Glu69-to-stop codon) in affected members of one family that caused a truncated protein without a T-box domain (2), and in another study Yang et al. (2000) identified three novel mutations that included a frame shift by deletion of one base pair, and two missense mutations in 11 Chinese patients. (14) Contiguous gene deletions of about 2.19 mega base pairs (Mbp) in TBX5 with involvement of TBX3 was reported by Borozdin et al (2006) in one Czechoslovakian mother and her two daughters, which was diagnosed as HOS. (15) Large TBX5 gene deletions have been reported with multiplex amplifiable probe hybridization (MAPH) in genomic DNA from two related patients in which the TBX5 mutation was unknown in exons 3-9 (16). TBX5 mutation screening in exons 3-9 in a five-generation family of nine affected individuals with HOS phenotype identified no mutations, but array comparative genomic hybridization (array CGH) detected a 48 kb duplication at 12q24.21 including TX5 exons 2-9 with breakpoints within introns 1-2 and 9-10 (17).

Presently, modern high-throughput DNA sequencing technologies such as pyro sequencing and next generation sequencing (NGS) can be used to search for nucleotide changes in entire candidate genes in patients with genetic disorders. These methods are improvements over exon-by-exon PCR and subsequent DNA sequencing.

Acknowledgments

We thank Prof. Dr. Bernd Rautenstrauf (MGZ), for his proofreading of the manuscript. The authors are deeply grateful to the HOS family for their collaborations. This work was supported by a grant from TUMS, grant no. 10505.

References

- Holt M, Oram S. Familial heart disease with skeletal malformations. *Br Heart J.* 1960 Apr;22(2):236-42.
- Basson CT, Bachinsky DR, Lin RC, Levi T, Elkins JA, Soultis J, et al. Mutations in human TBX5 [corrected] cause limb and cardiac malformation in Holt-Oram syndrome. *Nat Genet.* 1997 Jan;15(1):30-5.
- Li QY, Newbury-Ecob RA, Terrett JA, Wilson DI, Curtis AR, Yi CH, et al. Holt-Oram syndrome is caused by mutations in TBX5, a member of the Brachyury (T) gene family. *Nat Genet.* 1997 Jan;15(1):21-9.
- Elek C, Vitez M, Czeizel E. Holt-Oram syndrome. *Orv Hetil.* 1991 Jan 13;132(2):73-4, 7-8.
- Boehme DH, Shotar AO. A complex deformity of appendicular skeleton and shoulder with congenital heart disease in three generations of a Jordanian family. *Clin Genet.* 1989 Dec;36(6):442-50.
- Basson CT, Huang T, Lin RC, Bachinsky DR, Weremowicz S, Vaglio A, et al. Different TBX5 interactions in heart and limb defined by Holt-Oram syndrome mutations. *Proc Natl Acad Sci U S A.* 1999 Mar 16;96(6):2919-24.
- Miller SA, Dykes DD, Polesky HF. A simple salting out procedure for extracting DNA from human nucleated cells. *Nucleic Acids Res.* 1988 Feb;16(3):1215.
- Goetz SC, Brown DD, Conlon FL. TBX5 is required for embryonic cardiac cell cycle progression. *Development.* 2006 Jul;133(13):2575-84.
- Horb ME, Thomsen GH. Tbx5 is essential for heart development. *Development.* 1999 Apr;126(8):1739-51.
- Hatcher CJ, Goldstein MM, Mah CS, Delia CS, Basson CT. Identification and localization of TBX5 transcription factor during human cardiac morphogenesis. *Dev Dyn.* 2000 Sep;219(1):90-5.
- Bruneau BG, Logan M, Davis N, Levi T, Tabin CJ, Seidman JG, et al. Chamber-specific cardiac expression of Tbx5 and heart defects in Holt-Oram syndrome. *Dev Biol.* 1999 Jul;211(1):100-8.
- Moskowitz IP, Pizard A, Patel VV, Bruneau BG, Kim JB, Kupersmidt S, et al. The T-Box transcription factor Tbx5 is required for the patterning and maturation of the murine cardiac conduction system. *Development.* 2004 Aug;131(16):4107-16.
- Smith AT, Sack GH, Jr., Taylor GJ. Holt-Oram syndrome. *J Pediatr.* 1979 Oct;95(4):538-43.

14. Yang J, Hu D, Xia J, Yang Y, Ying B, Hu J, et al. Three novel TBX5 mutations in Chinese patients with Holt-Oram syndrome. *Am J Med Genet.* 2000 Jun;92(4):237-40.
15. Borozdin W, Bravo-Ferrer Acosta AM, Seemanova E, Leipoldt M, Bamshad MJ, Unger S, et al. Contiguous hemizygous deletion of TBX5, TBX3, and RBM19 resulting in a combined phenotype of Holt-Oram and ulnar-mammary syndromes. *Am J Med Genet A.* 2006 Sep;140A(17):1880-6.
16. Akrami SM, Winter RM, Brook JD, Armour JA. Detection of a large TBX5 deletion in a family with Holt-Oram syndrome. *J Med Genet.* 2001 Dec;38(12):E44.
17. Patel C, Silcock L, McMullan D, Brueton L, Cox H. TBX5 intragenic duplication: A family with an atypical Holt-Oram syndrome phenotype. *Eur J Hum Genet.* 2012 Aug;20(8):863-9.
18. Schott J-J, Benson DW, Basson CT, Pease W, Silberbach GM, Moak JP, et al. Congenital Heart Disease Caused by Mutations in the Transcription Factor NKX2-5. *Science.* 1998 July, 1998;281(5373):108-11.
19. Garg V, Kathiriya IS, Barnes R, Schluterman MK, King IN, Butler CA, et al. GATA4 mutations cause human congenital heart defects and reveal an interaction with TBX5. *Nature.* 2003 Jul;424(6947):443-7.