

# Influence of Nanocurcumin and Photodynamic Therapy Using Nanocurcumin in Treatment of Rat Tongue Oral Squamous Cell Carcinoma Through Histological Examination and Gene Expression of BCL2 and Caspase-3

Latifa Mohamed Abdelgawad\*<sup>1</sup>, Ahmed Abdullatif Abdelaziz<sup>1</sup>,  
Mahmoud Bawdy El-Begawey<sup>2</sup>, Ali Mohamed Saafan<sup>1</sup>

## Abstract

**Background:** Oral squamous cell carcinoma (OSCC) is the sixth most common mouth cancer in the world. The aim of the present study is comparing the effects of using Nanocurcumin, and photodynamic therapy (PDT), alone or together in treatment of OSCC in rats.

**Methods:** Forty Wister male rats were divided into Control (group 1), 650 nm diode Laser only (group 2), Nanocurcumin alone (group 3), and PDT with a combination of laser with Nanocurcumin (group 4). Then, OSCC in the tongue induced by dimethylbenz anthracene (DMBA). The treatments were evaluated clinically, histopathologically, and immunohistochemically through BCL2 and Caspase-3 genes expression.

**Results:** Positive control with OSCC displayed significant weight loss, while PDT group gained more than nanocurcumin treated groups as well as laser groups comparing with control positive group. The histological examination of the tongue in PDT group showed improvement. In laser group, there were partial loss of surface epithelium with various ulcers and dysplasia and partial improvement by this type of treatment. The tongue in the positive control group showed ulcer in the dorsum surface with inflammatory cells, hyperplasia of the mucosa membrane around the ulcer (acanthosis) with increase of dentition, vacuolar degeneration of prickle cell layer and increase mitotic activity of basal cell layer together with dermal proliferation.

**Conclusions:** Under the condition of the present study, PDT using nanocurcumin photosensitizer was effective in the treatment of OSCC regarding clinical, histological and gene expression of BCL2 and Caspase-3.

**Keywords:** BCL2, Caspase-3, Diode laser 650 nm, Histological analysis, Nanocurcumin, OSCC, PDT.

## Introduction

Oral squamous cell carcinoma (OSCC) is the sixth most common oral cancer, with over 500,000 cases diagnosed each year (1). It is thought to be responsible for more than 90% of all oral cancer cases and has the highest death rate in the globe (2-4). Its treatments, including surgery, radiotherapy, and chemotherapy, have

a significant impact on a patient's quality of life and are perceived as particularly harsh due to their location and intrusive nature. Photodynamic therapy treats the tumor while preserving as much shape and function as possible through proper repair (5-8).

Curcumin is a promising molecule for

1: Department of Medical Applications of Lasers, National Institute of Laser Enhanced Sciences, Cairo University, Cairo, Egypt.

2: Department of Pathology, Faculty of Veterinary Medicine, Bani Suef University, Egypt.

\*Corresponding author: Latifa Mohamed Abdelgawad; Tel: +20 1005215402; E-mail: latifa.mohamed@cu.edu.eg.

Received: 22 Sep, 2022; Accepted: 30 Oct, 2022

creating anti tumorigenic therapeutic approaches, particularly because of its low toxicity, antioxidant, and anti-inflammatory properties (9). Due to limited resorption from the gastrointestinal tract, low solubility, and quick metabolization, curcumin has a low bioavailability (10). Nanocurcumin can be used to boost curcumin levels in the bloodstream by preventing metabolic breakdown (11-12); another feasible treatment strategy is a combination of nanocurcumin (0.1-2 g/ml/Kg) with visible light (VIS) diode laser 650 nm (13).

Photodynamic therapy (PDT) is a noninvasive therapy method that has the advantages of preserving normal tissue, causing minimal pain, and being clinically approved for early-stage disease, notably cancer. It has been shown to cause tumor-specific cytotoxicity and cell death. In the presence of oxygen, a certain wavelength of light, and a photosensitizer (PS), PDT is done. Until they are exposed to light in the presence of oxygen, PDT agents are pharmacologically inactive (14-18). The aim of the present study evaluated the efficacy of nanocurcumin alone and nanocurcumin as a photosensitizer in PDT for treatment of OSCC in the rat tongue.

## Materials and Methods

### Ethical approval

The research was approved by Cairo University's Institutional Animal Care and Use Committee, Cairo University, Egypt, with identification

number code (CU-IACUC CU I F 21 18).

### Selection of the animal

A total of 40 male Wistar rats, aged 8 weeks with the weight range 120- 160 g were used in the present study.

### Induction of rat tongue Oral squamous cell carcinoma (OSCC)

Rat tongue OSCC was induced according to the protocol of Chen et al., by using topical application of the carcinogen 7, 12 di methyl benz anthracene (DMBA) at a concentration of 0.5 percent (Sigma Aldrich, Company, Saint Louis, USA) three times per week for 4 weeks with the total applications 12 times (19).

### Nanocurcumin

Nanocurcumin was obtained from (Sigma Aldrich, St. Louis, MO, USA), particle size ranged from  $200 \pm 0.2$  nanometers and 94% purity. Nanocurcumin was given orally in distilled water at a concentration of 0.1-2 ml/mg/kg (13).

### Diode laser

A continuous 650 nm wavelength (6 mm diameter) was generated using gallium aluminum arsenide diode laser equipment (5 minutes of irradiation at 200 mw, Pioon S1, China) (20, 21).

### Experiment design

Forty Wistar male rats were divided into four equal groups, each of ten rats (Table 1).

Table 1. Descriptions of animal groups were used in this study.

Group number	Group description	Subgroups	Number of Rats	Tumor induction by DMBA	Therapy	
					PDT	Nanocurcumin
1	Control	A (-ve)	5	-	-	-
		B (+ve)	5	Yes	-	-
2	PDT only		10	Yes	Yes	-
3	Nanocurcumin only		10	Yes	-	Yes
4	PDT		10	Yes	Yes	Yes

## Treatment assessment of rat tongue OSCC

### Clinical observation

The treated rats were assessed clinically by measurements of tumor volume reduction and body weight. All animals were weighted monthly for 4 months, (22). The tumor volume was measured using a caliper in both horizontal and vertical orientations and  $V = (W^2 * L) / 2$  formula was the used. The letters V, L, and W stand for tumor volume, length, and width, respectively.

Tumor volumes were measured for all experimental groups at two separate time points, after the first month after tumour induction and after 3 months after different treatments (23).

### Histopathology examination

The tongue tissues were preserved in 10% neutral buffered formalin, and sections were stained with hematoxylin and eosin (H & E) (22).

### Bcl2 and Casapase-3 expression levels measurements by ELISA

Bcl2 and Caspase-3 expression were evaluated by ELISA in accordance with the manufacturer's instructions (Simple Step ELISA kits, UK) (24-27).

### Statistical analysis

Data were presented as mean  $\pm$  standard deviation of mean, analyzed with Student's t-test for two groups of data or one-way analysis of variance with Tukey's post hoc test for multiple groups of data using SPSS, 2020. Where P value was set as ( $P < 0.05$ ) to indicate a statistically significant difference (28).

## Results

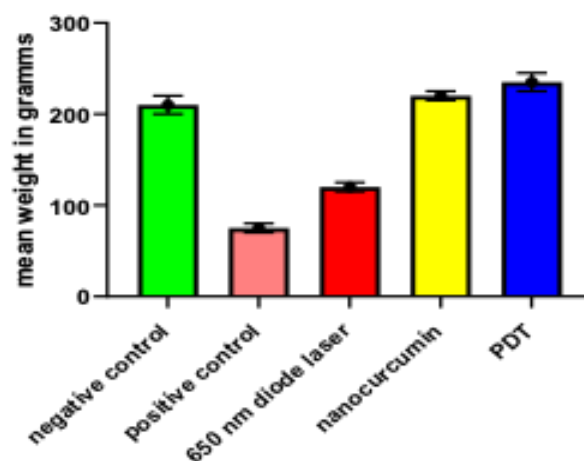
### Clinical results

#### Body weight

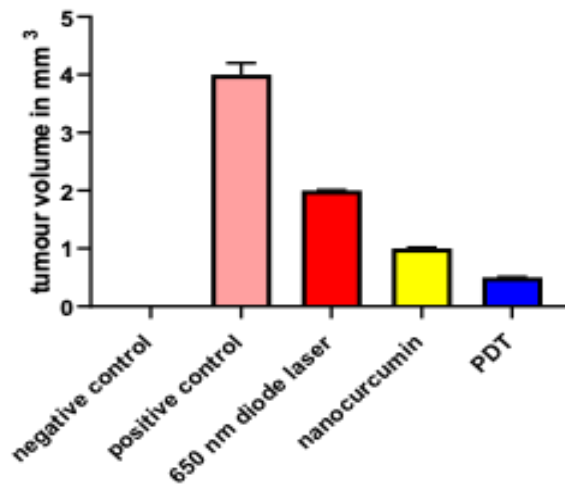
When compared to the control subgroup A, all rats receiving DMBA (subgroup B) lost weight significantly. The weights of the rats in all groups differed significantly, according to the unpaired t-test. There was a substantial difference in body weight between groups 3 and 4 and other groups at the end of the trial (Fig. 1).

#### Tumor volume

There was no significant difference in tumor volumes between group 1A (-ve control) and (group 4) at the end of the study. However, there was a highly significant difference between groups 3 and 4 when compared to 1B (+ve control) and group 2 (Laser only) ( $P < 0.05$ ) (Fig. 2).



**Fig. 1.** Body weights were measured in different groups at the end of the experiment. There was a significant difference in body weight between all groups, positive control group, showed a significant loss in body weight, on the other hand, animals in all treatment groups gained weight, with the best result in PDT group.

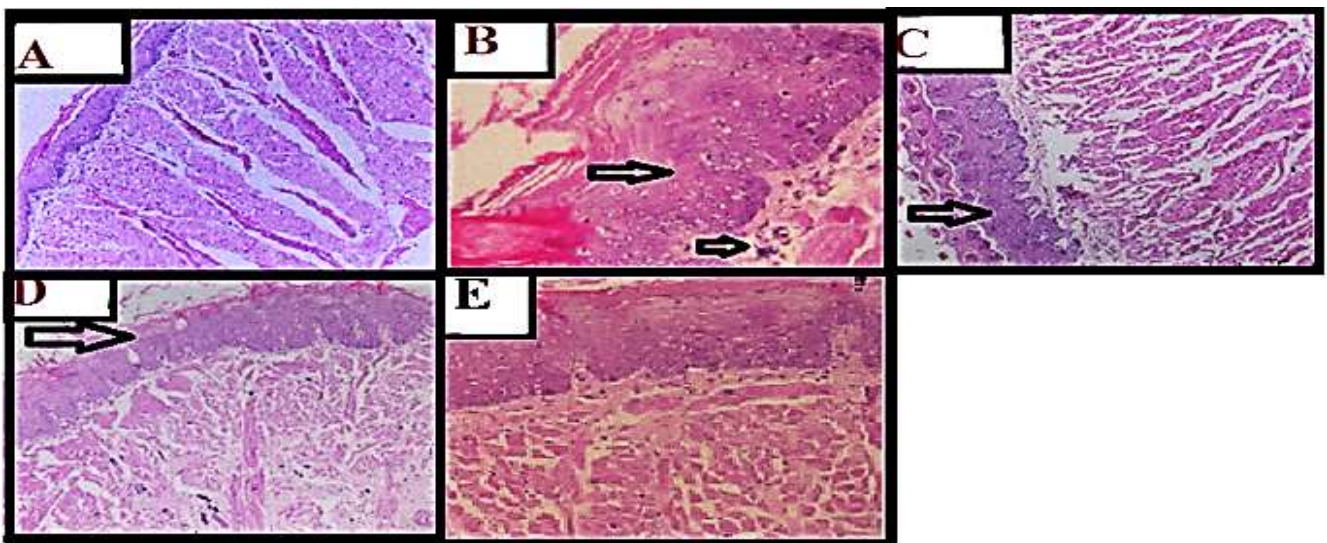


**Fig. 2.** Tumor volume in different groups. were measured in different groups at the end of the experiment. There was a significant difference in tumor size between all groups; positive control group, showed highest volume size and the least tumor size in PDT group.

**Histopathology observation**

The H & E-stained sections at the end of experiments were prepared and evaluated (Fig. 3). The mucosa in subgroup 1A (the negative control) had four regular different layers. While the subgroup 1B positive control (DMBA group) had well to moderately differentiated oral squamous cell carcinoma with various ulcers and significant papillomatous overgrowths, as well as several invading malignant epithelial islands into the connective tissue. The epithelium showed dysplasia, hyperplasia, and hyperkeratinization.

In group 2 (Laser group), partial loss of surface epithelium with various ulcers and dysplasia were seen. In group 3 (Nanocurcumin group), sub epithelial moderate congestion and inflammatory cell infiltration, as well as congestion and mononuclear infiltration were found. In Group 4 (PDT group), tongue that is typical (epidermis, muscle) smaller cells with nuclear disintegration, cytoplasm condensation, and well-defined cell boundaries were discovered to be apoptotic cells.



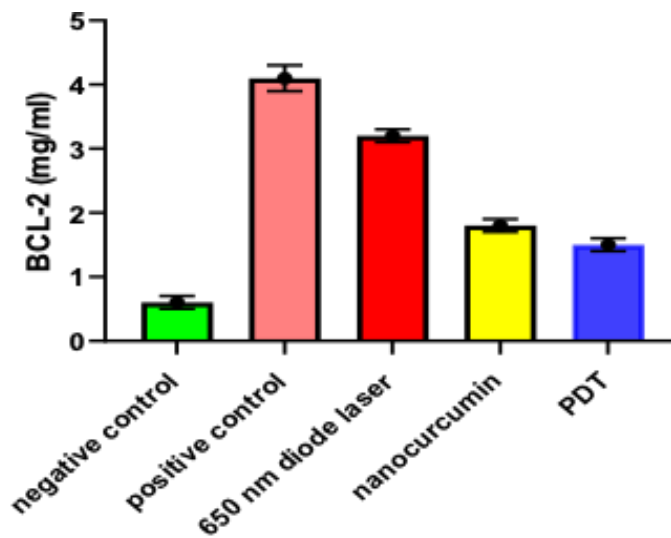
**Fig. 3.** Immunohistochemistry for hormonal receptors in female breast cancer patients A) Positive estrogen receptor (ER +Ve). B) Negative estrogen receptor (ER -Ve). C) Positive progesterone receptor (PR +Ve). D) Negative progesterone receptor (PR -Ve). E) Positive HER-2/neu (HER2 +Ve). F) Negative HER-2/neu (HER2 -Ve).

**Bcl-2 and Caspase-3 expressions**

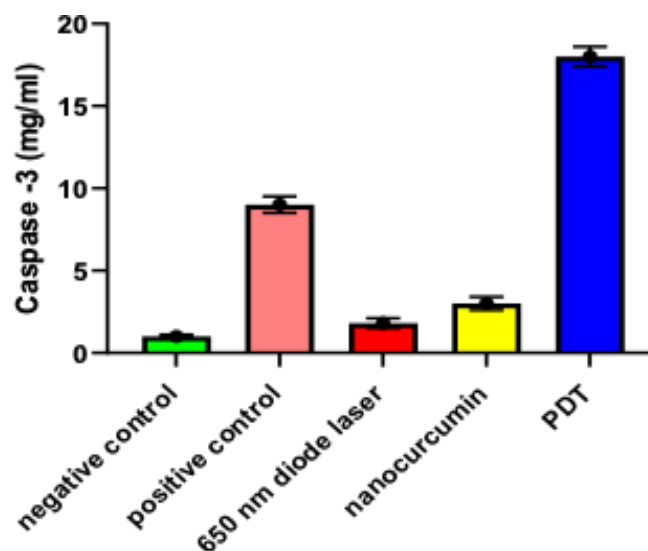
There were a significant decrease of Bcl-2 amounts in cancer tongue tissue treated with nanocurcumin ( $1.75 \pm 0.04$ ), cancer tongue tissue treated with diode laser ( $2.25 \pm 0.04$ ) groups compared to cancer group ( $2.5 + 0.28$ ). ( $P < 0.001$ ). There was a significant difference in Bcl-2 level in cancer tongue tissue treated with PDT and control group ( $P < 0.05$ ). A significant increase of Bcl-2 amounts in tongue tissue treated with PDT in comparison

with tongue tissue treated with low power diode laser and nanocurcumin (Fig. 4).

There were significant elevations of Caspase-3 in cancer tongue tissue treated with low power laser only, with nanocurcumin only, and with PDT compared to cancer group ( $P < 0.001$ ). Caspase-3 expression also showed significant elevation between tongue tissue treated with PDT in comparison with tongue tissue treated with nanocurcumin or low power diode laser ( $P < 0.05$ ) (Fig. 5).



**Fig. 4.** The levels of (Bcl-2) in different treated groups related to control. There was a significant difference in Bcl-2 level in cancer tongue tissue treated with PDT and control group.



**Fig. 5.** The levels of (Caspase3) in different treated groups related to control. There was a significant difference in Caspase 3 level in cancer tongue tissue treated with PDT and control group.

## Discussion

Oral squamous cell carcinomas are common, have a high rate of recurrence, and have a dismal five-year survival rate (29). Curcumin is a cancer-fighting substance. It has a reduced risk of side effects when compared to other medications. The goal of the current study was to examine nanocurcumin alone as well as photodynamic therapy with nanocurcumin on OSCC in rats. Due to the limited solubility, rapid degradation, and photochemical instability of free curcumin in clinical trials, a formulation capable of solubilizing and stabilizing the curcumin during treatment is required for photoactivity, which matched the present result (30).

Body weight, the animals in the control positive group that were not given any therapy showed a significant loss in body weight at the end of the experiment. Animals in all treatment groups, on the other hand, gained weight. The (PDT group) better than the Nanocurcumin alone group, showed significant reductions in tumor volumes, matching with the studies (22).

In terms of histology, various studies have advocated a step-by-step progression of mucosal lesions following DMBA delivery using the identical procedure used here. Throughout the establishment of OSCC in tongue tissues, every rat exposed to DMBA displayed symptoms of malignancy clinically and histopathologically. The tongue tissues epidermis and muscle in group 1B (control positive) showed marked malignant transformation, whereas group 4 (PDT) demonstrated improvement. The current research established a photodynamic treatment using combination of nanocurcumin and 200 mw of 650 nm diode laser light. The effects caused by PDT treatments were more potent than those induced by laser treatment alone throughout the treatment, which mirrored Buss et al 2013 findings. Previously, photodynamic therapy of malignant and non-cancerous cell lines, as well as a mouse xenograft tumor model, reduced cell growth and promoted apoptosis (31-32).

Nanocurcumin therapy, whether with or without PDT, resulted in liver function modulation. Curcumin has been shown to have potent antioxidant, anti-proliferative, and anti-inflammatory activities. Apoptosis-inducing factors have been studied in a wide range of cells. It's risk-free and well-tolerated. At higher doses, curcumin has been used to treat hyperproliferative diseases (33-34).

Immunohistochemistry examination (IHC) reveals the following: - Immunohistopathology of BCL2 B cell lymphoma2 (Bcl-2) is a protein that prevents cell death, allowing malignant cells to proliferate (35). Caspase cascades are associated to cancer progression and prognosis, as well as apoptosis. In cancer cells, caspase inactivation or low levels of expression are common, making them resistant to the microenvironment (36,37). Stresses and therapies that target Caspases expression in dying cells, on the other hand, may be damaging. Allow non apoptotic tumor cells to thrive and multiply by producing growth-stimulating signals. You live in a high-stress atmosphere. The role of apoptosis related Caspase in OSCC is unknown currently. The IHC and statistical analysis results are listed below. First, the expression of Caspase-3 in tumor tissues was substantially higher than in normal tissues. Second, in OSCC, high levels of cleaved Caspase-3 were linked to poor differentiation. Third, the presence of either positive cleaved Caspase-3 or increased Caspase-3 expression, or both, was linked to poor differentiation in OSCC, as well as moderately differentiated tumors and small tumor size (38,39).

Apoptosis induced proliferation is a process in which dead or surviving tumor cells produce a variety of mitogens, including as Ryo and Hedgehog, to encourage surrounding cells to expand (40). Caspases were shown to be over expressed in breast carcinomas, pancreatic ductal carcinomas, lung carcinomas, and oral carcinomas, among other cancer tissues (41).

Nutrient deficiency and hypoxia are common in tumors and aggressive tumor cells.

Caspases-3 activation is simpler under both dietary deficiency and hypoxia conditions, resulting in cancer cell death. Increased expression of cleaved Caspase-3 and Caspase-3 has been connected to a protracted invasion of OSCC with only large tumors, according to these data. Even though caspases may have non apoptotic functions in tumor genesis and poor prognosis, our data suggest that Caspase-3 can be employed as tumor genesis biomarkers in OSCC, with Caspase-3 values that matched our research values (38, 42-44).

Photodynamic therapy using a combination of nanocurcumin photosensitizer and 650 nm diode laser with suitable parameters has a significant influence in treatment of rat tongue oral squamous cell carcinoma through clinical, histological examination and gene expression of BCL2 and Caspase-3.

## References

1. Giovannacci I, Vescovi P, Manfredi M, Meleti M. Non-invasive visual tools for diagnosis of oral cancer and dysplasia: A systematic review. *Med Oral Patol Oral Cir Bucal*. 2016;21(3):e305-15.
2. Maleki D, Ghojzadeh M, Mahmoudi SS, Mahmoudi SM, Pournaghi-Azar F, Torab A, et al. Epidemiology of Oral Cancer in Iran: a Systematic Review. *Asian Pac J Cancer Prev*. 2015;16(13):5427-32.
3. Mascitti M, Orsini G, Tosco V, Monterubbianesi R, Balercia A, Putignano A, et al. An Overview on Current Non-invasive Diagnostic Devices in Oral Oncology. *Front Physiol*. 2018;9:1510.
4. Givony Sh. Oral squamous cell carcinoma (OSCC) an overview. *J Med Sci*. 2020;8(13):67-74.
5. El-Haddad, K., Metwaly, H. Evaluation of dose dependent effects of gamma radiation on rat tongue internal structures: histomorphometric and immunohistochemical study. *Egyptian Dental Journal*. 2018;64 (2):1315-1325.
6. Almangush A, Levio I, Mäkitie AA. Biomarkers for Immunotherapy of Oral Squamous Cell Carcinoma: Current Status and Challenges. *Front. Oncol*. 2021;11:1-5.
7. Carreras-Torras C, Gay-Escoda C. Techniques for early diagnosis of oral squamous cell

## Acknowledgements

Cairo University, Egypt is acknowledged.

## Funding

This research did not receive any specific grant from funding agencies in the public, commercial, or not-for-profit sectors.

## Conflicts of Interest

The authors declare that there are no conflicts of interest.

## Ethics approval

The research was approved by Cairo University's Institutional Animal Care and Use Committee, Cairo University, Egypt, with identification number code (CU-IACUC CU I F 21 18).

carcinoma: Systematic review. *Med Oral Patol Oral Cir Bucal*. 2015;20(3):e305-15.

8. Alhusaini A, Fadda L, Hasan IH, Zakaria E, Alenazi AM, Mahmoud AM. Curcumin Ameliorates Lead-Induced Hepatotoxicity by Suppressing Oxidative Stress and Inflammation, and Modulating Akt/GSK-3 $\beta$  Signaling Pathway. *Biomolecules*. 2019;9(11):703.

9. Bakhshi M, Gholami S, Mahboubi A, Jaafari MR, Namdari M. Combination Therapy with 1% Nanocurcumin Gel and 0.1% Triamcinolone Acetonide Mouth Rinse for Oral Lichen Planus: A Randomized Double-Blind Placebo Controlled Clinical Trial. *Dermatol Res Pract*. 2020;2020:4298193.

10. Zhang XD, Wu D, Shen X, Liu PX, Fan FY, Fan SJ. In vivo renal clearance, biodistribution, toxicity of gold nanoclusters. *Biomaterials*. 2012;33(18):4628-38.

11. Singh DV, Godbole MM, Misra K. A plausible explanation for enhanced bioavailability of P-gp substrates in presence of piperine: simulation for next generation of P-gp inhibitors. *J Mol Model*. 2013;19(1):227-38.

12. Schiborr C, Kocher A, Behnam D, Jandasek J, Toelstede S, Frank J. The oral bioavailability of curcumin from micronized powder and liquid micelles is significantly increased in healthy

humans and differs between sexes. *Mol Nutr Food Res*. 2014;58(3):516-27.

13. Buss S, Dobra J, Goerg K, Hoffmann S, Kippenberger S, Kaufmann R, et al. Visible light is a better co-inducer of apoptosis for curcumin-treated human melanoma cells than UVA. *PLoS One*. 2013;8(11):e79748.

14. Liew YCC, De Souza NNA, Sultana RG, Oh CC. Photodynamic therapy for the prevention and treatment of actinic keratosis/squamous cell carcinoma in solid organ transplant recipients: a systematic review and meta-analysis. *J Eur Acad Dermatol Venereol*. 2020;34(2):251-259.

15. Lin J, Ni G, Ding T, Lei S, Zhong L, Liu N, et al. Photodynamic Therapy for Oral Squamous Cell Carcinoma: A Systematic Review and Meta-Analysis. *Int J of Photoenerg*. 2021;6641358:1-14.

16. Hamblin MR. Mechanisms and applications of the anti-inflammatory effects of photobiomodulation. *AIMS Biophys*. 2017;4(3):337-361.

17. The Lancet (EDITORIAL). Stem cells, regenerative medicine, Prometheus. Editorial. *Lancet*. 2018;391(10123):814.

18. de Pauli Paglioni M, Faria KM, Palmier NR, Prado-Ribeiro AC, E Dias RB, da Graça Pinto H, et al. Patterns of oral mucositis in advanced oral squamous cell carcinoma patients managed with prophylactic photobiomodulation therapy-insights for future protocol development. *Lasers Med Sci*. 2021;36(2):429-436.

19. Chen X, Duan N, Zhang C, Zhang W. Survivin and Tumorigenesis: Molecular Mechanisms and Therapeutic Strategies. *J Cancer*. 2016;7(3):314-23.

20. Ailioaie LM, Litscher G. Curcumin and Photobiomodulation in Chronic Viral Hepatitis and Hepatocellular Carcinoma. *Int J Mol Sci*. 2020;21(19):7150.

21. Beyer K, Nikfarjam F, Butting M, Meissner M, König A, Ramirez Bosca A, et al. Photodynamic Treatment of Oral Squamous Cell Carcinoma Cells with Low Curcumin Concentrations. *J Cancer*. 2017;8(7):1271-1283.

22. Zhang C, Li B, Zhang X, Hazarika P, Aggarwal BB, Duvic M. Curcumin selectively induces apoptosis in cutaneous T-cell lymphoma cell lines and patients' PBMCs: potential role for

STAT-3 and NF-kappaB signaling. *J Invest Dermatol*. 2010;130(8):2110-9.

23. Faustino-Rocha A, Oliveira PA, Pinho-Oliveira J, Teixeira-Guedes C, Soares-Maia R, da Costa RG, et al. Estimation of rat mammary tumor volume using caliper and ultrasonography measurements. *Lab Anim (NY)*. 2013;42(6):217-24.

24. Juneja S, Chaitanya NB, Agarwal M. Immunohistochemical expression of Bcl-2 in oral epithelial dysplasia and oral squamous cell carcinoma. *Indian J Cancer*. 2015;52(4):505-10.

25. Latteri S, Catania VE, Malaguarnera G, Peri A, Bertino G, Frazzetto G, et al. Carcino embryonic Antigen Serum Levels in Nonmelanoma Skin Cancer. *Biomedicines*. 2018;6(24):1-11.

26. Ramezani M, Mohamadzaheeri E, Khazaei S, Najafi F, Vaisi-Raygani A, Rahbar M, Sadeghi M. Comparison of EMA, CEA, CD10 and Bcl-2 Biomarkers by Immunohistochemistry in Squamous Cell Carcinoma and Basal Cell Carcinoma of the Skin. *Asian Pac J Cancer Prev*. 2016;17(3):1379-83.

27. Scuderi SA, Casili G, Basilotta R, Lanza M, Filippone A, Raciti G, et al. NLRP3 Inflammasome Inhibitor BAY-117082 Reduces Oral Squamous Cell Carcinoma Progression. *Int J Mol Sci*. 2021;22(20):11108.

28. Wang J, Zhang X, Wei P, Zhang J, Niu Y, Kang N, et al. Livin, Survivin and Caspase 3 as early recurrence markers in non-muscle-invasive bladder cancer. *World J Urol*. 2014;32(6):1477-84.

29. Kangboonruang K, Wongtrakoongate P, Lertsuwan K, Khachonkham S, Changkaew P, Tangboonduangjit P, et al. MALAT1 Decreases the Sensitivity of Head and Neck Squamous Cell Carcinoma Cells to Radiation and Cisplatin Anticancer Res. 2020;40(5):2645-55.

30. Ahn J, Kang J, Shin J, Chung P. Combination treatment with photodynamic therapy and curcumin induces mitochondria-dependent apoptosis in AMC-HN3 cells. *Int J of Oncology*. 2012;41(6):2184-2190.

31. Chen CH, Huang YC, Lee YH, Tan ZL, Tsai CJ, Chuang YC, et al. Anticancer Efficacy and Mechanism of Amentoflavone for Sensitizing

Oral Squamous Cell Carcinoma to Cisplatin. *Anticancer Res.* 2020;40(12):6723-6732.

32. Prasad S, Tyagi AK, Aggarwal BB. Recent developments in delivery, bioavailability, absorption and metabolism of curcumin: the golden pigment from golden spice. *Cancer Res Treat.* 2014;46(1):2-18.

33. Liu T, Long T, Li H. Curcumin suppresses the proliferation of oral squamous cell carcinoma through a specificity protein 1/nuclear factor- $\kappa$ B-dependent pathway. *Exp Ther Med.* 2021;21(3):202.

34. Ludwig LM, Nassin ML, Hadji A, LaBelle JL. Killing Two Cells with One Stone: Pharmacologic BCL-2 Family Targeting for Cancer Cell Death and Immune Modulation. *Front Pediatr.* 2016;4:135.

35. Jakubowska K, Guzińska-Ustymowicz K, Famulski W, Cepowicz D, Jagodzińska D, Pryczynicz A. Reduced expression of caspase-8 and cleaved caspase-3 in pancreatic ductal adenocarcinoma cells. *Oncol Lett.* 2016;11(3):1879-1884.

36. Noble P, Vyas M, Al-Attar A, Durrant S, Scholefield J, Durrant L. High levels of cleaved caspase-3 in colorectal tumour stroma predict good survival. *Br J Cancer.* 2013;108(10):2097-105.

37. Coutinho-Camillo CM, Lourenço SV, Nishimoto IN, Kowalski LP, Soares FA. Caspase expression in oral squamous cell carcinoma. *Head Neck.* 2011;33(8):1191-8.

38. Huang Q, Li F, Liu X, Li W, Shi W, Liu FF, et al. Caspase 3- mediated stimulation of tumor cell repopulation during cancer radiotherapy. *Nat Med.* 2011;17(7):860-6.

39. Ryoo HD, Bergmann A. The role of apoptosis-induced proliferation for regeneration and cancer. *Cold Spring Harb Perspect Biol.* 2012;4(8):a008797.

40. Hassan M, Watari H, AbuAlmaaty A, Ohba Y, Sakuragi N. Apoptosis and molecular targeting therapy in cancer. *Biomed Res Int.* 2014;2014:150845.

41. Li S, Zhang HY, Wang T, Meng X, Zong ZH, Kong DH, et al. BAG3 promoted starvation-induced apoptosis of thyroid cancer cells via attenuation of autophagy. *J Clin Endocrinol Metab.* 2014;99(11):E2298-307.

42. Mohamed Abdelgawad L, Abd El-Hamed MM, Sabry D, Abdelgawad M. Efficacy of Photobiomodulation and Metformin on Diabetic Cell Line of Human Periodontal Ligament Stem Cells through *Keap1/Nrf2/Ho-1* Pathway. *Rep Biochem Mol Biol.* 2021;10(1):30-40.

43. Shahabinejad M, Zare R, Asadi Z, Mohajertehran F. LAMP3 (CD208) Expression in Squamous Cell Carcinoma and Epithelial Dysplasia of the Oral Cavity and Clinicopathological Characteristics of Unfavorable Prognosis. *Rep Biochem Mol Biol.* 2021;9(4):373-378.

44. Abdelgawad M, Sabry D, Mohamed Abdelgawad L, Mohamed Elroby Ali D. *In Vitro* Differential Sensitivity of Head and Neck Squamous Cell Carcinoma to Cisplatin, Silver Nanoparticles, and Photodynamic Therapy. *Rep Biochem Mol Biol.* 2022;11(2):224-237.