

Hydroalcoholic Sumac Extract as a Protective Agent Against X-Ray-Induced Pulmonary Fibrosis

Faezeh Rezaie¹, Aboufazel Ghafouri Khosroshahi¹, Amir Larki-Harchegani¹,
Alireza Nourian², Hossein Khosravi*³

Abstract

Background: X-ray exposure can result in acute or chronic damage to lung tissue, leading to pneumonitis and fibrosis. Given the potent antioxidant properties of sumac, this study investigates the impact of hydroalcoholic sumac extract on X-ray-induced pulmonary fibrosis in rats.

Methods: In this experimental study, 36 rats were randomly divided into six groups of six rats each. The treatment and sham groups received intraperitoneal administration of the extract daily for one week before exposure to X-ray radiation. On the seventh day, all rats except those in group 3 were exposed to 2 Gy of 6 MV X-rays using an electro-linear accelerator. Lung tissue was subsequently removed to assess the subacute effects of the extract. Data analysis involved independent sample t-tests and one-way ANOVA using SPSS 26.

Results: A single dose of X-rays significantly increased oxidative stress and lung tissue damage in rats. However, rats receiving vitamin C and hydroalcoholic sumac extract at two different doses (100 and 400 mg/kg intraperitoneally) positively improved lung damage and decreased antioxidant parameters.

Conclusion: The findings demonstrate that hydroalcoholic sumac extract can mitigate oxidative stress and enhance lung repair following X-ray radiation exposure.

Keywords: Antioxidant, CT X-Ray, Pulmonary Fibrosis, Radiation protective agents.

Introduction

Idiopathic pulmonary fibrosis (IPF) is the most common type of idiopathic interstitial pneumonia, characterized by progressive dyspnea, loss of lung function, and a deteriorating quality of life. It is more prevalent in men and less common in individuals under 50 years.

The etiology of IPF is not clear, but research suggests that oxidative-nitrosative stress plays a significant role in producing reactive oxygen and nitrogen species, leading to cellular damage. Inadequate antioxidant defenses exacerbate this stress. Due to its exposure to relatively higher oxygen tensions compared to other tissues, the lung is

susceptible to oxidative stress. Exogenous oxidants and pollutants can further increase oxidant generation and activate inflammatory cells, producing free radicals. Factors such as smoking, drug exposure, and radiation contribute to fibrotic interstitial lung reactions and trigger the generation of reactive oxygen species (ROS).

The high penetrating power of γ -rays and X-rays has been approved due to low linear energy transfer (LET). Exposure to X-rays can lead to the production of free radicals through the radiolysis process. When these free radicals collide with biological molecules, they may cause cellular lipid peroxidation and DNA

1: Department of Medicinal Chemistry, School of Pharmacy, Hamadan University of Medical Sciences, Hamadan, Iran.

2: Department of Pathobiology, School of Veterinary Science, Bu-Ali Sina University, Hamadan, Iran.

3: Department of Radiology, School of Allied Medical Sciences, Hamadan University of Medical Sciences, Hamadan, Iran.

*Corresponding author: Hossein Khosravi; Tel: +98 81 38380499; E-mail: h.khosravi@umsha.ac.ir.

Received: 9 Apr, 2024; Accepted: 23 Jun, 2024

damage (5). The lung is a susceptible organ to radiation. Radiation can cause acute or chronic lung damage, depending on the dose, duration, and pre-existing lung disease (6). Acute radiation damage usually occurs between two weeks and three months after treatment, and this damage is usually limited to the irradiated area. Mild injury often resolves without treatment, while more severe injury 6 to 12 months later leads to fibrosis. The main side effects of radiation therapy on the lungs are pneumonitis and fibrosis. Fibrotic changes in the lung result from interactions between different types of cells that involve the production of inflammatory and fibrotic cytokines by cells such as macrophages and fibroblasts. Increased expression of pro-inflammatory and pro-fibrotic cytokines plays a crucial role in fibrosis (7). Inflammation begins as a mechanism to protect and repair damage to natural tissue caused by radiation. When the balance between prophylactic and anti-inflammatory processes is disturbed, the state of chronic inflammation can lead to further tissue damage. Both pneumonitis and fibrosis can significantly affect patients' quality of life (8).

Given the fundamental role of oxidative stress in developing IPF, antioxidant therapy is an attractive and rational treatment approach. Natural antioxidants have more advantages and fewer side effects than synthetic ones (9).

Sumac (*Rhus coriaria* L.) is a dicotyledonous flowering plant of the genus *Rhus* that belongs to the Anacardiaceae family. Sumac is a commonly used spice, condiment, and flavoring agent employed in traditional medicine to treat hemorrhoids, diarrhea, wound healing, eye inflammation, and ulcers. It contains several chemical compounds with intense antioxidant activity, such as anthocyanins, tannins, and flavonoids. Recent epidemiological studies strongly suggest consuming some plants containing these substances to reduce the risk of chronic diseases due to oxidative distress. The antioxidant activity of sumac is significant, with the highest activity at a concentration of 250 mg/kg (10,11). Recent studies have shown that the aqueous methanolic extract of sumac fruit has a

high antioxidant capacity. In addition, the protective role of *Rhus coriaria* L. extract against UV-A damage has been reported (12).

Due to the potent antioxidant activity of sumac and the importance of management of IPF considering its poor survival and increasing trend, in this study, we assessed the effect of hydroalcoholic extract of sumac on pulmonary fibrosis induced by X-ray in rats.

Materials and Methods

This experimental study was conducted on 36 rats (180-200 g) prepared from the animal house of the Hamedan University of Medical Sciences in 2021. Animals were kept in the animal room for one week to adapt to the new environment at a temperature of 22 ± 1 °C under a 12/12-hour dark light and randomly assigned to six groups (n=6 per group, three animals for acute test and three animals for subacute test) as follows:

- 1) Negative control group: This group received no radiation and medicine.
- 2) Positive control group: This group received only X-ray.
- 3) Treatment group: This group received intraperitoneal injection of vitamin C.
- 4) Sham group: This group received only sumac extract at 400 mg/kg.
- 5) Treatment group: This group was subjected to X-ray, followed by the administration of the hydroalcoholic extract of sumac at 100 mg/kg.
- 6) Treatment group: This group was subjected to X-ray, followed by the administration of the hydroalcoholic extract of sumac at 400 mg/kg.

Rats in the treatment and sham groups received the extract intraperitoneally every day for one week before receiving X-ray radiation. On the seventh day, all rats except group 3 and 1 were taken to Mahdiah Imaging Center, Hamedan, anesthetized with ketamine, and exposed to 2 Gy from 6 MV X-rays by an electro-linear accelerator (Elekta, Sweden). The rats were returned to the laboratory, and three rats from each group were sacrificed using ketamine/xylazine. Their lung tissue was removed to evaluate the acute effects of X-rays. The rest of the rats received the recommended extract dose daily for another two weeks. They

were then sacrificed using ketamine/xylazine, and their lung tissue was removed to assess the subacute effects of the extract. Part of the tissues was kept in formalin for histology examination and other parts were stored in the freezer at -80 °C.

Measurement of lipid peroxidation (LPO), total antioxidant capacity (TAC), superoxide dismutase (SOD) activity, myeloperoxidase activity, glutathione peroxidase (GPx) activity, nitric oxide (NO) levels, and hydroxyproline levels were performed using kits provided by the Kiazist Company, Iran, and histological examination of lung tissue.

Measurement of superoxide dismutase activity

To assess SOD activity, 20 mg of tissue was lysed by homogenizer in Phosphate-buffered saline (PBS) inside an ice bucket and then centrifuged at 16,128 RCF at 4 °C for 15 minutes. The supernatant was frozen in a new tube at -80 °C for analysis. To measure of SOD collected samples, the kit's solutions were warmed to the room temperature. In plate wells, first, 20 µl of the sample was poured, then 100 µl of SOD assay reagent, and after adding Xanthine oxidase (XO) working solution, the plate was gently shaken to mix the materials inside the wells, followed by incubation at 37 °C for 37 minutes. Finally, the absorbance was read at 570 nm with an ELISA reader (Biotek, USA). The activity was expressed as the inhibition rate percentage.

Measurement of glutathione peroxidase activity

Twenty milligrams of lung tissue were lysed using a homogenizer in phosphate-buffered saline (PBS) while kept on ice. The lysate was then centrifuged at 16,128 RCF for 15 minutes at 4 °C. Then, 50 µl of the sample was poured into the wells of the plate, and then 37 µl of Gpx Buffer 1x was added, followed by pouring 10 µl of Enzyme working solution into the plates and finally adding 3 µl of Co-substrate solution, mixing the plate well to mix the ingredients. It was then incubated at room temperature and dark for 15 minutes. Then, 10 µl of H₂O₂ working solution was poured into all wells and mixed well to start the reaction immediately.

The adsorption was then read immediately at 340 nm for 5 minutes and every minute in kinetic mode with ELISA reader Biotek. The enzyme activity was considered as Mu/ml.

Measurement of total antioxidant capacity

Twenty milligrams of lung tissue was lysed using a homogenizer in phosphate-buffered saline (PBS) and then centrifuged at 16,128 RCF for 15 minutes at 4 °C. First, 30 µl of the sample was poured into each well. Then, PBS Buffer was used as a blank and 30 µl of this solution was added to the blank well. Afterward, 150 µl of TAC solution was added to each well and the plate was incubated at room temperature for 30-60 minutes. Finally, the plate absorbance was read at a wavelength of 450 nm.

Measurement of MDA lipid peroxidation

Twenty milligrams of lung tissue was washed with phosphate-buffered saline (PBS) buffer. Then, 300 µl of Malondialdehyde (MDA) Lysis buffer was combined with 3 µl of Butylated hydroxytoluene (BHT) 100X and the sample was homogenized on ice (Kiazist Company, Iran). The resulting homogeneity was centrifuged at 6,000 G for 10 minutes. Then, 200 µl of the sample or blank and standard was added to each microtube, followed by 600 µl of TBA solution. The microtube lids were tightly closed with parafilm and incubated at 95 °C for 60 minutes. They were cooled at room temperature for 10 minutes. Then, 200 µl of the sample or standard supernatant was transferred to a 96-well plate, and its absorbance was read at 532 to 560 nm.

Measurement of myeloperoxidase activity

Twenty milligrams of lung tissue was lysed using a homogenizer in 1x Myeloperoxidase (MPO) buffer, kept in an ice bucket, and then centrifuged at 16,128 RCF for 15 minutes at 4 °C. Then, 40 µl of sample or sample control was added to each well. Afterward, 50 µl of reagent mix one was added to the sample wells, followed by incubation at room temperature for 120 minutes. Then, 10 µl of stop reagent working solution was added to all wells except

the standard and incubated at room temperature for 10 minutes. In the next step, 30 µl of reagent mix2 was added to all samples and their controls and incubated at room temperature for 10 minutes. In the end, we read the absorption at 405 nm.

Measurement of hydroxyproline

After transferring 20 mg of tissue to a clean microtube was homogenized in 100 µl of deionized water. Then, 100 µl of HCL (12 M) was added and incubated at 120 °C for 4 hours. First, we added 20 µl of sample or standard to each well. The assay buffer was used as a blank. Then, 20 µl of this solution was added to the blank wells. Then, 100 µl of oxidation solution was added to each well and incubated at room temperature for 15 minutes. Afterward, 100 µl of chromogen solution was added to the well and baked at 60 °C until a purple-orange color appeared. The absorption was read at 560 nm.

Measurement of nitric oxide

After homogenizing 20 mg of tissue in the NO buffer with a homogenizer, it was centrifuged at 16,128 RCF for 15 minutes at 4 °C. Then, 100 µl of the sample was mixed with 120 µl of the prepared MasterMix and then incubated at room temperature until the wells' color changed from light pink to purple. At the end of the incubation, we read the sample absorption at 545 nm with ELISA reader Biotek.

Histopathology procedure

About a quarter of the posterior part of the right lip of each rat's lung was placed in a 10% Formalin buffer solution. After stabilization for at least 24 hours, tissue processing was performed, including dehydration steps using ascending ethanol concentrations, xylene clarification, and paraffin impregnation. After molding, the blocks were cut with a microtome and the tissue sections (5-6 µm) were stained with hematoxylin and eosin (H&E), and Masson's trichrome. The slides prepared by the pathologist were examined and analyzed using light microscopy (CX41, Olympus, Japan) equipped with a digital camera (DP25, Olympus, Japan).

Statistical analysis

In this study, sample analysis in each test was performed in duplicate and the result was reported as Mean ± SD. The independent sample t-test was used to compare two different groups and more than two groups. The one-way analysis of variance (ANOVA) and Tukey's post hoc test were used to compare more than two groups using SPSS 26 at a significance level of 0.05.

Results

Effect of the sumac extract on Myeloperoxidase levels in the lung tissue

There was no statistically significant difference in the acute group compared to the positive control group in myeloperoxidase (MPO) levels. Also, there was a statistically significant difference between the Sham, treatment with a dose of 400 mg/kg, treatment with a dose of 100 mg/kg, and treatment with vitamin C compared to the negative control group in the acute group ($P < 0.05$).

The antioxidant content of the group receiving 400 mg/kg of sumac extract was equal to that of the group receiving vitamin C. However, these two groups' antioxidant content was higher than those receiving 100 mg/kg of sumac hydroalcoholic extract.

There was no statistically significant difference in the subacute group compared to the positive control group in MPO levels. There was a statistically significant difference in the vitamin C group compared to the negative control in the subacute group ($P < 0.05$). There was a statistically significant difference between the treatment with a dose of 100 mg/kg between acute and subacute groups ($P < 0.05$).

Effect of the sumac extract on MDA levels in the lung tissue

There was not statistically significant in MDA levels in the acute group compared to the positive control group. A statistically significant difference was found in the vitamin C group compared to the negative control group ($P < 0.05$).

There was no statistically significant difference in MDA levels between the subacute

and positive control groups. No statistically significant difference was found between the studied groups and the negative control group in the subacute group. There was no statistically significant difference between the studied acute and subacute groups.

Effect of the sumac extract on SOD levels in the lung tissue

There was no statistically significant difference between the studied groups and the positive control in the acute group regarding SOD levels.

A statistically significant difference was found in the acute group compared to the negative control group ($P < 0.05$). The group receiving sumac extract at 400 mg/kg showed better antioxidant effects. Also, there was no statistically significant difference between the studied and the positive control groups in the subacute groups.

There was a statistically significant difference between the Sham, treatment at a dose of 400 mg/kg, treatment at 100 mg/kg, and vitamin C compared with the negative control in the subacute group ($P < 0.001$). Also, there was no statistically significant difference between the acute and subacute groups.

Effect of the sumac extract on NO levels in the lung tissue

There was a statistically significant difference in the acute group compared to the positive control group ($P < 0.05$). A statistically significant difference was found in the acute group compared to the negative control group ($P < 0.05$).

In the sham group (receiving sumac extract at 400 mg/kg), NO levels were lower than in healthy rats receiving neither medication nor radiation, indicating this extract's antioxidant effects in healthy rats. Also, in the subacute group, there was a statistically significant difference between the group receiving the extract at 100 and 400 mg/kg compared to the group receiving only radiation (positive control) ($P < 0.05$). According to the level of antioxidants in the groups receiving sumac hydroalcoholic extract compared to the group

receiving radiation, the extract could reduce the amount of NO in these rats. In the subacute group, there was a statistically significant difference between the Sham, treatment at 400 mg/kg, treatment at 100 mg/kg, and vitamin C groups compared to the negative control group ($P < 0.001$). No statistically significant difference was found between the acute and subacute groups.

Effect of the sumac extract on hydroxyproline levels in the lung tissue

In the acute group, there was a statistically significant difference between the extract group (400 mg/kg) and the vitamin C group compared to the positive control group ($P < 0.05$). Also, in the acute group, there was a statistically significant difference between the treatment at 400 mg/kg, treatment at 100 mg/kg, and vitamin C groups compared to the negative control group ($P < 0.05$). Also, the rate of reduction in hydroxyproline in the group receiving hydroalcoholic sumac extracts was more significant than in the vitamin C group ($P < 0.05$). A statistically significant difference was found in the subacute group compared to the positive control group ($P < 0.05$). The groups receiving vitamin C and the dose of 100 mg/kg of hydroalcoholic extract of sumac showed better antioxidant effects within 14 days of continuing the injection. In the acute and subacute groups, there was also a statistically significant difference between the treatment group at a dose of 400 mg/kg compared to the negative control group ($P < 0.05$). In addition, there was a statistically significant difference between sham, treatment at a dose of 400, and vitamin C groups in the acute and subacute groups.

Effect of the sumac extract on GPx levels in the lung tissue

There was no statistically significant difference between the studied groups and the positive control group regarding GPx levels in the acute group. Also, there was no statistically significant difference between the studied and the acute group's negative control groups.

In the subacute group, no statistically significant difference was found between the

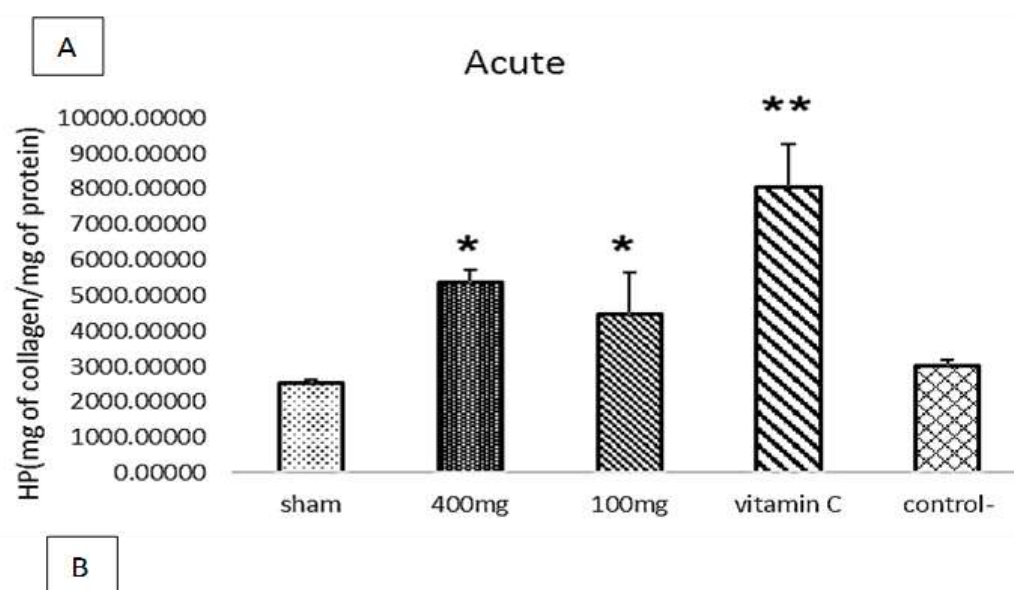
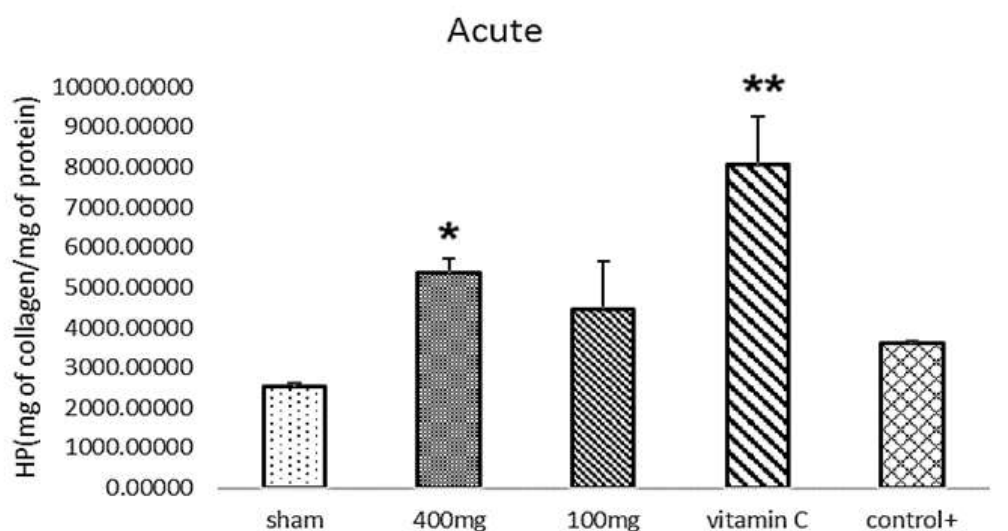
studied groups and the positive control. There was also no statistically significant difference between the studied and negative control groups. In addition, there was no statistically significant difference between the studied acute and subacute groups.

Effect of the sumac extract on TAC levels in the lung tissue

In the acute group, there was no statistically significant difference between the studied groups compared to the positive control group in TAC levels. Also, in the acute group, a statistically significant difference was found between the sham treatment at 400 mg/kg, treatment at 100 mg/kg, and vitamin C groups

compared to the negative control group ($P < 0.001$). The groups receiving vitamin C and hydroalcoholic extract of sumac showed increased TAC levels (Fig. 1).

In the subacute group, there was a statistically significant difference between the sham and positive control groups ($P < 0.05$). Also, in the subacute group, there is a statistically significant difference between the sham, treatment at 400 mg/kg, treatment at 100 mg/kg, and vitamin C groups compared to the negative control group ($P < 0.001$). There was no statistically significant difference between the studied acute and subacute groups (Figs. 2 & 3).



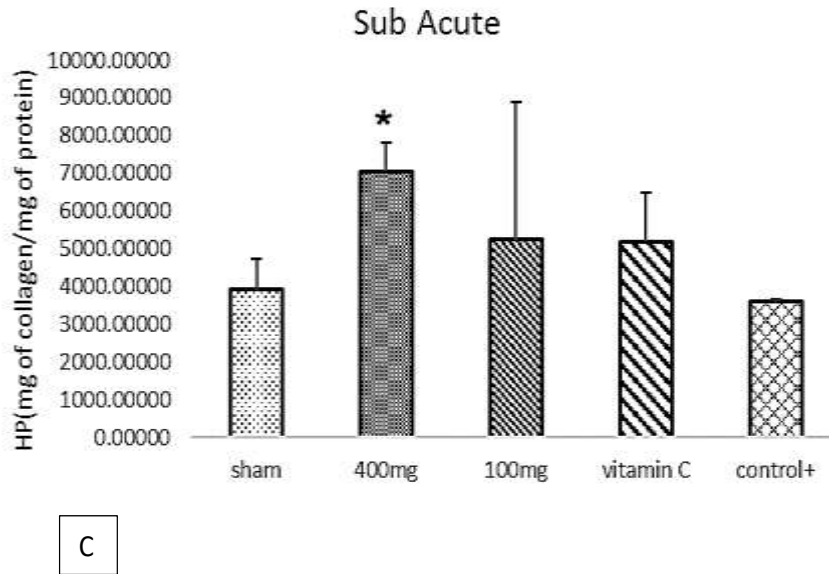


Fig. 1. Effect of hydroalcoholic extract of sumac and vitamin C on HP levels in lung tissue of acute and sub-acute groups ($P < 0.05$) versus control ($P < 0.001$) versus controls (A: Acute with control+, B: Acute with control- and C: Sub Acute with control+).

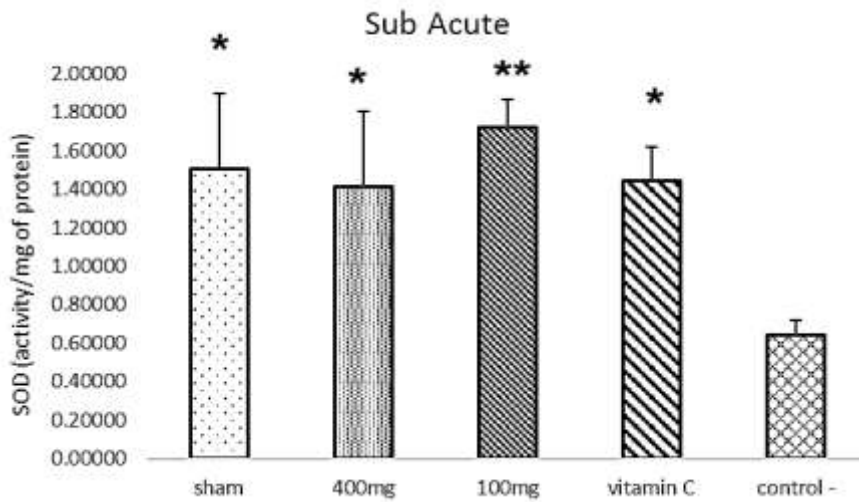


Fig. 2. Effect of hydroalcoholic extract of sumac and vitamin C on SOD levels in lung tissue of sub-acute groups. * ($P < 0.05$) versus control-, ** ($P < 0.001$) versus controls.

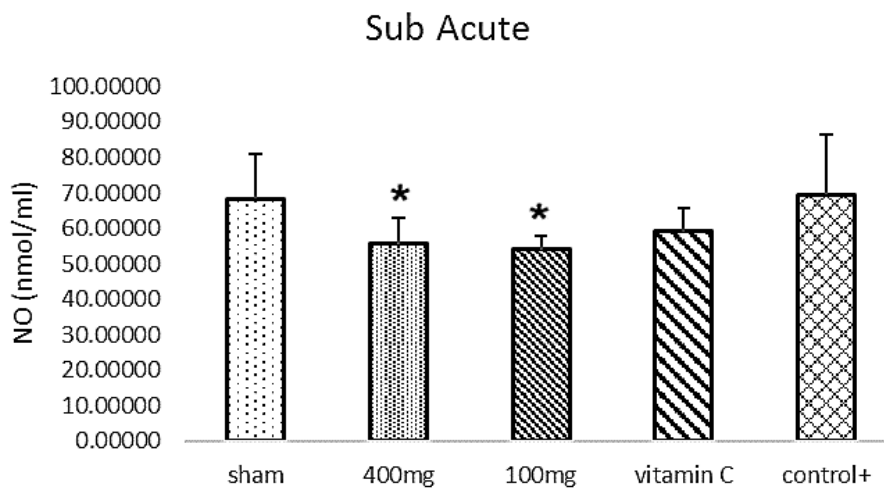


Fig. 3. Effect of hydroalcoholic extract of sumac and vitamin C on NO levels in lung tissue of sub-acute groups ($P < 0.05$) versus control+ ** ($P < 0.001$) versus controls.

Lung histology results

A tissue cross-section was selected for each group, and five fields were studied using $\times 100$ microscope magnification. The morphological criterion of Ashcroft (1988) was used to grade

the microscopic status of lung tissue (13). Sampling was done on two days at intervals of two weeks, and Masson's trichrome staining was done. The results of this section are shown in Fig. 4.

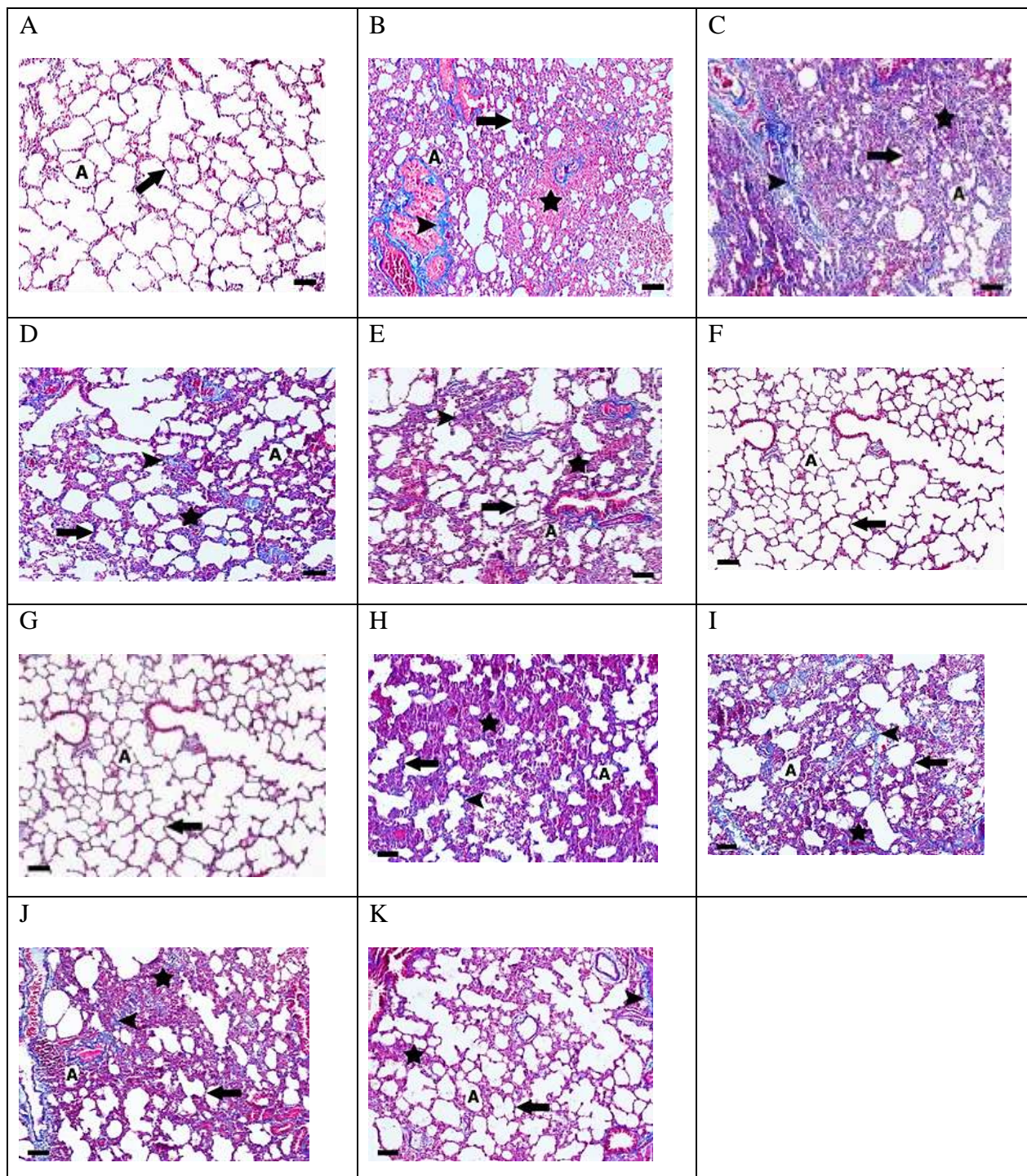


Fig. 4. Masson's trichrome staining of lung tissue, Bubble (A), bubble wall (arrow), fibrous areas (star), collagen fibers (arrow tip). Magnification = $\times 100$, scale bar = μm 100, A) the negative control group: The walls of the bubbles were thin, and the bubble space was ample and natural (grade 1-0); B) the positive control group (acute group): lung tissue showed pathological changes, including the formation of large areas of fibrosis due to inflammation and increased interstitial connective tissue volume and collagen accumulation. The wall thickness of the bubbles increased, and the bubble space decreased (grade 6); C) the positive control group (subacute group): On the 14th day, pathological changes, including the

formation of large areas of fibrosis due to inflammation and an increase in the volume of interstitial connective tissue and collagen accumulation have become more extensive and severe (grade 7); D) the vitamin C group (acute group): On the first day, pathological changes and tissue damage were significantly eliminated (compared to other treatment groups). The bubble space increased and the bubble wall diameter, as well as the amount of fibrous connective tissue, decreased (grade 2-3); E) the vitamin C group (subacute group). On the 14th day, pathological changes and lung tissue damage were resolved over time (grade 2); F) the sham group (acute group): On the first day, the microscopic structure of lung tissue was normal. The walls of the bubbles were thin, and the bubble space was large and natural (grade 1-0); G) the sham group (subacute group): On the 14th day, the microscopic structure of lung tissue was normal. The walls of the bubbles were thin and the bubble space was ample and average (grade 1-0); H) the sumac extract group (100 mg/kg) (acute group) On the first day, lung damage reduced to a limited extent (grade 5); I) the sumac extract group (100 mg/kg) (Subacute group): On the 14th day, lung damage reduced to a limited extent (grade 5); J) the sumac extract group (400 mg/kg) (acute group): On the first day, lung damage, tissue inflammation, area of fibrosis, and bubble wall thickness significantly reduced (grade 4); K) the sumac extract group (400 mg/kg) (Subacute group): On the 14th day, lung damage, tissue inflammation, area of fibrosis, and bubble wall thickness slightly decreased compared to two weeks ago (grade 3-4).

Discussion

Idiopathic pulmonary fibrosis (IPF) is a deadly and progressively worsening lung disease, with patients typically surviving less than three years after diagnosis. It is marked by fibrosis of the alveolar walls, excessive scar tissue, and destruction of the lung parenchyma, which lead to severe respiratory issues and abnormal gas exchange. While the exact cause of IPF is unknown, research suggests that oxidative-nitrosative stress and the resulting production of reactive oxygen species (ROS) and reactive nitrogen species (RNS) play a significant role in causing cellular damage. These factors may contribute to the disease by inducing epithelial-mesenchymal transition (EMT). High levels of oxidative stress can damage proteins, lipids, carbohydrates, and nuclei, accelerating disease progression. In addition to increased oxidative damage markers in IPF patients, such as exhaled ethane, NO, MDA, and urinary isoprostane levels, oxidative stress impacts lung homeostasis, hindering regeneration and repair processes (14-16).

While two FDA-approved drugs, pirfenidone and nintedanib, are available for treating idiopathic pulmonary fibrosis (IPF), they only moderately slow lung function decline and extend survival by about six months. These drugs are not universally effective and often come with significant and sometimes intolerable side effects. No current drug treatment can significantly improve the quality of life for IPF patients or reverse fibrosis. There is a pressing need for new

therapy options that provide health benefits by targeting the critical oxidant-related pro- and antifibrotic pathways rather than just acting as antioxidants. Non-pharmacological compounds with known mechanisms could be promising candidates for such treatments (17-18).

In this study, vitamin C and sumac extract were used due to their antioxidant properties. Antioxidant supplements help bolster the lung's antioxidant defense, reduce oxidative stress, and act as anti-inflammatory agents. Over the past 50 years, antioxidants have been shown to mitigate cellular damage caused by ionizing radiation in animal models. Nutrients like selenium compounds and vitamin E can protect against radiation effects. Ascorbic acid, a potent antioxidant, scavenges oxygen and nitrogen oxide species (19-21). Research has explored the use of drugs and supplements with anti-inflammatory and antioxidant effects as additional therapies for pulmonary fibrosis and lung tissue damage caused by X-rays. One study observed that oxidative stress indicators did not significantly increase one day after irradiation in four groups of mice, but a notable increase was seen two weeks later. It was also found that SOD activity and GSH levels were significantly higher in the irradiated groups. Another study examined the radioprotective effects of watermelon on oxidative damage in mice exposed to low-dose X-rays. The results showed that watermelon juice significantly reduced MDA levels and enhanced intracellular antioxidant

activities, including SOD inhibition activities and GSH levels. Notably, SOD activity in the lung tissue significantly increased in the treated group compared to the irradiated group. However, no significant increase in GSH levels was observed in the lung, though increases were noted in brain and liver tissues (24,27).

Several studies have shown that sumac extract possesses significant anti-inflammatory and antioxidant properties, useful for treating various inflammatory diseases. For instance, research by Kosar et al. found that sumac extracts and fractions exhibit strong radical inhibitory activity, with the highest phenolic content showing the greatest free radical scavenging effects. Sumac has also been shown to effectively inhibit lipid peroxidation. Alsamri et al. suggested that sumac's protective effects are due to its ability to increase the activity of detoxifying enzymes like glutathione S-transferase (GST) and its isozymes, GST- π and GST- α . Additionally, gallic acid, a major component of sumac, was found to reduce H₂O₂-induced DNA damage in human lymphocytes to a level similar to that of sumac itself. In a study involving Wistar rats, sumac extract administered either orally or intraperitoneally (at doses of 200, 400, or 800 mg/kg) increased the total antioxidant capacity (TAC). The antioxidant capacity in treatment groups using sumac extract and injectable vitamin C was significantly higher compared to control groups (10,22-31).

Further research is needed to understand the molecular mechanisms of the hydroalcoholic extract of sumac. Developing standard drug formulations could significantly enhance these beneficial effects.

References

1. Raghu G, Remy-Jardin M, Myers JL, Richeldi L, Ryerson CJ, Lederer DJ, et al. Diagnosis of idiopathic pulmonary fibrosis. An official ATS/ERS/JRS/ALAT clinical practice guideline. *Am J Respir Crit Care Med*. 2018;198(5):e44–68.
2. Duchemann B, Annesi-Maesano I, Jacobs de Naurois C, et al. Prevalence and incidence of

It is suggested to investigate the antioxidant effects of the sumac extract on other tissues affected by X-ray-induced oxidative stress and to explore various formulations of the sumac extract to assess their effectiveness in reducing oxidative stress. In this study, a single dose of X-rays significantly increased oxidative stress and lung tissue damage in rats. However, rats treated with vitamin C and hydroalcoholic extract of sumac at doses of 100 and 400 mg/kg intraperitoneally showed improvements in lung damage and a decrease in oxidative stress markers (hydroxyproline, NO, SOD, MDA, and MPO) along with an increase in total antioxidant capacity (TAC).

Ethical considerations

All ethical principles of working with laboratory animals were observed according to the instructions of the Hamadan University of Medical Sciences ethics committee. The research protocol was approved by this committee (IR.UMSHA.REC.1400.453).

Acknowledgments

This study is the result of a research plan approved by Hamadan University of Medical Sciences. We would like to express our gratitude to the Research and Technology Vice-Chancellor of Hamadan University of Medical Sciences for the financial support of this study in the form of project number 140007276155.

Funding/Support

This study was supported by the Hamedan University of Medical Sciences.

Conflict of interest

None to report

- interstitial lung diseases in a multi-ethnic county of Greater Paris. *Eur Respir J*. 2017; 50: 1602419.
3. Fois AG, Paliogiannis P, Sotgia S, Mangoni AA, Zinellu E, Pirina P, et al. Evaluation of oxidative stress biomarkers in idiopathic pulmonary fibrosis and therapeutic applications: a systematic review. *Respiratory research*. 2018;19(1):51.

4. Kinnula VL, Fattman CL, Tan RJ, Oury TD. Oxidative stress in pulmonary fibrosis: a possible role for redox modulatory therapy. *Am J Respir Crit Care Med.* 2005;172:417–422.
5. Mohammad MK, Mohamed MI, Zakaria AM, Abdul Razak HR, Saad WM. Watermelon (*Citrullus lanatus* (Thunb.) Matsum. and Nakai) juice modulates oxidative damage induced by low dose X-ray in mice. *BioMed research international.* 2014;2014:512834.
6. Abid SH, Malhotra V, Perry MC. Radiation-induced and chemotherapy-induced pulmonary injury. *Curr Opin Oncol.* 2001 Jul;13(4):242-8.
7. Bolourani S, Brenner M, Wang P. The interplay of DAMPs, TLR4, and proinflammatory cytokines in pulmonary fibrosis. *J Mol Med (Berl).* 2021;99(10):1373-1384.
8. Para AE, Bezjak A, Yeung IW, Van Dyk J, Hill RP. Effects of genistein following fractionated lung irradiation in mice. *Radiother Oncol.* 2009;92(3):500-10.
9. Mehrabani M, Goudarzi M, Mehrzadi S, Siahpoosh A, Mohammadi M, Khalili H, Malayeri A. Crocin: a protective natural antioxidant against pulmonary fibrosis induced by bleomycin. *Pharmacol Rep.* 2020;72(4):992-1001.
10. Kosar M, Bozan B, Temelli F, Baser KH. Antioxidant activity and phenolic composition of sumac (*Rhus coriaria* L.) extracts. *Food Chem.* 2007;103(3):952-9.
11. Hosseini S, Ramezan Y, Arab S. A comparative study on physicochemical characteristics and antioxidant activity of sumac (*Rhus coriaria* L.), cumin (*Cuminum cyminum*), and caraway (*Carum carvil*) oils. *J Food Meas Charact.* 2020;14(6):3175-83.
12. Nozza E, Melzi G, Marabini L, Marinovich M, Piazza S, Khalilpour S, et al. *Rhus coriaria* L. fruit extract prevents UV-A-induced genotoxicity and oxidative injury in human microvascular endothelial cells. *Antioxidants.* 2020;9(4):292.
13. Ashcroft T, Simpson JM, Timbrell V. Simple method of estimating severity of pulmonary fibrosis on a numerical scale. *J Clin Pathol.* 1988;41(4):467-70.
14. Raghu G, Collard HR, Egan JJ, Martinez FJ, Behr J, Brown KK, et al. An official ATS/ERS/JRS/ALAT statement: idiopathic pulmonary fibrosis: evidence-based guidelines for diagnosis and management. *Am J Respir Crit Care Med.* 2011;183(6):788-824.
15. Inghilleri S, Morbini P, Campo I, Zorzetto M, Oggionni T, Pozzi E, Luisetti M. Erratum to "factors influencing oxidative imbalance in pulmonary fibrosis: an immunohistochemical study". *Pulm Med.* 2011;2011:515608.
16. Ding Q, Luckhardt T, Hecker L, Zhou Y, Liu G, Antony VB, et al. New insights into the pathogenesis and treatment of idiopathic pulmonary fibrosis. *Drugs.* 2011;71(8):981–1001.
17. Hecker L. Mechanisms and consequences of oxidative stress in lung disease: therapeutic implications for an aging populace. *Am J Physiol Lung Cell Mol Physiol.* 2018;314(4):L642-53.
18. Macagno F, Varone F, Leone PM, Mari PV, Panico L, Berardini L, Richeldi L. New treatment directions for IPF: current status of ongoing and upcoming clinical trials. *Expert Rev Respir Med.* 2017;11(7):533-548.
19. Veith C, Drent M, Bast A, van Schooten FJ, Boots AW. The disturbed redox-balance in pulmonary fibrosis is modulated by the plant flavonoid quercetin. *Toxicol Appl Pharmacol.* 2017;336:40-48.
20. Weiss JF, Landauer MR. Protection against ionizing radiation by antioxidant nutrients and phytochemicals. *Toxicology.* 2003;189(1-2):1-20.
21. Pehlivan FE. Vitamin C: An antioxidant agent. *Vitamin C.* 2017;2:23-35.
22. Lee YH, Kim YS, Lee SN, Lee HC, Oh SJ, Kim SJ, et al. Interstitial lung change in pre-radiation therapy computed tomography is a risk factor for severe radiation pneumonitis. *Cancer Res Treat.* 2015;47:676–86.
23. Miglioretti DL, Johnson E, Williams A, Greenlee RT, Weinmann S, Solberg LI, et al. The use of computed tomography in pediatrics and the associated radiation exposure and estimated cancer risk. *JAMA Pediatr.* 2013;167(8):700-7.
24. Jang SS, Kim HG, Lee JS, Han JM, Park HJ, Huh GJ, Son CG. Melatonin reduces X-ray radiation-induced lung injury in mice by modulating oxidative stress and cytokine expression. *Int J Radiat Biol.* 2013;89(2):97-105.
25. Homma S, Azuma A, Taniguchi H, Ogura T, Mochiduki Y, Sugiyama Y, et al. Efficacy of inhaled N-acetylcysteine monotherapy in patients

with early stage idiopathic pulmonary fibrosis. *Respirology*. 2012;17(3):467-77.

26. Hagiwara SI, Ishii Y, Kitamura S. Aerosolized administration of N-acetylcysteine attenuates lung fibrosis induced by bleomycin in mice. *Am J Respir Crit Care Med*. 2000;162(1):225-31.

27. Mohammad MK, Mohamed MI, Zakaria AM, Abdul Razak HR, Saad WM. Watermelon (*Citrullus lanatus* (Thunb.) Matsum. and Nakai) juice modulates oxidative damage induced by low dose X-ray in mice. *Biomed Res Int*. 2014;2014:512834.

28. Alsamri H, Athamneh K, Pintus G, Eid AH, Iratni R. Pharmacological and Antioxidant Activities of *Rhus coriaria* L. (Sumac). *Antioxidants (Basel)*. 2021;10(1):73.

29. Ahmed Mobasher M, Galal El-Tantawi H, Samy El-Said K. Metformin Ameliorates Oxidative Stress Induced by Diabetes Mellitus and Hepatocellular Carcinoma in Rats. *Rep Biochem Mol Biol*. 2020;9(1):115-128.

30. Mahmoudivar S, Zarredar H, Asadi M, Zafari V, Hashemzadeh S, Farzaneh R, Asvadi Kermani T. Serum miR-23 and miR-150 Profiles as Biomarkers for Predicting Recurrence following Surgical Intervention in Colorectal Cancer Patients. *Rep Biochem Mol Biol*. 2024;12(4):540-549.

31. Azmoonfar R, Khosravi H, Rafieemehr H, Mirzaei F, Dastan D, Ghiasvand MR, et al. Radioprotective effect of *Malva sylvestris* L. against radiation-induced liver, kidney and intestine damages in rat: A histopathological study. *Biochem Biophys Rep*. 2023;34:101455.