

Celastrol Mitigates Acetaminophen-Induced Nephrotoxicity in Rats via Targeting Renal Oxidative Stress, Inflammation, Apoptosis with Enhancement in Aquaporin 1 Level

Mohie Mahmoud Ibrahim^{1,2}, Amira Osman^{1,3}, Azza Ibrahim Helal³,
Ahmed Mohsen Faheem⁴, Mohammad Abd-El-Same'e El-Kattan⁵,
Iman Ibrahim⁶, Ahmed Abdel-monem Elmetwally⁷, Sara Abubakr²,
Alaa Mohamed Badawy², Emadeldeen Hussin*²

Abstract

Background: Acetaminophen also name paracetamol is a popular antipyretic and analgesic drug, in large doses produces a acute kidney injury either in human and animals. The aim of this study to assess the effect of celastrol in reducing acetaminophen-induced nephrotoxicity and to elucidate its underlying mechanisms.

Methods: Rats were divided into four groups: control, celastrol-treated, acetaminophen-exposed, and a group receiving both acetaminophen and celastrol. After 24 hours, blood samples were taken and kidney tissues were harvested for histological and molecular analyses. The findings shed light on the protective effects of celastrol against acetaminophen-induced nephrotoxicity, offering insights into its therapeutic potential.

Results: paracetamol oral intake altered renal histology with significantly $P < 0.05$ increased serum creatinine, blood urea nitrogen (BUN), and homogenate malonaldehyde (MDA), and immunoexpression of tumor necrosis- α (TNF- α), interleukin-6 (IL-6), caspase-3, Bcl-2-associated X- protein (Bax). Furthermore, it decreases homogenate level of superoxide dismutase (SOD), catalase (CAT), glutathione (GSH), and gene expression of nuclear factor erythroid 2-related factor 2 (Nrf2), and haem oxygenase-1 (HO-1). Meanwhile, intraperitoneal injection of celastrol with acetaminophen reaffirms the previous results.

Conclusion: We provided a novel treatment against acetaminophen induced-nephrotoxicity with targeting renal oxidative stress, inflammation, apoptosis with elevation of Aquaporin 1 (AQP1) level.

Keywords: Acetaminophen Apoptosis, Aquaporin 1 (AQP1), Celastrol, Inflammation, Oxidative Stress.

Introduction

Paracetamol (PAR), a commonly used analgesic-antipyretic medication, demonstrates efficacy at therapeutic doses but

carries substantial risks of adverse effects at elevated levels (1). Overdosing on PAR has been linked to renal and liver failure, with

1: Department of Basic Medical and Dental Sciences, Faculty of Dentistry, Zarqa University, Zarqa, Jordan.

2: Department of Anatomy and Embryology, Faculty of Medicine, Mansoura University, Egypt.

3: Department of Histology and Cell Biology, Faculty of Medicine, Kafrelsheikh University, Egypt.

4: Department of Medical Biochemistry and Molecular Biology, Faculty of Medicine, Mansoura University, Egypt.

5: Department of Forensic Medicine and Clinical Toxicology, Faculty of Medicine, Mansoura University, Egypt.

6: Department of Pathology, Faculty of Veterinary Medicine, Mansoura University, Mansoura 35516, Egypt.

7: Clinical Pharmacology Department, Faculty of Medicine, Mansoura University, Egypt. 35516.

*Corresponding author: Emadeldeen Hussin; Tel: +20 1018914906; E-mail: emadeldeenahmed@mans.edu.eg.

Received: 28 Apr, 2024; Accepted: 9 Jun, 2024

current guidelines relying on outdated dosing calculations dating back to the 1970s. Massive overdoses can lead to nephrotoxicity, resulting in acute tubular necrosis and renal failure (2). Although toxic doses have been investigated in rats, comprehensive data in the international literature remains scarce. Elevated levels of serum creatinine and blood urea nitrogen serve as indicators of PAR-induced acute tubular necrosis, affecting 1-2% of patients exposed to overdose (3,4).

The mechanism of PAR-induced liver injury involves the formation of a reactive intermediate, N-acetyl p-benzoquinonimine (NAPQI), which is also involved in nephrotoxicity (5). Renal toxicity occurs due to the saturation of glucuronidation, and sulphation pathways, leading to an imbalance between NAPQI and basal glutathione levels (6). Consequently, toxic metabolites cause subendothelial damage and acute tubular necrosis. N-acetyl cysteine (NAC) is the sole clinically used antidote for PAR intoxication, necessitating prompt administration for hepatoprotection (7). As an alternative to NAC, this study delves into celastrol, a quinone methide triterpene sourced from *Tripterygium wilfordii* Hook F. Celastrol, historically employed in traditional medicine for autoimmune diseases and cancer, exhibits antioxidant properties by diminishing reactive oxygen species, inhibiting lipid peroxidation, and augmenting the cellular glutathione cycle (8-11). The research aims to investigate the potential therapeutic effects of celastrol post treatment on acetaminophen-induced nephrotoxicity, leveraging its promising antioxidant properties.

Materials and Methods

Experimental Animals

Forty male Wistar rats, with weights ranging from 220-250 grams, were procured from the Faculty of Veterinary Medicine, Zagazig University. Following a 7-day acclimatization period in plastic cages with standard laboratory diet and ad libitum access to water, the rats were segregated into four groups, each comprising eight rats. All experimental protocols were

authorized by the ethical committee (KFS-IACUC/185/2024).

Medications

Celastrol was sourced from Sigma-Aldrich Co. (St. Louis, MO, USA), and stock solutions for injection were prepared on a weekly basis. Acetaminophen (paracetamol) was commercially available, was sourced from Sigma Chemicals, Balcatta, WA, USA.

Experimental Design

The study involved four groups of 10 rats each. Group 1 (control) received saline orally and intraperitoneal saline injection. Group 2 (celastrol) received a sole intraperitoneal injection of celastrol (2 mg/kg) (12). Group 3 (acetaminophen) received a single oral dose of acetaminophen (1000 mg/kg suspension) (13). Group 4 (acetaminophen + celastrol) was pretreated with intraperitoneal celastrol 24 h before acetaminophen challenge. After 24 h, all rats were sacrificed, blood was collected, serum stored, and kidney tissues fixed, in 4% paraformaldehyde (PFA), for histological analysis or stored at -80 °C for mRNA and protein analysis. Thiopental was used for anaesthesia during sacrifice.

Blood Sampling

Upon completion of the experiment, the rats underwent overnight fasting. Blood samples were collected from the heart of each rat and transferred to EDTA-free tubes. Following this, the serum was isolated and stored at -20 °C until further analysis.

Evaluation of Renal Function Tests

Kidney function tests in the rat sera were evaluated by employing colorimetric assays with urea and creatinine detection kits purchased from Bio-Diagnostic Co. (Dokki, Giza, Egypt). The manufacturer's instructions were rigorously adhered to during the execution of these assays.

Preparation of Tissue Homogenates

Kidney samples were homogenized. Subsequently, the supernatant was extracted

and stored for subsequent use in the detection of oxidative stress markers.

Estimation of Oxidative Stress Markers

The supernatants obtained from kidney tissue were used to evaluate the reduced levels of superoxide dismutase (SOD), catalase (CAT), homogenate malonaldehyde (MDA), and glutathione (GSH) levels. Detection kits from the Bio-Diagnostic company, Egypt, were used according to the manufacturer's instructions.

Measurement of inflammation markers

Aquaporin 1 (AQP1) levels in the renal tissues were detected with a commercial rat enzyme-linked immunosorbent assay (ELISA) kit (Cat No ab15080, Abcam; Cambridge, United Kingdom) according to the manufacturer's instruction.

Histopathological Examination of the Kidney

Sections of each kidney were excised, washed, and dried before being fixed in formaldehyde solution (10%). These fixed kidney segments were then embedded in paraffin, following the protocol detailed by El Tohamy *et al.* (14). The kidney sections were then subjected to histopathological examination to assess any structural changes. For this analysis, transverse sections with a thickness of 8 micrometers were prepared, stained using hematoxylin, and eosin (H&E). The histopathological examinations of kidney sections were performed by the same pathologists who were blinded to the group definitions. Sections were investigated for tubular changes (tubular degeneration, necrosis, and ectasia with intraluminal formation of hyaline and granular casts) and inflammatory response. A semi-quantitative scale ranged from 0-3, as conducted in Table 1, was used for the evaluation of four randomly selected fields of view for each group at 40× magnification.

Immunohistochemistry

The immunoperoxidase method was employed on 3-micrometer-thick transverse sections of kidney tissue, following the protocol outlined in Elmorshdy *et al.* (15). Briefly, the slides were subjected to deparaffinization, and endogenous peroxidase activity was inhibited. Kidney

sections were treated with a solution of 0.3% methanol and hydrogen peroxide for 10 minutes at room temperature, followed by heating in 10 mM citrate buffer at 95 °C for 10 minutes to facilitate antigen retrieval. After cooling for one hour, primary antibodies specific for TNF- α (Cat No. MBS839915, MyBioSource; San Diego, United States), IL-6 (Cat No. A21264, Abclonal; Woburn, United States), Bax (Cat No. A12009, Abclonal; Woburn, United States) and Caspase-3 (Cat No. CPP32 4-1-18, Thermo Fisher; Waltham, MA United States) were applied to sections and incubated overnight at 4 °C. Subsequently, the slides were incubated for 30 minutes with a mouse-rabbit polydetector (BSB 0268, Bioscience). A reagent control (no primary antibody) was included using phosphate- buffered- saline (PBS) instead of the primary antibody for comparison. The sections were then subjected to washing, dehydration, and examination, with positive staining indicated by dark brown areas against a blue background (16).

RT-PCR Assessment

The extraction of total RNA from homogenized renal tissue was performed using the direct-zol RNA kit (Cat# R2072, USA). Subsequently, the total RNA was reverse transcribed into complementary DNA (cDNA) using the RT-PCR kit (Cat# 12594100, Thermo Fisher Scientific, Waltham, MA, USA), followed by PCR. A 96-well plate StepOne instrument (Applied Biosystems, USA) was used with a specific thermal profile. After the RT-PCR run, the data were presented in Cycle threshold (Ct) values for both the target genes and the housekeeping gene. To account for variations in target gene expression (Nrf2, HO-1), normalization was carried out based on the mean critical threshold (CT) expression values of the housekeeping gene Glyceraldehyde-3-phosphate dehydrogenase (GAPDH), utilizing the $\Delta\Delta C_t$ method. Relative quantification (RQ) of each target gene was calculated using the 2^{-C_t} method. The primer sequences for the genes were as follows: Nrf2 gene [Forward 5'-CTGCCGTAAACGCAAGATGG-3' and Reverse 5'-ATCCGTTGACTGCTGAAGGG-

3' (gene bank accession number XM_003447296.5)], HO-1 gene [Forward 5'-CATCCGTGCAGAGAATTCTG-3' and Reverse 5'-CTGGTATGGGCCCCACTGGC-3' (gene bank accession number NM_012580.2)] and GAPDH housekeeping gene [Forward 5'-CCTCGTCTCATAGACAAGATGGT-3' and Reverse 5'-GGGTAGAGTCATACTGGAACATG-3' (GenBank accession number NM_001394060.2)].

Statistical analysis

The results of our work were expressed as mean±SD, and the assessment of significant differences between groups was performed

using one-way ANOVA followed by a post hoc Bonferroni test. $P < 0.05$ was statistically significant.

Results

Effect of celastrol on Acetaminophen-Induced renal function disturbance

Acetaminophen ingestion revealed a significant increase in renal function test markers, creatinine, and BUN ($P < 0.001$) (Figs. 1A & B). On the other hand, celastrol oral intake combined with acetaminophen significantly improved renal function test results ($P < 0.001$) in comparison to the acetaminophen group. Celastrol markedly improves the deteriorated kidney function induced by acetaminophen nephrotoxicity.

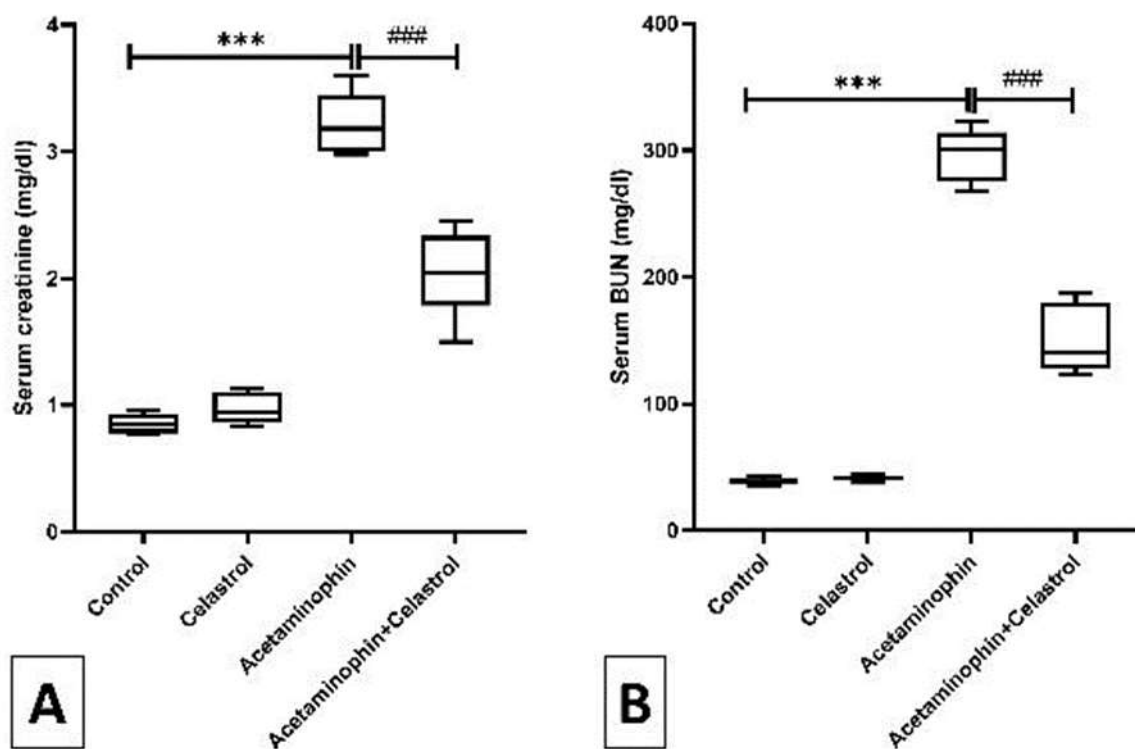


Fig. 1. Renal function test markers (creatinine and BUN) in different experimental groups: Data are expressed as mean ± SD, *** $P < 0.001$ significant versus control group; ### $P < 0.001$ significant versus acetaminophen group.

Impact of celastrol on acetaminophen-induced renal oxidative insult

Acetaminophen oral intake induced severe oxidative insult in renal tissues appeared in a significant $P < 0.001$ elevation in lipid peroxidation marker MDA and decrease in the homogenate levels of the antioxidant enzymes

SOD, CAT, and GSH compared to the control group. Fortunately, celastrol intake with acetaminophen possessed antioxidant power in the form of a significant $P < 0.001$ reduction of MDA by $P < 0.001$ and an increase in SOD, CAT compared to the acetaminophen group

(Figs. 2A, B, C, & D). Furthermore, treatment with celastrol significantly $P < 0.001$ improved the expression of antioxidant genes by

increasing Nrf2 and its antioxidant reducing elements (HO-1) at the level of mRNA relative to the acetaminophen group (Figs. 2E & F).

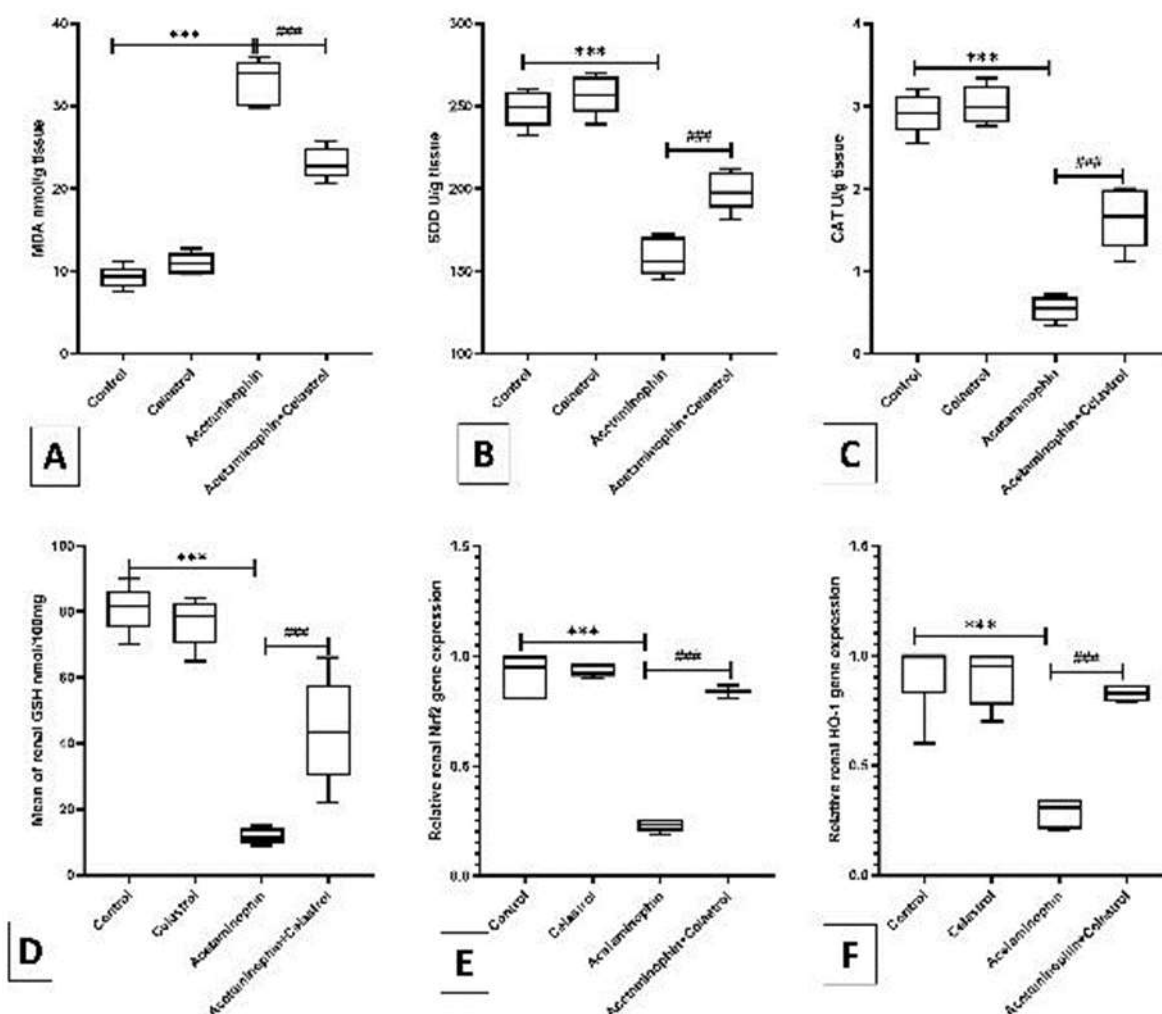


Fig. 2. Effect of celastrol on oxidative stress markers (MDA, SOD, CAT, GSH) in renal homogenate and gene expression of regulatory genes of antioxidant enzymes (Nrf2, HO-1) in different groups of rats: Data are expressed as mean \pm SD, *** $P < 0.001$ significant versus the control group; ### $P < 0.001$ significant versus the acetaminophen group.

The Role of celastrol on acetaminophen-induced altered renal morphology

The kidney histopathological changes were examined in different treatment groups. The control and celastrol groups showed a normal histological appearance of cortical tubules and glomerular architecture with partial sloughing in the cortical tubules of the celastrol control (Figs. 3A-C). However, there was diffuse disruption of the cortical tubules with swollen tubular epithelial cells, large vesiculated nuclei (degeneration), or shrunken, hyper-eosinophilic necrotic epithelial cells with pyknotic nuclei observed in the acetaminophen

group. Furthermore, tubular dilation or ectasia lined with attenuated epithelium and containing intraluminal eosinophilic homogenous hyaline material occasionally admixed with eosinophilic necrotic debris or desquamated epithelial cells forming a granular cast were also detected. Interstitial lymphoplasmacytic inflammation surrounded and replaced the necrotic and ectatic tubules (Figs. 3 D-G). In contrast to acetaminophen group, minimal to mild tubular changes were represented by mild tubular epithelial desquamation with few intraluminal hyaline granular casts and periglomerular

inflammatory aggregates in the acetaminophen + celastrol group (Figs. 3H & I). From this

finding, we can document the protective effect of celastrol on renal histology.

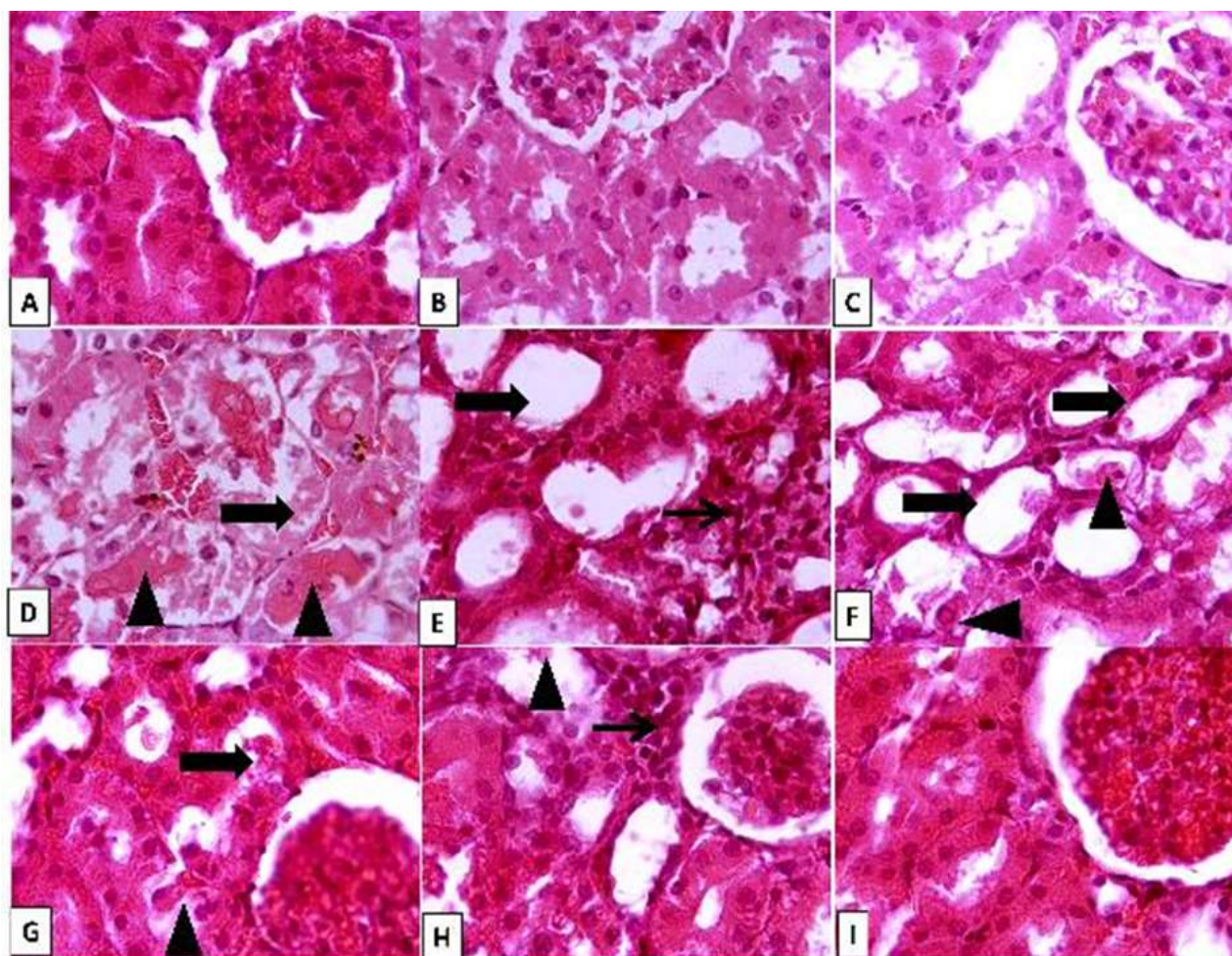


Fig. 3. Representative photomicrographs of kidney from different treatment groups. A, B) Control kidney showing normal histological appearance of renal parenchyma with intact cortical tubules and glomeruli. C) Celastrol group showing up to 95% of renal parenchyma appearing normal. D) Acetaminophen group showing diffuse disruption of tubular architecture (thick arrow) with abundant intraluminal eosinophilic homogeneous proteinaceous materials (proteinosis) admixed with desquamated epithelial cells or sloughed necrotic debris that forms a granular cast (arrowheads). E) Acetaminophen group showing focal to coalescing interstitial inflammation composed of lymphoplasmacytic cells and macrophages (thin arrow) surrounded by necrotic tubules, some of the adjacent tubules showing tubular ectasia (thick arrow). F) Acetaminophen group showing abundant ectatic and dilated tubules (thick arrows) lined with attenuated epithelium or desquamated hyperesinophilic necrotic epithelial cells (arrowheads). G) Acetaminophen+ celastrol group showing minimal to mild tubular damage with few intraluminal desquamated epithelial cells (arrowhead) forming granular casts (thick arrow). H) Acetaminophen+ celastrol group showing minimal to mild periglomerular cellular infiltrates (thin arrow) surrounding occasional necrotic tubules with desquamated epithelium (arrowhead). I) Acetaminophen+ celastrol group showing up to 90-95% of renal parenchyma with normal architecture. Image magnification=400x.

Anti-inflammatory effect of celastrol against acetaminophen-induced renal inflammation

Administration of acetaminophen induced nephroinflammation by a significant elevation $P < 0.001$ elevation in the immunoexpression of the pro-inflammatory markers TNF- α and IL6 (Figs. 4C, 5C D & E) compared to the

control groups (Figs. 4A, B, 5A, B). On the contrary, co-administration of celastrol with acetaminophen resulted in a significant $P < 0.001$ decrease in immunoexpression (Figs. 4F & 5F). Celastrol exerts a powerful anti-inflammatory effect in acetaminophen-induced nephrotoxicity.

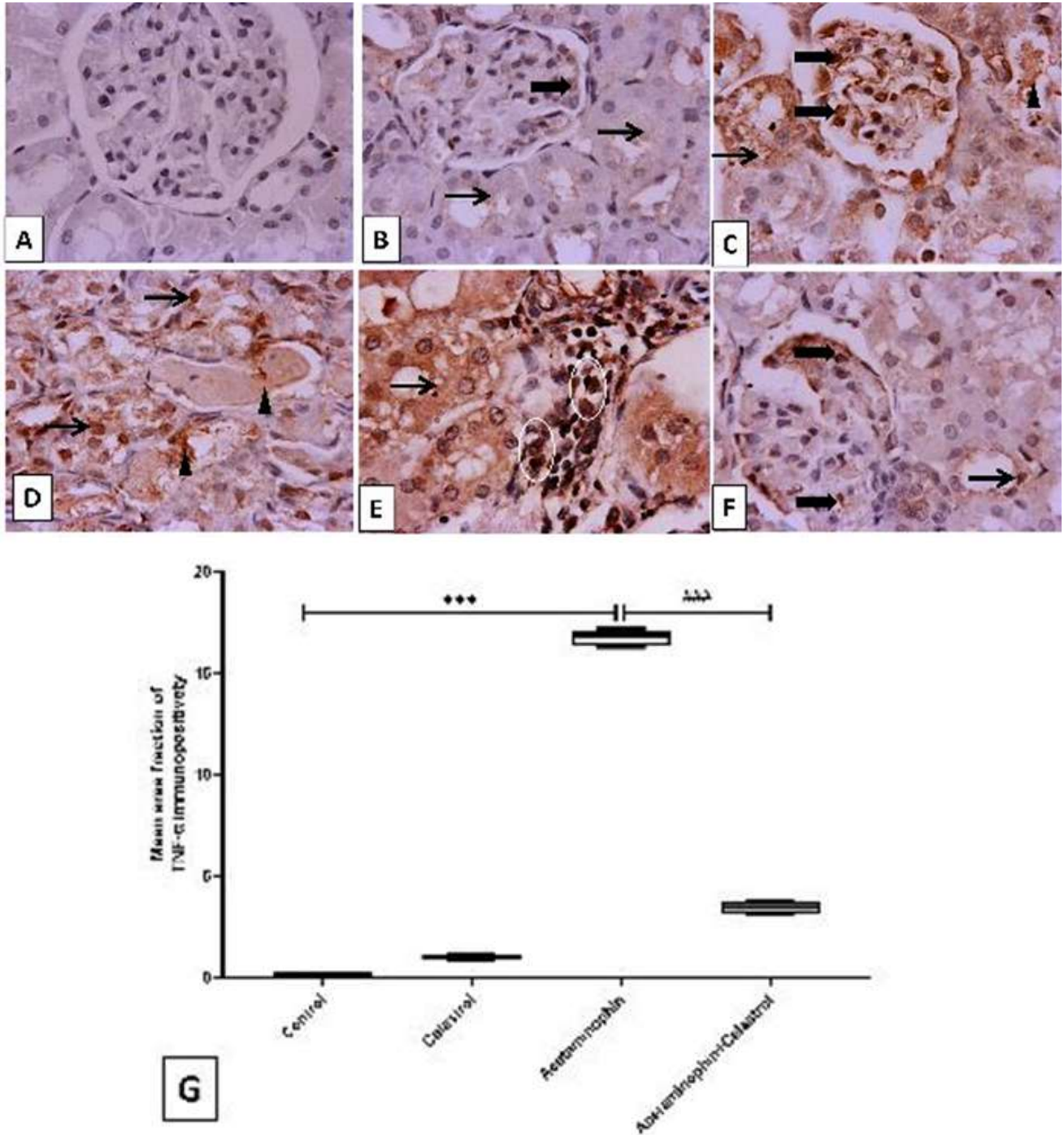


Fig. 4. Representative IHC staining of TNF- α expression in the kidney section of different treatment groups. A) Kidney sections of control rats showing negative to faint immunostaining in the glomerulus and cortical renal tubules. B) Celastrol group section showing weak immunopositive staining in tubular and glomerular cells. C, D, & E) Acetaminophen group showing diffuse and strong intense cytoplasmic and nuclear immunopositive staining in tubular epithelial cells and invading inflammatory cells, insets strong cytoplasmic expression in tubular epithelial cells. F) Acetaminophen + celastrol group showing minimal tubular expression, inset few faint cytoplasmic expressions in renal tubules. Thin arrow= positive immunostained tubular epithelial cells, thick arrow= positive glomerular cells, arrowhead= positive intraluminal desquamated cells, circle indicates positive immunostained inflammatory cells. Data are expressed as mean \pm SD, ***P< 0.001 significant versus the control group; ###P< 0.001 significant versus the acetaminophen group. Image magnification= 100x, inset=400x.

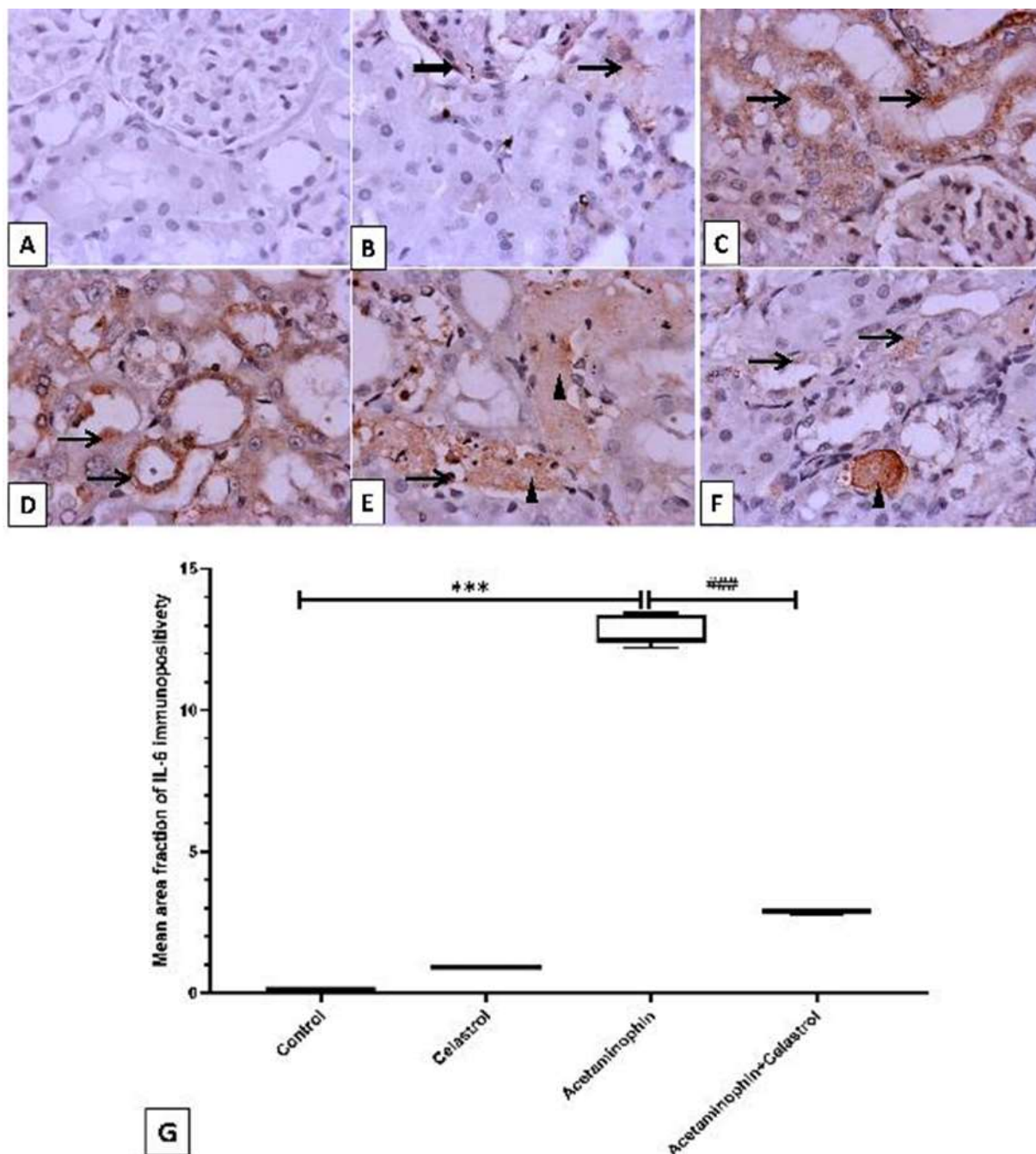


Fig. 5. Representative IHC staining of IL-6 expression in the kidney section of different treatment groups. A) Kidney sections of control rats showing negative immunostaining in the glomerulus and cortical renal tubules. B) Celastrol group kidney section showing faint immunopositive staining in tubular epithelial cells with weak expression in podocytes. C, D, & E) Acetaminophen group showing strong cytoplasmic immunopositive staining in tubular epithelial cells. F) Acetaminophen+ celastrol group showing minimal and weak tubular expression, with greater expression in intraluminal cellular cast. Thin arrow= positive immunostained tubular epithelial cells, thick arrow= positive glomerular cells, arrowhead= positive intraluminal desquamated cells. Data are expressed as mean \pm SD, *** P < 0.001 significant versus control group; #### P < 0.001 significant versus acetaminophen group. Image magnification= 100x, inset=400x.

Anti-apoptotic effect of celastrol against acetaminophen-induced tubular apoptosis

Immunohistological examination of the renal tissues of acetaminophen group revealed a

significant P < 0.001 increase in the number of tubular epithelial cells expressing caspase-3 and Bax (Figs. 6C, D, E, 7C, D, & E) compared to the control group (Figs. 6A, B, 7A, & B). Fortunately, combined intake of celastrol with

acetaminophen markedly decreased the number of apoptotic cells in relation to acetaminophen

(Figs. 6F, & 7F). This finding confirmed the anti-apoptotic power of celastrol.

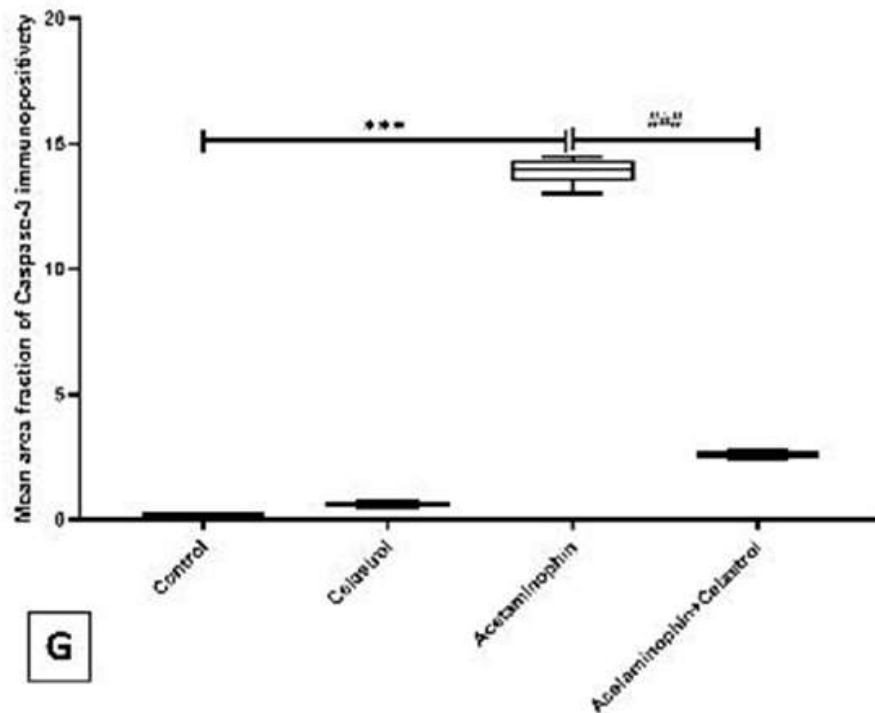
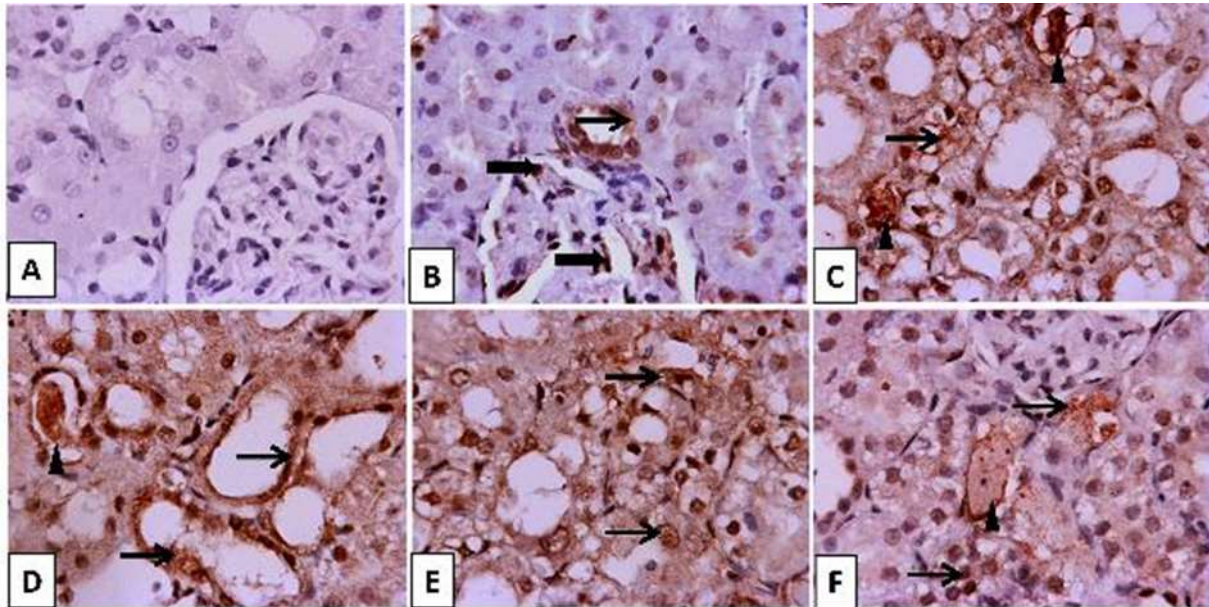


Fig. 6. Representative IHC staining of caspase-3 expression in the kidney section of different treatment groups. A) Kidney sections of control rats showed negative immunostaining in the glomerulus and cortical renal tubules. B) Celastrol group kidney section showing few faint immunopositive stained tubular epithelial cells and glomerular cells (mesangial, podocytes and endothelial cells). C, D, E) Acetaminophen group showed diffuse strong immunopositive staining in tubular epithelial cells and intraluminal cast, insets indicate strong nuclear and cytoplasmic expression in tubular epithelial cells. F) Acetaminophen+celastrol group showed mild tubular expression with intraluminal positive stained cellular cast. Thin arrow indicates positive immunostained tubular cells, thick arrow indicates positive immunostained glomerular cells, and arrowhead indicates positive intraluminal desquamated cells or cellular cast. Data are expressed as mean \pm SD, *** P < 0.001 significant versus control group; ### P < 0.001 significant versus acetaminophen group. Image magnification= 100x, inset=400x.

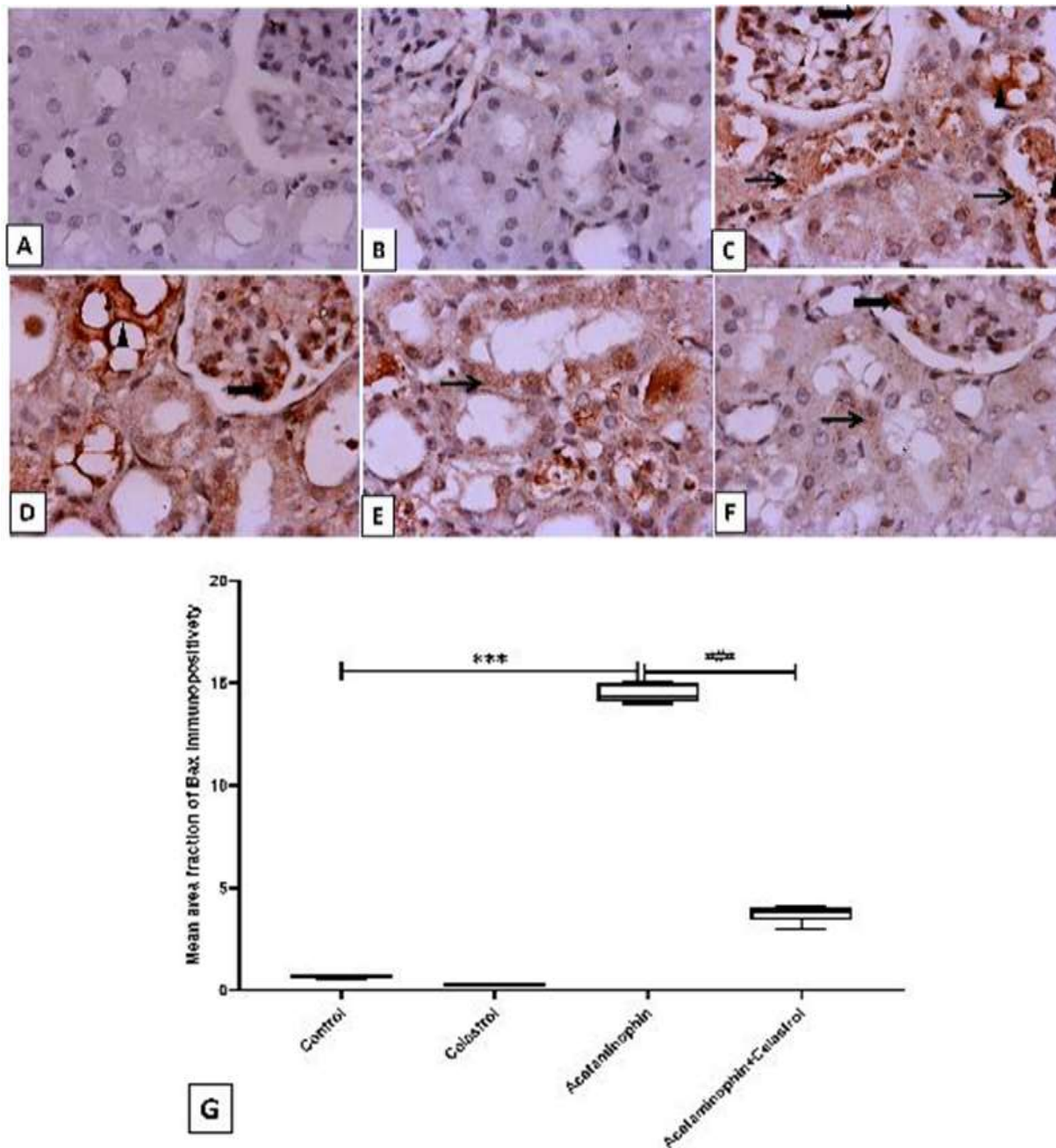


Fig. 7. Representative IHC staining of Bax expression in the kidney section of different treatment groups. A) Kidney sections of control rats showing negative immunostaining in the glomerulus and cortical renal tubules. B) Celastrol group kidney section showing weak immunopositive staining in the glomerulus and tubular epithelial cells. C, D, E) Acetaminophen group showing diffuse strong immunopositive staining in glomerular cells, tubular epithelial cells, intraluminal desquamated epithelial cells, and the cast. F) Acetaminophen+celastrol group showing minimal to mild faint tubular and glomerular expression. Thin arrow= positive immunostained tubular epithelial cells, thick arrow= positive glomerular cells, arrowhead= positive intraluminal desquamated cells. Data are expressed as mean \pm SD, *** P <0.001 significant versus control group; ### P <0.001 significant versus acetaminophen group. Image magnification= 100x, inset=400x.

Up-regulation effect of celastrol on renal aquaporins 1

Oral ingestion of acetaminophen markedly P < 0.001 decreased homogenate level of AQP-1 in a way comparable to the control group (Fig. 8). Likewise, Acetaminophen+ celastrol group

revealed a significant P < 0.001 upregulation in immunoexpression of AQP1 compared to the acetaminophen group (Fig. 8). From this result, we identified the beneficial effect of celastrol on AQP1 water channel proteins.

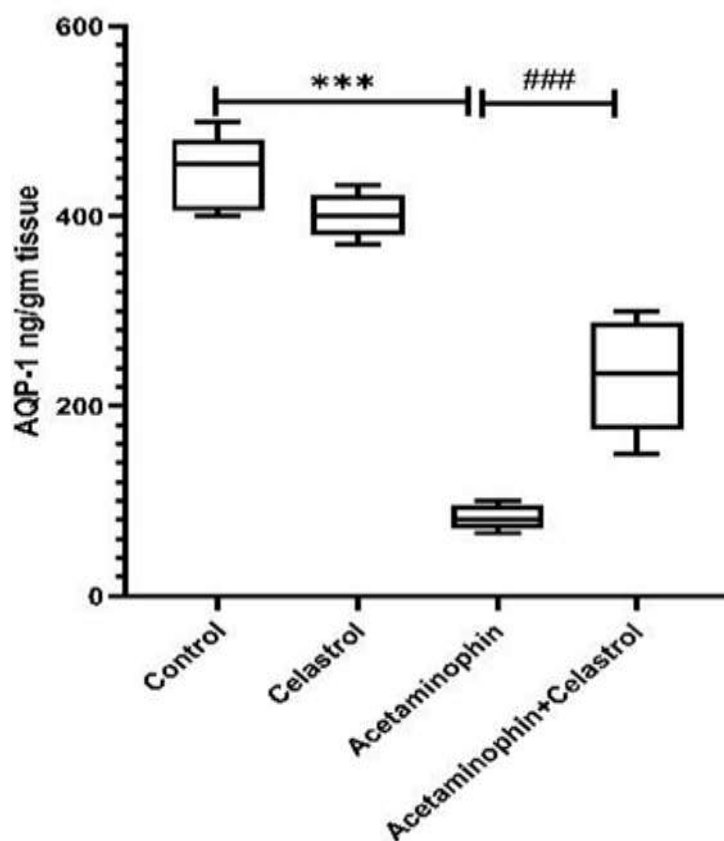


Fig. 8. Effect of AQP-1 on renal homogenate in different groups of rats by ELISA: Data are expressed as mean \pm SD, *** P < 0.001 significant versus control group; ### P < 0.001 significant versus acetaminophen group.

The effect of quercetin (QCT), and catechin (CAT) on the expression of PARP (poly ADP-ribose polymerase) protein in the liver of diabetic mice. Data are expressed as mean \pm SEM ($n=6$). (* P < 0.05, ** P < 0.01 and *** P < 0.001).

Discussion

In the current study, we found that the administration of 1000 mg/kg of acetaminophen given orally once was associated with a marked increase in renal function tests, elevated oxidative and inflammatory markers with an increase in the number of renal apoptotic cells, and a marked decrease in the renal protein level of AQP-1. The main objective of this study is to evaluate the protective effect of celastrol against acetaminophen-induced nephrotoxicity and its mechanistic role. Disturbed renal function related to acetaminophen overdose can be demonstrated clinically based on laboratory examination of BUN, serum creatinine (17). In our study, oral intake of acetaminophen markedly increased serum creatinine and BUN, deteriorating renal function that was associated with histological alternations in the

form of tubular epithelial degeneration with cast formation. The results of our study are consistent with the previous study by Topal *et al.*, (13). On the other hand, celastrol administration counteracted the effect of acetaminophen by decreasing the level of renal function and improving renal histology. Previous study by Younis *et al.*, (18) has reported the nephroprotective effect of celastrol against renal ischemia-reperfusion. Paracetamol-induced nephrotoxicity may be due to its metabolic activation with the production of NAPQI (19). Overproduction of NAPQI results in GSH depletion (20). In our work paracetamol significantly decreased antioxidant markers such as SOD, CAT, and GSH, while increasing the lipid peroxidation marker MDA. The down-regulatory effect of paracetamol can be considered due to its inhibitory effect on the gene expression of the

antioxidant regulatory genes Nrf2 and HO-1. The finding of our study is consistent with the previous work by Alqahtani et al., (21) who documented the down-regulation effect of glutathione, superoxide dismutase, and Nrf2 expression in acetaminophen-induced nephropathy. Fortunately, Celastrol intake antagonized acetaminophen-induced oxidative insult increasing antioxidant levels and leading to the upregulation of mRNA expression of antioxidant regulatory genes Nrf2 and HO-1, this results parallel to the finding of the previous literature by Jannuzzi et al., (22) who reported that Celastrol treatment improved GSH content and decreased lipid peroxidation in acetaminophen treated HepG2 cells. Additionally, with the previous work done by Pan et al. (23) who documented the up regulatory effect of celastrol on Nrf2 in cisplatin-induced acute kidney injury.

Sever inflammatory cascade in acute renal injury usually occur as a result of oxidative stress (24). In the present work oral intake of a large dose of acetaminophen markedly elevated the immunoexpression of proinflammatory markers TNF- α and IL-6, in accordance with the study of Ucar et al., (25). Meanwhile, celastrol coadministration with acetaminophen produced a drastic drop in the levels of these inflammatory marker. This finding in line with the previous study done by Yu et al. (12).

Several studies have demonstrated that a large dose of paracetamol induces apoptosis in several tissues and markedly increases the level of caspase-3 (26), so we examined the effect of paracetamol overdose on tubular epithelial cell apoptosis through histopathological examination. In our study we found that paracetamol increased immunoexpression of Caspas-3 and Bax apoptotic markers, consistent with previous work done by Hussain et al. (27). In contrast, celastrol exhibited an anti-apoptotic effect against acetaminophen-induced tubular epithelial apoptosis by decreasing the immunoexpression of caspase-3 and Bax, in line with the previous done by Yu et al. (12).

Aquaporins (AQPs) are water channel proteins with isoforms ranging from AQP0 to AQP12 (28). They play an important role in epithelial fluid secretion, renal water balance, adipocyte metabolism, cell migration, and brain oedema. The AQP1 is highly expressed in proximal tubules and thin descending limbs as well as renal endothelium including renal vasa recta (29). In our study acetaminophen administration markedly decreased the protein level of AQP1 as measured by ELISA. In contrast celastrol significantly increased the protein level of AQP1. To the best of our knowledge, our work is the first to discuss the harmful effect of paracetamol and the protective effect of celastrol on renal AQP1 levels.

Our study investigated the potential protective role of celastrol against acetaminophen-induced nephrotoxicity. This protective effect can be attributed to its antioxidant, anti-inflammatory, and antiapoptotic properties, along with its modulation of AQP1 levels in renal tissues. Overall, our findings indicate that celastrol shows promise as a treatment for mitigating the nephrotoxic effects of acetaminophen overdose.

Acknowledgement

Authors declared that nobody is acknowledged to this work.

Conflict of interest

All authors declare that there are no conflicts of interest.

Funding

This research work was self-funded and did not receive any fund from anywhere.

Ethics

The study was conducted in accordance with the Canadian Council on Animal Care Guidelines and approved by the committee of Research Ethics, Kafrelsheikh University with approval code (KFS-IACUC/185/2024).

References

- Prescott LF. Kinetics and metabolism of paracetamol and phenacetin. *Br J Clin Pharmacol*. 1980;10 Suppl 2(Suppl 2):291S-298S.
- Marks DJB, Dargan PI, Archer JRH, Davies CL, Dines AM, Wood DM, et al. Outcomes from massive paracetamol overdose: a retrospective observational study. *Br J Clin Pharmacol*. 2017;83(6):1263-1272.
- Zhao YL, Zhou GD, Yang HB, Wang JB, Shan LM, Li RS, et al. Rhein protects against acetaminophen-induced hepatic and renal toxicity. *Food Chem Toxicol*. 2011;49(8):1705-10.
- Georgiadis G, Mavridis C, Belantis C, Zisis IE, Skamagkas I, Fragkiadoulaki I, et al. Nephrotoxicity issues of organophosphates. *Toxicology*. 2018;406-407:129-136.
- Commandeur JN, Vermeulen NP. Cytotoxicity and cytoprotective activities of natural compounds. The case of curcumin. *Xenobiotica*. 1996;26(7):667-680.
- Richie JP Jr, Lang CA, Chen TS. Acetaminophen-induced depletion of glutathione and cysteine in the aging mouse kidney. *Biochem Pharmacol*. 1992;44(1):129-135.
- Green JL, Heard KJ, Reynolds KM, Albert D. Oral and Intravenous Acetylcysteine for Treatment of Acetaminophen Toxicity: A Systematic Review and Meta-analysis. *West J Emerg Med*. 2013;14(3):218-226.
- Gu L, Bai W, Li S, Zhang Y, Han Y, Gu Y, et al. Celastrol prevents atherosclerosis via inhibiting LOX-1 and oxidative stress. *PLoS One*. 2013;8(6):e65477.
- Guan Y, Cui ZJ, Sun B, Han LP, Li CJ, Chen LM. Celastrol attenuates oxidative stress in the skeletal muscle of diabetic rats by regulating the AMPK-PGC1 α -SIRT3 signaling pathway. *Int J Mol Med*. 2016;37(5):1229-1238.
- Sassa H, Takaishi Y, Terada H. The triterpene celastrol as a very potent inhibitor of lipid peroxidation in mitochondria. *Biochem Biophys Res Commun*. 1990;172(2):890-897.
- Galal RM, Zaki HF, Seif El-Nasr MM, Agha AM. Potential protective effect of honey against paracetamol-induced hepatotoxicity. *Arch Iran Med*. 2012;15(11):674-680.
- Yu X, Meng X, Xu M, hang X, Zhang Y, Ding G, et al. Celastrol ameliorates cisplatin nephrotoxicity by inhibiting NF- κ B and improving mitochondrial function. *EBioMedicine*. 2018;36:266-280.
- Topal I, Özdamar MY, Catakli T, Malkoc İ, Hacimuftuoglu A, Mamoulakis C, et al. Renoprotective Effect of Taxifolin in Paracetamol-Induced Nephrotoxicity: Emerging Evidence from an Animal Model. *J Clin Med*. 2023;12(3):876.
- El Tohamy M, Adel M, Rashad El-Menabawy F, Gad GEM, El-Gamal R, El Serougy H. Role of Cannabinoid Type 2 Receptor Activation in Renal Fibrosis Induced by Unilateral Ureteric Obstruction in Rats. *Rep Biochem Mol Biol*. 2023;12(1):59-73.
- Elmorshdy Elsaeed Mohammed Elmorshdy S, Ahmed Shaker G, Helmy Eldken Z, Abdelbadie Salem M, Awadalla A, Mahmoud Abdel Shakour H, et al. Impact of Cerium Oxide Nanoparticles on Metabolic, Apoptotic, Autophagic and Antioxidant Changes in Doxorubicin-Induced Cardiomyopathy: Possible Underlying Mechanisms. *Rep Biochem Mol Biol*. 2023;12(3):495-511.
- Ramos-Vara JA, Miller MA. When tissue antigens and antibodies get along: revisiting the technical aspects of immunohistochemistry--the red, brown, and blue technique. *Vet Pathol*. 2014;51(1):42-87.
- Ndetan H, Evans MW Jr, Singal AK, Brunner LJ, Calhoun K, Singh KP. Light to moderate drinking and therapeutic doses of acetaminophen: An assessment of risks for renal dysfunction. *Prev Med Rep*. 2018;12:253-258.
- Younis NS, Ghanim AMH. The Protective Role of Celastrol in Renal Ischemia-Reperfusion Injury by Activating Nrf2/HO-1, PI3K/AKT Signaling Pathways, Modulating NF- κ B Signaling Pathways, and Inhibiting ERK Phosphorylation. *Cell Biochem Biophys*. 2022;80(1):191-202.
- El-Maddawy ZK, El-Sayed YS. Comparative analysis of the protective effects of curcumin and N-acetyl cysteine against paracetamol-induced hepatic, renal, and testicular toxicity in Wistar rats. *Environ Sci Pollut Res Int*. 2018;25(4):3468-3479.

20. Bessems JG, Vermeulen NP. Paracetamol (acetaminophen)-induced toxicity: molecular and biochemical mechanisms, analogues and protective approaches. *Crit Rev Toxicol.* 2001;31(1):55-138.
21. Alqahtani QH, Fadda LM, Alhusaini AM, Hasan IH, Ali HM. Involvement of Nrf2, JAK and COX pathways in acetaminophen-induced nephropathy: Role of some antioxidants. *Saudi Pharm J.* 2023;31(10):101752.
22. Jannuzzi AT, Kara M, Alpertunga B. Celastrol ameliorates acetaminophen-induced oxidative stress and cytotoxicity in HepG2 cells. *Hum Exp Toxicol.* 2018;37(7):742-751.
23. Pan M, Wang Z, Wang Y, Jiang X, Fan Y, Gong F, et al. Celastrol alleviated acute kidney injury by inhibition of ferroptosis through Nrf2/GPX4 pathway. *Biomed Pharmacother.* 2023;166:115333.
24. El-Sayed EM, Abd-Allah AR, Mansour AM, El-Arabey AA. Thymol and carvacrol prevent cisplatin-induced nephrotoxicity by abrogation of oxidative stress, inflammation, and apoptosis in rats. *J Biochem Mol Toxicol.* 2015;29(4):165-172.
25. Ucar F, Taslipinar MY, Alp BF, Aydin I, Aydin FN, Agilli M, et al. The effects of N-acetylcysteine and ozone therapy on oxidative stress and inflammation in acetaminophen-induced nephrotoxicity model. *Ren Fail.* 2013;35(5):640-647.
26. Gujral JS, Knight TR, Farhood A, Bajt ML, Jaeschke H. Mode of cell death after acetaminophen overdose in mice: apoptosis or oncotic necrosis? *Toxicol Sci.* 2002;67(2):322-328.
27. Hussain S, Alshahrani S, Siddiqui R, Khan A, Elhassan Taha MM, Ahmed RA, et al. Cinnamon Oil Alleviates Acetaminophen-Induced Uterine Toxicity in Rats by Abrogation of Oxidative Stress, Apoptosis, and Inflammation. *Plants (Basel).* 2023;12(12):2290.
28. Kobayashi K, Yasui M. Cellular and subcellular localization of aquaporins 1, 3, 8, and 9 in amniotic membranes during pregnancy in mice. *Cell Tissue Res.* 2010;342(2):307-316.
29. Verkman AS, Anderson MO, Papadopoulos MC. Aquaporins: important but elusive drug targets. *Nat Rev Drug Discov.* 2014;13(4):259-277.