

Anti-apoptotic, Anti-inflammatory, Anti-ulcer Effect of Silver Green Synthesis of *Boesenbergia Rotunda* Rhizome

Tola Abdulsattar Faraj*^{1,2}

Abstract

Background: Silver nanoparticles (SNPs) synthesized using the aqueous rhizome extract of *Boesenbergia rotunda* exhibit a wide range of biological activities and have traditionally been used in treating various ailments. The present study aimed to evaluate the gastroprotective effects of biosynthesized SNPs against ethanol-induced acute gastric mucosal injury in rats.

Methods: SNPs were synthesized and characterized using X-ray diffraction (XRD), UV–Vis spectroscopy, and transmission electron microscopy (TEM).

Result: Alleviated ethanol-induced gastric lesions, as evidenced by a reduced ulcer index. Ethanol-induced gastric damage was associated with decreased mucus production, lowered gastric pH, and increased ulcerated areas, edema, and inflammatory cell infiltration in the submucosa. Administration of SNPs markedly increased the activities of superoxide dismutase (SOD) and catalase (CAT), and elevated prostaglandin E2 (PGE2) levels, while significantly reducing malondialdehyde (MDA) concentrations in gastric tissue homogenates. SNPs also prevented oxidative stress by inhibiting lipid peroxidation. Furthermore, SNP treatment enhanced periodic acid–Schiff (PAS) staining of the gastric mucosa, upregulated HSP-70 protein expression, and downregulated Bax protein levels. SNPs also modulated inflammatory cytokines by increasing IL-10 and reducing TNF- α and IL-6 levels. Acute toxicity testing at a high dose (500 mg/kg) showed no toxicological symptoms in rats.

Conclusion: The present study demonstrates that *Boesenbergia rotunda*-derived silver nanoparticles exert significant gastroprotective effects, likely due to their antioxidant properties, stimulation of gastric secretions, enhancement of endogenous antioxidant enzymes (SOD, CAT, PGE2), suppression of lipid peroxidation, upregulation of HSP-70, downregulation of Bax, and modulation of inflammatory cytokines.

Keywords: Bax, *Boesenbergia rotunda*, Histology, HSP 70, Silver nanoparticle, Stomach ulcer.

Introduction

Peptic ulcer disease is a common gastrointestinal disorder associated with increased oxidative stress, inflammation, and disruption of the gastric epithelial barrier. These conditions make the mucosa more vulnerable to injury from various damaging factors. Several endogenous and exogenous agents can contribute to ulcer formation,

including smoking, use of nonsteroidal anti-inflammatory drugs (NSAIDs), alcohol consumption, *Helicobacter pylori* infection (1), excessive secretion of hydrochloric acid and pepsin, leukotrienes, bile reflux, and reactive oxygen species (ROS) (2, 3).

Nanotechnology is a rapidly expanding field with broad applications across science

1: Department of Physiology and Microbiology, College of Medicine, Hawler Medical University, Erbil 44001, Kurdistan Region, Iraq.

2: Department of Medical Analysis, Faculty of Applied Science, Tishk International University, Erbil 44001, Kurdistan Region, Iraq.

*Corresponding author: Tola Abdulsattar Faraj; Tel: +96 47509988344; E-mail: tola.faraj@tiu.edu.iq.

Received: 23 Feb, 2025; Accepted: 16 Jun, 2025

and technology, involving materials with at least one dimension at the nanometer scale (<100 nm). It has transformed numerous industrial sectors, such as electronics and biomedicine (4). In medicine, nanotechnology, referred to as nanomedicine, has opened new frontiers in healthcare by improving the physical, chemical, and biological properties of therapeutic agents at the nanoscale (5). Nano-medicine was mentioned in the request of nanotechnology for realizing breakthroughs in health care besides refining physical, chemical, besides biological possessions constituents nanometer scale (5). Among metallic nanoparticles, silver nanoparticles (SNPs) are recognized for their preventive and protective biological roles, including their ability to inhibit microbial growth and promote tissue repair (6).

Recently, metal-based nanoparticle formulations have gained attention for their therapeutic potential, demonstrating anti-ulcer (7), anti-*H. pylori* (8), anti-inflammatory (7, 9), antimicrobial (10), wound healing (6), antitumor (11) effects.

The gastric mucosa possesses several endogenous defense mechanisms that protect against injury, including mucus secretion, bicarbonate production, regulation of mucosal blood flow, antioxidant enzyme activity, surface-active phospholipids, and rapid epithelial regeneration (12). When these protective mechanisms fail, gastric ulceration may result, leading to severe complications such as bleeding or perforation. Although various medications, including proton pump inhibitors, anticholinergics, antacids, H₂-receptor antagonists, mucosal protectants, and antibiotics, are available to treat gastric ulcers, they can cause undesirable side effects and are not always effective in preventing recurrence (13, 14). Therefore, there is a continued need for safe and effective anti-ulcer agents.

Therefore, there is a continued need for safe and effective anti-ulcer agents (9, 12, 15). Ethanol exposure leads to the overproduction of reactive oxygen species such as superoxide

anions and hydroxyl radicals, resulting in lipid peroxidation and damage to the gastric epithelium (16, 17). The present study aimed to synthesize stable silver nanoparticles (AgNPs) using the aqueous rhizome extract of *Boesenbergia rotunda* as a reducing agent and to investigate their gastroprotective effects in a rat model of ethanol-induced gastric ulceration.

Materials and Methods

Chemicals and Reagents

All reagents and chemicals were of analytical grade. Silver nitrate (AgNO₃) was purchased from Merck (Germany). *Boesenbergia rotunda* rhizomes and Arabic gum were obtained from the local market. Omeprazole was purchased from the pharmacy (Gastuf 20, Geneda Pharma, India). All other chemicals, including carboxymethyl cellulose (CMC), were obtained from Sigma-Aldrich (St. Louis, MO, USA). Omeprazole was dissolved in 0.5% CMC and administered orally to rats at a dose of 20 mg/kg (5 mL/kg), as described in previous studies (9).

Preparation of Rhizome Extract

Fresh *B. rotunda* rhizomes were collected and authenticated by the Herbarium of Microbiology, Salahaddin University, Erbil (voucher No. ERB 42159). The rhizomes were thoroughly washed with tap and double-distilled water to remove impurities, then air-dried under shade at room temperature for 14 days. The dried rhizomes were cut into small pieces and ground into a fine powder using an electric grinder.

A total of 100 g of powdered rhizome was soaked in 500 mL of distilled water for three days with intermittent stirring every two hours. The mixture was filtered first through muslin cloth and then through Whatman No. 1 filter paper. The filtrate was concentrated using a rotary evaporator and stored at 4 °C until use. To prepare the reducing solution, 0.15 g of Arabic gum was dissolved in 50 mL of distilled water and heated at 70 °C in a 100 mL Pyrex beaker. The *B. rotunda* extract was then added gradually to this solution under continuous stirring to obtain the final reaction mixture.

Formation of silver nanoparticles

A mixture of *Boesenbergia rotunda* extract and Arabic gum was prepared in a 250 mL conical flask and heated at 65–75 °C. The pH of the mixture was adjusted to 7.5. Subsequently, 50 mL of 1 mM silver nitrate (AgNO₃) solution was added dropwise under continuous stirring. A color change from colorless to bright yellow indicated the formation of silver nanoparticles. The reaction was allowed to proceed for 20 minutes, after which the heating was stopped and stirring was continued until the temperature decreased to 25 °C. The resulting yellow colloidal solution remained stable and uniform for up to three months (7).

Experimental Animals and Study Design

Acute toxicity study

To ensure the safety of the synthesized silver nanoparticles (SNPs), an acute toxicity study was conducted following OECD (2002) guidelines. Adult albino Wistar rats of both sexes were obtained from the Animal House Unit, Cihan University, Erbil. The rats were provided with standard pellet feed and water ad libitum throughout the experiment.

A total of 36 rats were randomly divided into three groups (n = 12 per group):

Group 1 (Control): Received 0.5% carboxymethyl cellulose (CMC).

Group 2 (Low dose): Received *B. rotunda* extract at 2500 mg/kg.

Group 3 (High dose): Received *B. rotunda* extract at 5000 mg/kg.

Dose selection was based on previously published toxicity data (18). Food was withheld overnight before dosing, but water was provided. After treatment, rats were observed continuously for the first 30 minutes, intermittently during the first 24 hours, and daily for 14 days for signs of toxicity or mortality.

At the end of the study, food was withdrawn for 24 hours, and the animals were anesthetized with ketamine (100 mg/kg) and xylazine (3 mg/kg). Blood samples were collected via intracardiac puncture for biochemical analyses of liver and kidney function. The liver and kidneys were excised for histopathological

examination using hematoxylin and eosin (H&E) staining to detect any structural or cellular abnormalities (19, 20).

Experimental animals for gastric ulcer induction

Adult albino Wistar rats, weighing 185–215 g, were obtained from the Experimental Animal Facility, College of Science, Cihan University, Erbil (Ethics Approval No. Biology/23/07/2023/MAA). All experimental procedures adhered to the guidelines outlined by the National Institutes of Health (NIH, USA) for the care and use of laboratory animals (7).

Animals were housed individually in stainless-steel cages with wire-mesh bottoms to prevent coprophagy and were acclimatized for 7 days before experimentation. Rats were maintained on standard pellet feed with free access to water. The rats were randomly divided into five groups (n = 6 per group):

Group 1: Normal control, received 0.5% CMC (5 mL/kg).

Group 2: Ulcer control, received 0.5% CMC (5 mL/kg).

Group 3: Positive control, treated with omeprazole (20 mg/kg).

Group 4: Treated with SNPs (175 ppm, p.o.).

Group 5: Treated with SNPs (350 ppm, p.o.).

One hour after the respective treatments, all groups except the normal control received absolute ethanol (5 mL/kg, orally) to induce gastric ulcers. After another 60 minutes, all rats were anesthetized with ketamine/xylazine and euthanized. Stomachs were immediately excised for macroscopic and biochemical analyses (7).

Macroscopic Evaluation of Gastric Lesions

Each excised stomach was opened along the greater curvature, rinsed gently with cold phosphate-buffered saline (PBS), and examined for visible mucosal injury using a stereomicroscope. Linear hemorrhagic lesions were measured using a planimeter under a dissecting microscope (1.8× magnification). The ulcer area (UA) in mm² was calculated using the following formula:

$$UA \text{ (mm}^2\text{)} = (\text{Total number of small squares}) \times 4 \times 1.8$$

$$UA \text{ (mm}^2\text{)} = (\text{Total number of small squares}) \times 4 \times 1.8$$

The percentage of ulcer inhibition was determined as:

Inhibition ratio (I%) = (UA controller – UA cured / UA control) X 100 (9, 15, 21).

Measurement of Gastric Juice pH and Mucus Content

Gastric juice samples were centrifuged, and the pH of the supernatant was measured using a pH meter. Total acidity was determined by titration with 0.1 N NaOH and expressed in mEq/L (19). For mucus determination, the gastric mucosa was gently scraped using a clean glass slide, and the mucus was weighed on an electronic precision balance (19, 22).

Preparation of Gastric Mucosal Homogenate

Sections of gastric mucosa were rinsed in ice-cold PBS and homogenized (10% w/v) in PBS containing a mammalian protease inhibitor cocktail. The homogenate was centrifuged at 1000 g for 10 minutes at 4°C. The resulting supernatant was used for biochemical assays, including measurements of superoxide dismutase (SOD), catalase (CAT), prostaglandin E₂ (PGE₂), and malondialdehyde (MDA), according to the manufacturer's protocols (Cayman Chemical, USA) (19).

Assessment of Antioxidant Enzyme Activity and Lipid Peroxidation

SOD, CAT, and PGE₂ levels were quantified using commercial assay kits (Cayman Chemical, Ann Arbor, USA), following the manufacturer's instructions (12, 19). MDA levels, an indicator of lipid peroxidation, were measured using standard colorimetric assay kits (9).

Histology valuation

Glandular stomach sections (~2 cm) were fixed in 10% buffered formalin for 24 hours at 25 °C, dehydrated through graded ethanol, cleared with xylene, and embedded in paraffin wax

using a tissue processor. Sections (5 µm thick) were stained with hematoxylin and eosin (H&E) and examined microscopically for pathological changes (15).

Periodic Acid-Schiff (PAS) Staining

For the evaluation of mucus secretion and glycoprotein distribution in the gastric mucosa, 5 µm paraffin sections were stained with PAS reagent according to standard procedures (19, 22).

Periodic acid Schiff (PAS) stains

Appraise mucus discharge stomach glandular epithelia, sections 5 µm thick were stain by PAS to visualize stomach secretion beside alterations together acidic besides basic glycoproteins succeeding production training technique (19).

Immunohistochemical Analysis

Paraffin-embedded gastric sections (5 µm) were processed using the ARK™ Animal Research Kit to detect HSP-70 (1:100) and Bax (1:50) protein expression. Both antibodies were purchased from Santa Cruz Biotechnology (7).

Measurement of Inflammatory Cytokines

Levels of TNF-α, IL-6, and IL-10 in gastric homogenates were determined using ELISA kits (Elabscience, Wuhan, China) following the manufacturer's instructions. Cytokine concentrations were calculated using recombinant standards (12, 15).

Statistical analysis

All data were analyzed using GraphPad Prism version 9.0. Results were expressed as mean ± SEM. Statistical significance was determined using one-way ANOVA followed by Student's t-test, with p < 0.05 considered significant.

Results

Toxicity of B. rotunda Silver Nanoparticles

Rats treated with B. rotunda-derived silver nanoparticles (SNPs) at dosages of 2500 and 5000 mg/kg showed no signs of toxicity throughout the 14-day observation period. All animals remained active and healthy, with no behavioral or physiological abnormalities.

There were no significant changes in body weight, food consumption, or general activity among the groups. No mortality was recorded during the experiment.

Histological examination of the liver and kidney tissues revealed no structural

abnormalities or lesions in the SNP-treated groups compared with the normal controls (Fig. 1). Similarly, biochemical analyses of blood parameters showed no statistically significant differences ($p > 0.05$) between experimental and control rats (Tables 1 and 2).

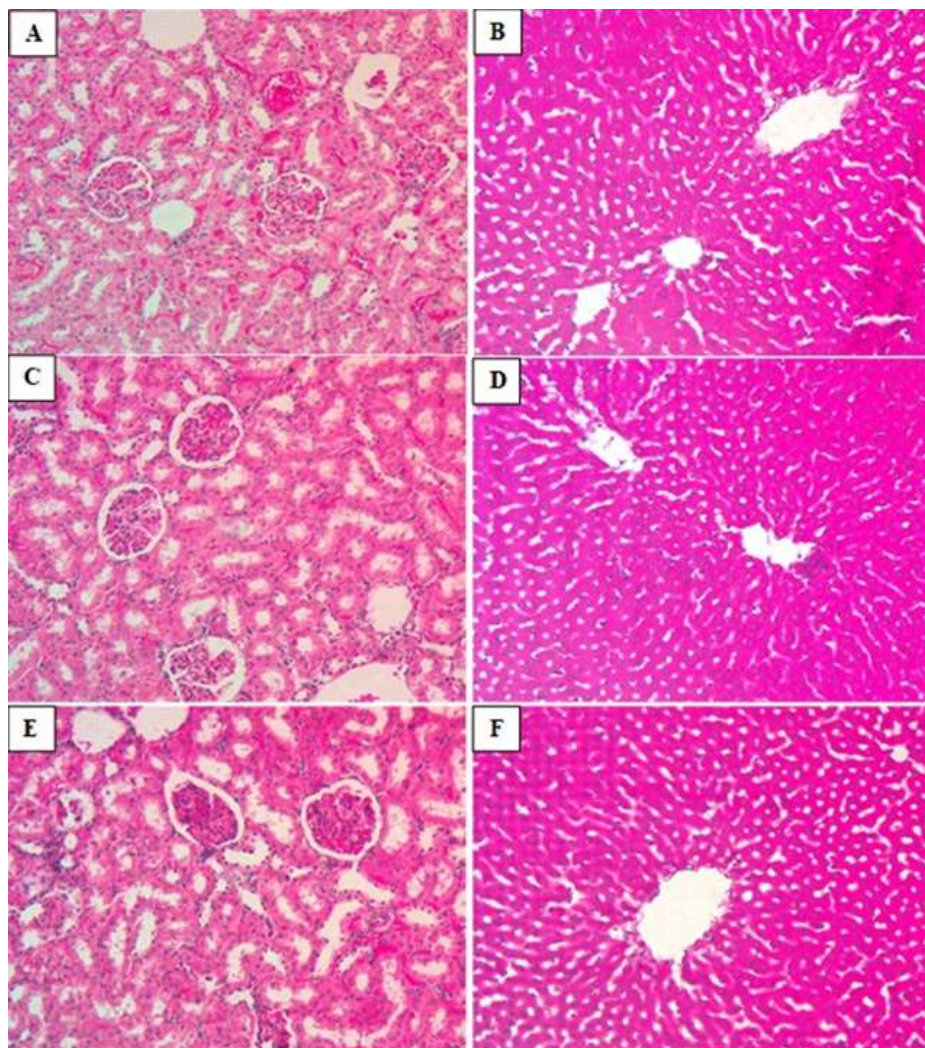


Fig. 1. Microscopic views kidney (first column) and liver (second column) of rat tissues in acute toxicity test. A: control rats treated with 1% CMC; B: rats treated with 2500 mg/kg *B. rotunda* SNPs; C: rats treated with 5000 mg/kg *B. rotunda* SNPs. Tissue structures were comparable across groups (H&E, 20 \times).

Table 1. Impact of *B. rotunda* SNP on blood (liver) parameters of rats in toxicity experiment.

Groups	Albumin (g/L)	T. bilirubin (mmol/L)	ALP (IU/L)	ALT IU/L)	C. glutamyl transferase (IU/L)
G1	33.6 \pm 1.7	<2	165.4 \pm 3.2	81.2 \pm 9.3	0.02 \pm 0.4
G2	34.4 \pm 2.1	<2	163. 11 \pm 2,3	78.72 \pm 7.6	0.08 \pm 0.2
G3	32.3 \pm 2.7	<2	162. 5 \pm 5.3	79.33 \pm 8.7	0.08 \pm 0.4

Values are presented as mean \pm SEM (n = 6). No significant differences were observed at $p < 0.05$. G1: control (1% CMC); G2: 2500 mg/kg SNP; G3: 5000 mg/kg SNP.

Table 2. Effect of *B. rotunda* SNPs on renal function parameters in rats.

Groups	Sodium (mmol/L)	Potassium (mmol/L)	Chloride (mmol/L)	CO2 (mmol/L)	Anion gap (mmol/L)	Urea (mmol/L)	Creatinine (mmol/L)
G1	145.3 + 5.3	4.7 + 1.5	105.1 ± 4.2	36.7 ± 2.3	14.4 ± 2.1	5.2 + 1.1	32.3. + 31)
G2	148.4 ± 4.2	5.2 + 1.6	106.4. ± 2.3	38. 2 + 1.6	15.8 ± 0.2	6.3 + 1.5	31.6 + 33
G3	147.3 ± 4.7	5.1 + 2.2	104.5 + 6.5	35.5 ± 5.2	14.5 ± 0.4	6.7 + 3.3	30.7 + 42

Values are presented as mean ± SEM (n = 6). Differences were non-significant at p < 0.05.

Effect of *B. rotunda* silver nanoparticle on stomach mucus contented

Investigational animals nourished *B. rotunda*

SNP exhibited a considerable rise in the mucus excretion of gastric once related to ulcer control gathering (Table 3).

Table 3. Influence of *B. rotunda* SNP on mucus mass, stomach's pH, ulceration region, as well as reserve proportion ulcer's part rodent's stomach.

Animal groups	Pre-feeding (5mL/kg)	Mucus (g)	pH	Ulcer area (mm) ²	Inhibition (%)
G1	Normal control (0.5% CMC)	2.22±0.09 ^a	6.54±0.07 ^a	0.00	0
G2	Ulcer control (0.5% CMC + Ethanol)	0.75±0.02 ^b	2.96±0.10 ^b	783±4.26 ^a	0
G3	Omeprazole (20 mg/kg)	1.94±0.01 ^a	5.81±0.02 ^a	103±3.25 ^b	86.8 ^a
G4	SNP (175 ppm)	1.59±0.01 ^a	5.22±0.01 ^a	158±1.23 ^b	79.8 ^b
G5	SNP (350 ppm)	1.78±0.004 ^a	5.37±0.03 ^a	138±0.70 ^b	82.3 ^a

Values are mean ± SD (n = 6). Different superscripts indicate significant differences at p < 0.05 (Tukey's HSD).

Effect of *B. rotunda* SNP on pH of the stomach

Experimental rats nourished *B. rotunda* SNP previously management with ethanol meaningfully increased gastric pH-related ulcer control collection (Table 3).

Impact of *B. rotunda* SNP on histopathology assessment of ethanol-convicted stomach ulcer rats

Histopathological Findings

Hematoxylin & Eosin (H&E) Staining

Ulcer control rats displayed severe epithelial injury, necrosis, edema, and marked leukocyte infiltration into the submucosal layer. Rats treated with *B. rotunda* SNPs exhibited markedly improved mucosal integrity with reduced ulceration and minimal inflammation (Fig. 2).

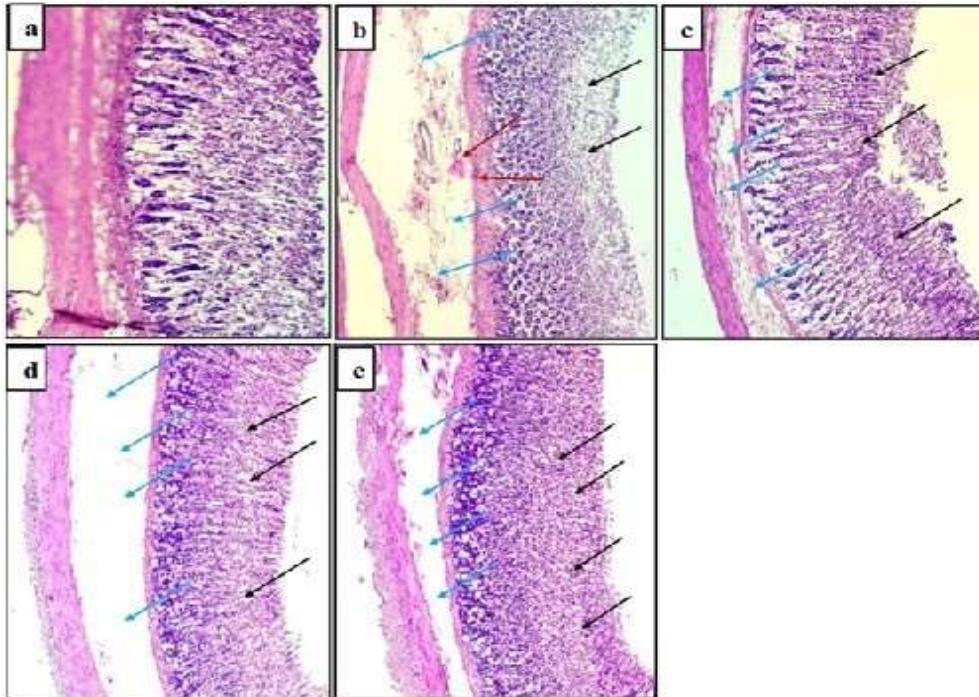


Fig. 2. Effect of *B. rotunda* SNPs on histopathology of gastric mucosa in ethanol-induced ulceration. a. Normal control; b. Ulcer control showing necrosis (black arrows), edema (blue arrows), and neutrophil infiltration (red arrows); c. Omeprazole-treated; d–e. SNP-treated groups showing reduced mucosal damage.

Periodic Acid-Schiff (PAS) Staining

B. rotunda SNP-treated groups showed enhanced PAS staining intensity, indicating

increased glycoprotein content and mucus secretion in the gastric mucosa compared with ulcer control rats (Fig. 3).

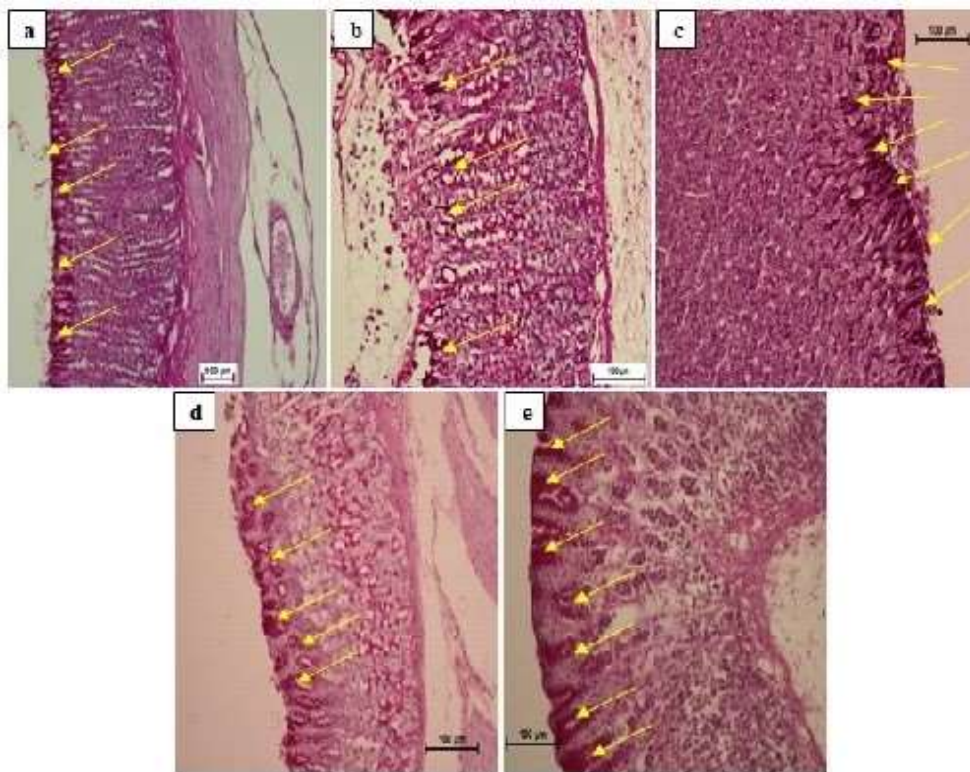


Fig. 3. PAS staining of gastric mucosa showing magenta coloration indicating mucin presence. Ulcer control (b) showed weak PAS staining compared with the SNP-treated (d–e) and omeprazole-treated (c) groups.

Bax Expression

The ulcer control group exhibited strong Bax expression, indicating apoptotic activation. In

contrast, *B. rotunda* SNP-treated rats showed downregulation of Bax expression similar to the omeprazole group (Fig. 4).

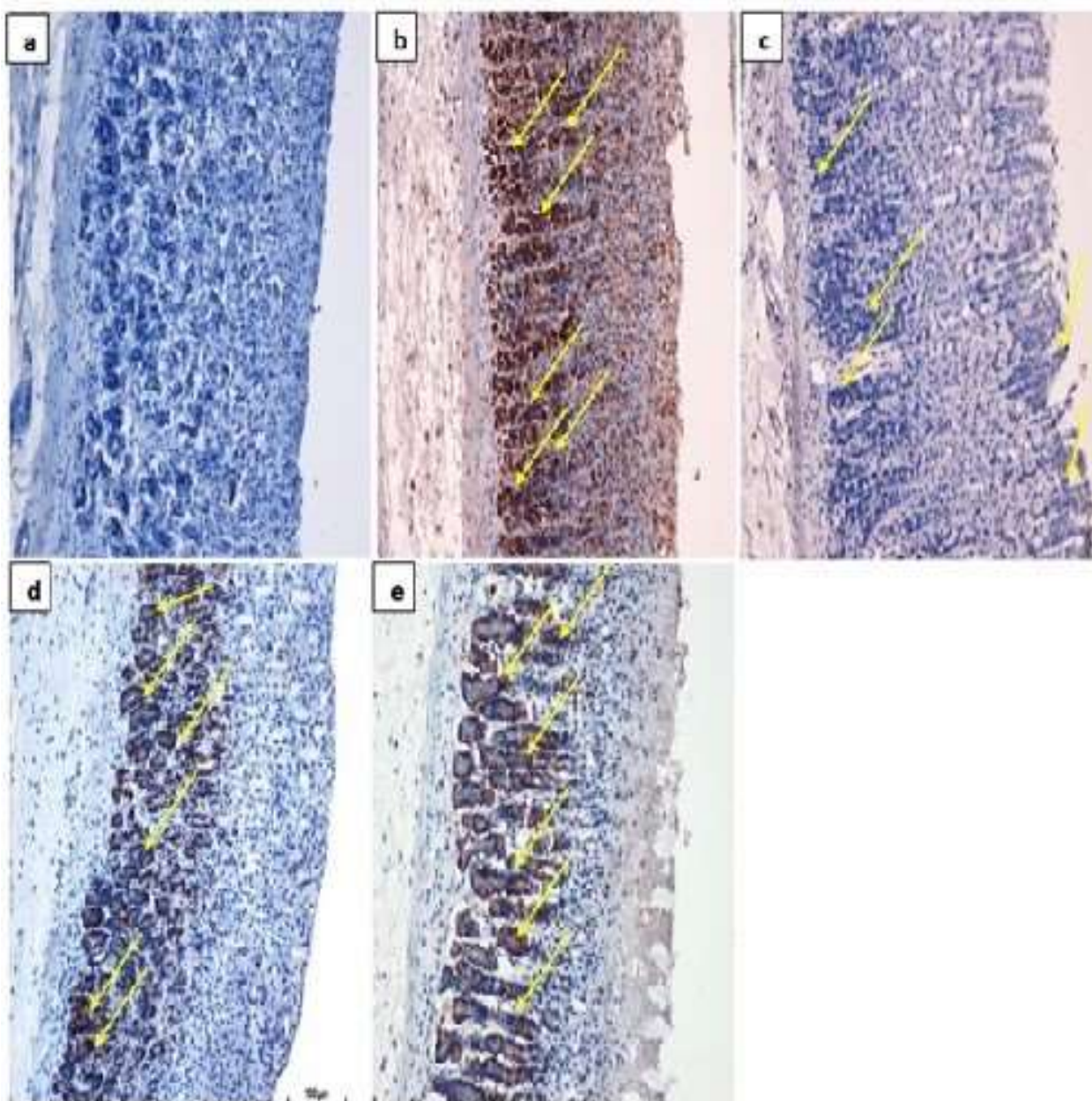


Fig. 4. Effects of the SNP of *B. rotunda* rhizome on the appearance of Bax protein stomach epithelium of alcohol-convinced gastric injury rats. a. Normal group obtainable deficiency of countenance. b. Ulcer control group showed up-regulation of Bax protein (yellow arrows) in the stomach epithelia. c. The omeprazole group showed down-regulation of Bax protein (yellow arrows) in the gastric epithelia. d. & e. Investigational groups revealed the downregulation of Bax protein (yellow arrows) in the stomach epithelia.

HSP-70 Expression

Ulcer control rats showed downregulation of HSP-70 protein, whereas SNP-treated rats

demonstrated significant upregulation of HSP-70 expression in gastric epithelial cells, indicating enhanced cytoprotection (Fig. 5).

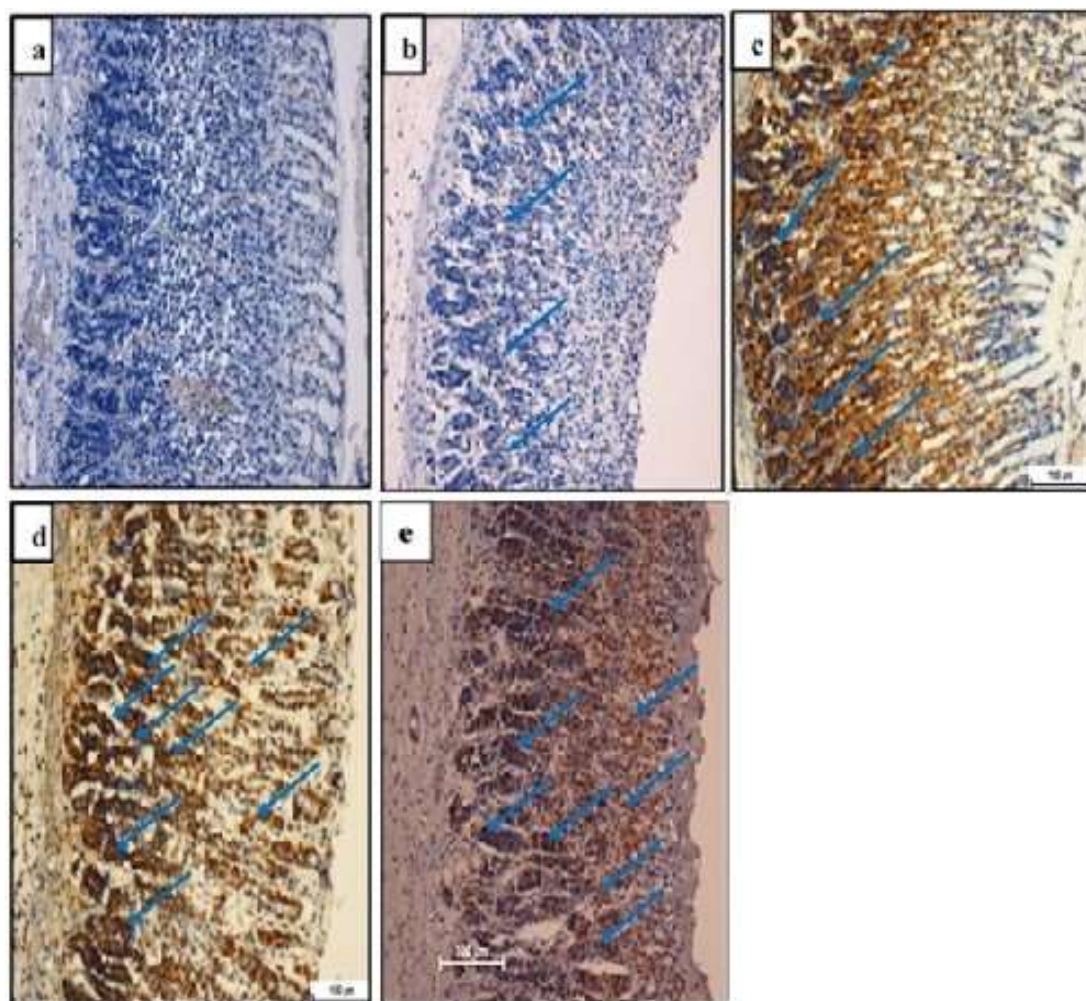


Fig. 5. Effects of *B. rotunda* SNP rhizome on appearance HSP-70 protein gastric epithelia alcohol-convicted stomach injury rodents. a. Normal group presented an absence of manifestation. b. Ulcer control assemblage presented down-regulation HSP-70 protein (blue arrows) in the stomach epithelium. c. Omeprazole collection revealed the up-regulation of HSP-70 protein (blue arrows) in the stomach's mucosa. d. & e. Investigational groups showed up-regulation of HSP-70 protein (blue arrows) in the gastric mucosa.

Antioxidant Enzyme Activities and Lipid Peroxidation

Ethanol-induced ulceration significantly reduced SOD, CAT, and PGE₂ levels while

increasing MDA levels. Pretreatment with *B. rotunda* SNPs restored antioxidant enzyme activities and decreased MDA levels close to normal (Table 4).

Table 4. Effect of SNP on antioxidant enzymes and lipid peroxidation in stomach tissue homogenate.

Animal's group	SOD (U/g protein)	CAT (nM/min/mL)	PGE2 (ng/mg protein)	MDA (μM/g protein)
1. Vehicle	474.7±1.5 ^a	127±0.9 ^a	457.8±1.5 ^a	205.7±1.8 ^a
2. Ulcer control	171.5±1.7 ^b	71.5±1.1 ^b	72.3±1.3 ^b	230.8±1.2 ^b
3. Omeprazole	393.8±1.5 ^c	130±1.0 ^a	301.2±1.1 ^c	108.2±1.6 ^c
4. silver nanoparticle 175 ppm	365.2±1.5 ^c	110.3±2.6 ^a	272.8±1.6 ^c	104.5±1.4 ^c
5. silver nanoparticle 350 ppm	384.7±1.4 ^c	132.5±1.3 ^a	297±2.2 ^c	107.3±1.6 ^c

Values are mean ± SEM (n = 6). Different superscripts indicate significant differences (p < 0.05, Bonferroni post hoc test).

Inflammatory Cytokines

Ethanol administration significantly elevated pro-inflammatory TNF- α and IL-6 levels while reducing anti-inflammatory IL-10 levels. Treatment with *B. rotunda* SNPs significantly

($p < 0.05$) decreased TNF- α and IL-6 levels and increased IL-10 compared to the ulcer control group, particularly at the 350-ppm dose (Fig. 6).

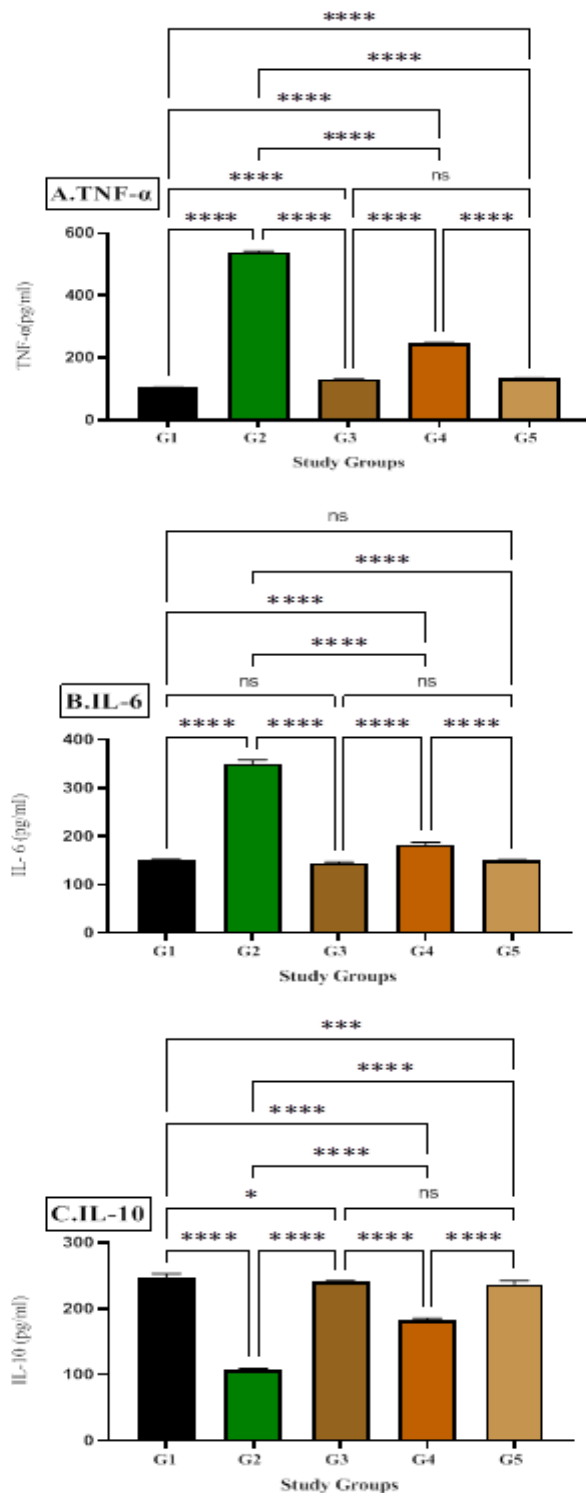


Fig. 6. Effects of *B. rotunda* SNPs on (A) TNF- α , (B) IL-6, and (C) IL-10 levels in ethanol-induced gastric ulcers. Values are expressed as mean \pm SEM (n = 6). ns: non-significant; * $p < 0.05$; *** $p < 0.001$; **** $p < 0.0001$.

Discussion

The acute toxicity study revealed no evidence of toxicity or mortality, indicating that silver nanoparticles (SNPs) are safe and non-toxic when administered orally at doses up to 5 g/kg. This observation aligns with previous studies utilizing SNPs synthesized from various medicinal plant extracts (15, 19, 21). It has been reported that anti-ulcer agents enhance the secretion of gastric mucus (7, 9, 15). In the present study, SNPs demonstrated significant anti-ulcer activity in rats, as evidenced by reduced ulcer index, increased gastric pH and mucus volume, and attenuation of submucosal edema and leukocyte infiltration (8, 23). These results are consistent with earlier findings on the gastroprotective and anti-ulcer effects of SNPs and herbal composites (7, 24, 25). Pretreatment with SNPs effectively suppressed gastric acidity and restored the integrity of the gastric mucosa in ethanol-treated rats. This gastroprotective effect may be attributed to the preservation of the gastric mucus barrier. The balance between gastroprotective mechanisms and gastric toxicity is crucial in the pathogenesis of acute inflammation, which is often associated with the release of pro-inflammatory cytokines (26). Ethanol-induced acute gastritis is characterized by massive neutrophil infiltration into the gastric mucosa (15, 27). In this study, SNP pretreatment markedly inhibited submucosal infiltration, suggesting that SNPs protect the gastric mucosa by mitigating ethanol-induced inflammatory responses.

Reactive oxygen species (ROS) and free radicals are key mediators of oxidative stress and tissue damage (28). In the current study, rats pretreated with SNPs exhibited preserved epithelial integrity, reduced submucosal edema, and minimal inflammatory cell infiltration compared with ulcer control animals. Histopathological evaluation revealed a pronounced reduction in hemorrhagic lesions and edema, along with limited leukocyte infiltration in the SNP-treated group. Periodic acid–Schiff (PAS) staining confirmed an increase in mucus

production in SNP-pretreated rats, supporting the hypothesis that the gastroprotective effects of SNPs are mediated through enhanced mucus secretion. These findings are consistent with earlier studies showing increased gastric mucus secretion following pretreatment with synthetic or natural compounds against necrotizing agents (7, 21).

ROS such as hydroxyl radicals and superoxide anions initiate lipid peroxidation, leading to cellular and epithelial damage. Malondialdehyde (MDA), a major byproduct of lipid peroxidation, serves as a reliable biomarker of oxidative stress (29, 30). Prostaglandin E₂ (PGE₂) plays an essential role in maintaining gastric mucosal integrity by stimulating mucus secretion and modulating local blood flow (31). Ethanol exposure markedly decreases mucosal PGE₂ levels, thereby contributing to gastric injury (32, 33). In this study, SNP administration significantly elevated mucosal PGE₂ levels, suggesting that the gastroprotective activity of SNPs may be partially mediated through the upregulation of PGE₂ synthesis.

Moreover, SNP treatment enhanced the activities of the antioxidant enzymes superoxide dismutase (SOD) and catalase (CAT), while simultaneously reducing MDA levels. These observations are consistent with previous reports demonstrating improved antioxidant enzyme activity in SNP-treated animals compared with ethanol-treated controls (7, 21). The reduction in MDA levels observed here is also supported by findings from studies employing various plant-derived antioxidants (15, 21, 34). Since free radicals play a pivotal role in the pathogenesis of gastric ulcers, the antioxidant potential of SNPs likely contributes to their protective effect by scavenging ROS and restoring antioxidant balance (35).

Apoptotic pathways are also involved in ethanol-induced gastric mucosal damage. Bax, a pro-apoptotic member of the Bcl-2 family, regulates mitochondrial membrane permeability and facilitates cytochrome c

release (6, 19). Ethanol exposure promotes Bax overexpression and downregulates anti-apoptotic proteins such as Bcl-2, leading to increased apoptosis in gastric epithelial cells (7, 21). Conversely, heat shock protein 70 (HSP-70), an anti-apoptotic molecular chaperone, inhibits the Apaf-1/cytochrome c/caspase-9 apoptotic cascade by binding to Apaf-1 (7, 36). In this study, SNP pretreatment significantly downregulated Bax and upregulated HSP-70 expression in gastric tissues, suggesting that SNPs confer cytoprotection by suppressing apoptosis and stabilizing mitochondrial function.

HSP-70, a 70 kDa stress-inducible protein, plays a fundamental role in maintaining cellular homeostasis and protecting cells against various stressors such as toxins, oxidative agents, and heat shock (7, 21). Ethanol-induced oxidative stress can suppress HSP-70 expression, leading to cellular dysfunction and mucosal injury (15, 19, 37). Several studies have demonstrated that natural or synthetic compounds capable of inducing HSP-70 expression protect gastric mucosa from ethanol-induced lesions (19, 21). In agreement, our findings showed that SNP administration significantly upregulated HSP-70 expression, indicating that its gastroprotective effects may involve HSP-70-mediated stabilization of mitochondrial integrity and inhibition of stress-induced apoptosis.

Cytokines are crucial regulators of immune homeostasis, modulating immune cell activity and intercellular communication (38). Ethanol exposure significantly increased the levels of pro-inflammatory cytokines (TNF- α , IL-6) and decreased the anti-inflammatory cytokine (IL-10), indicating immune dysregulation. In contrast, pretreatment with *B. rotunda*-derived SNPs markedly downregulated TNF- α and IL-

6 while upregulating IL-10, thereby restoring immune balance (39).

To the best of our knowledge, this is the first study to report the gastroprotective effects of *B. rotunda*-mediated SNPs against ethanol-induced gastric ulcers in rats, as supported by histopathological, immunohistochemical, and biochemical analyses. Treatment with *B. rotunda* SNPs significantly enhanced the antioxidant defense system (CAT, SOD, and PGE₂), reduced lipid peroxidation (MDA), and modulated apoptotic and inflammatory markers (upregulation of HSP-70, downregulation of Bax, TNF- α , and IL-6, and elevation of IL-10). The observed bioactivity of *B. rotunda* SNPs can be attributed to their antioxidant and anti-inflammatory potential, likely mediated by the synergistic action of the plant's phytochemical constituents and the nanoscale properties of silver nanoparticles.

Financial support

Self-funded.

Conflicts of Interest

The authors declare that there is no conflict of interest regarding the publication of this paper.

Acknowledgment

The author is thankful to the staffs of the Department of Medical Analysis, Faculty of Applied Science, Tishk International University for their assistance in the practical part of this research.

Authors Contribution

Tola Abdulsattar Faraj designed and drafted the article, participated in data collection, project performance, and manuscript writing. The final manuscript was read and approved by TAF.

References

- Jaiswal F, Rai A, Wal P, Wal A, Singh SP. Peptic ulcer: a review on etiology, pathogenesis and treatment. *Asian J Pharm Educ Res*. 2021;10(4):1-17.
- Gwaram NS, Musalam L, Ali HM, Abdulla MA, Shaker SA. Synthesis, spectral characterization and biological activity of Zn (II) complex with 2'-[1-(2-hydroxyphenyl)

- ethylidene] benzenesulfanohydrazide. Arab J Chem. 2016;9(2):S1197-S207.
3. Abd El Hady WE, Mohamed EA, Soliman OAE, El-Sabbagh HM. In vitro-in vivo evaluation of chitosan-PLGA nanoparticles for potentiated gastric retention and anti-ulcer activity of diosmin. Int J Nanomedicine. 2019;14:7191-7213.
 4. Al-Dahmash ND, Al-Ansari MM, Alotibi FO, Singh AR. Frankincense, an aromatic medicinal exudate of *Boswellia carterii* used to mediate silver nanoparticle synthesis: Evaluation of bacterial molecular inhibition and its pathway. J Drug Del Sci Tech. 2021;61(12):102337.
 5. El-Batal AI, Ahmed SF. Therapeutic effect of Aloe vera and silver nanoparticles on acid-induced oral ulcer in gamma-irradiated mice. Braz Oral Res. 2018;32:e004.
 6. Osman Mahmud S, Hamad Shareef S, Jabbar AAJ, Hassan RR, Jalal HK, Abdulla MA. Green Synthesis of Silver Nanoparticles from Aqueous Extract of *Tinospora crispa* Stems Accelerate Wound Healing in Rats. Int J Low Extrem Wounds. 2022;15347346221133627.
 7. Ibrahim IAA, Hussein AI, Muter MS, Mohammed AT, Al-Medhtiy MH, Shareef SH, et al. Effect of nano silver on gastroprotective activity against ethanol-induced stomach ulcer in rats. Biomed Pharmacother. 2022;154:113550.
 8. Al-Bahrani RM, Radif HM, Albaayit SFA. Evaluation of potent silver nanoparticles production from *Agaricus bisporus* against *Helicobacter pylori*. Pak J Agri Sci. 2020;57(4):1197-201.
 9. Shareef SH, Hadi IN, Badeea MA, Abdulla MA. Green synthesis of gold nanoparticles using *Zingiber officinale* rhizomes aqueous extract and its gastroprotective activity against ethanol-produced stomach ulcer in rodents. Cihan Uni-Erbil Sci J. 2022;6(2):68-75.
 10. Senthilkumar P, Rashmitha S, Veera P, Ignatious CV, SaiPriya C, Samrot AV. Antibacterial activity of neem extract and its green synthesized silver nanoparticles against *Pseudomonas aeruginosa*. J Pure Appl Microbiol. 2018;12(2):969-74.
 11. Hashemi SF, Tasharrofi N, Saber MM. Green synthesis of silver nanoparticles using *Teucrium polium* leaf extract and assessment of their antitumor effects against MNK45 human gastric cancer cell line. J Mol struct. 2020;1208:127889.
 12. Formiga RO, Alves Júnior EB, Vasconcelos RC, Araújo AA, de Carvalho TG, de Araújo Junior RF, et al. Effect of p-cymene and rosmarinic acid on gastric ulcer healing - Involvement of multiple endogenous curative mechanisms. Phytomedicine. 2021;86:153497.
 13. Kaur D, Rana A, Sharma N, Kumar S. Herbal drugs with anti ulcer activity. Journal of applied pharmaceutical science. 2012;02(03):160-5.
 14. Beiranvand M. A review of the most common in vivo models of stomach ulcers and natural and synthetic anti-ulcer compounds: a comparative systematic study. Phytomed Plus. 2022;2(2):100264.
 15. Alhejaily TB, Alamri ZZ, ALaryani FS, Shareef SH. The Potential Gastro-Protective Effect of Qaysum (*Achillea fragrantissima*) Against Ethanol-Induced Gastric Ulcer in Wistar Albino Rats. Cureus. 2023;15(10):e47696.
 16. Yang HJ, Kim MJ, Kwon DY, Kang ES, Kang S, Park S. Gastroprotective actions of *Taraxacum coreanum* Nakai water extracts in ethanol-induced rat models of acute and chronic gastritis. J Ethnopharmacol. 2017;208:84-93.
 17. Basatinya AM, Sajedianfard J, Nazifi S, Hosseinzadeh S, Kamrani Mehni M, et al. Effects of ethanolic extracts of *Quercus*, *Cirsium vulgare*, and *Falcaria vulgaris* on gastric ulcer, antioxidant and inflammatory indices, and gene expression in rats. Physiol Rep. 2021;9(16):e14954.
 18. Shareef SH, Alamri ZZ, Al-Rashdi AS, Ismael LN, Agha NFS, Abdulla MA. Hepatoprotective Effect of Typhonium Flagelliforme against Thioacetamide Produced Liver Cirrhosis in Rats. Ann Clin Case Stud. 2023;5(1075):022-028
 19. Shareef SH. In Vivo Gastroprotective Upshots of the Novel Schiff Base CdCl₂ (C14H₂₁N₃O₂) Compound by Bax/HSP-70

- Signaling and Inflammatory Cytokines. *Cureus*. 2024;16(12): e75963.
20. Shareef SH, Juma AS, Agha DN, Alzaharani AR, Ibrahim IAA, Abdulla MA. Hepatoprotective effect of alpinetin on thioacetamide-induced liver fibrosis in sprague dawley rat. *Appl Sci*. 2023;13(9):5243.
21. Shareef SH, Ahmed KA, Faraj TA, Kheder RK, Aziz PY, Sulaiman JA, et al. In vivo antiulcerogenic effect of morinda elliptica stem extract against ethanol-induced gastric ulcer in rat. *J Asian Nat Prod Res*. 2025:1-19.
22. Ahmed K, Shareef S, Faraj T, Abdulla M, Najmaldin S, Agha N, Kheder RK. Chemoprotective effect of arbutin on azoxymethane-induced aberrant crypt foci in rat colon via modulation of PCNA/Bax protein. *Braz J Med Biol Res*. 2024;57:e13306.
23. Hemmati S, Zamenian T, Delsooz N, Zangeneh A, Mahdi Zangeneh M. Preparation and synthesis a new chemotherapeutic drug of silver nanoparticle-chitosan composite; Chemical characterization and analysis of their antioxidant, cytotoxicity, and anti-acute myeloid leukemia effects in comparison to Daunorubicin in a leukemic mouse model. *Appl organomet chem*. 2020;34(2):e5274.
24. Abdallah MT, Al-Ezzy RM, Khalaf HM. Biosynthesis And Antibacterial Effect Of Silver Nanoparticle Loaded On Glycyrrhiza Glabra. *Asian J Adv Res*. 2020;3(1):495-502.
25. El-Desouky N, Shoueir KR, El-Mehasseb I, El-Kemary M. Bio-inspired green manufacturing of plasmonic silver nanoparticles/Degussa using Banana Waste Peduncles: Photocatalytic, antimicrobial, and cytotoxicity evaluation. *J Mate Res Technol*. 2021;10:671-86.
26. Reddy N, Li H, Hou T, Bethu M, Ren Z, Zhang Z. Phytosynthesis of silver nanoparticles using *Perilla frutescens* leaf extract: characterization and evaluation of antibacterial, antioxidant, and anticancer activities. *Int J Nanomedicine*. 2021;16:15.
27. Saremi K, Rad SK, Shahnavaz Z, Majid NBA. Study of antidiabetic activity of two novel Schiff base derived dibromo and dichloro substituted compounds in streptozotocin-nicotinamide-induced diabetic rats: pilot study. *Braz J Pharm Sci*. 2023;59:e21159.
28. El-Aassar M, Ibrahim OM, Fouda MM, El-Beheri NG, Agwa MM. Wound healing of nanofiber comprising Polygalacturonic/Hyaluronic acid embedded silver nanoparticles: In-vitro and in-vivo studies. *Carbohydr Polym*. 2020;238:116175.
29. Hu J, Luo J, Zhang M, Wu J, Zhang Y, Kong H, et al. Protective Effects of Radix Sophorae Flavescentis Carbonisata-Based Carbon Dots Against Ethanol-Induced Acute Gastric Ulcer in Rats: Anti-Inflammatory and Antioxidant Activities. *Int J Nanomedicine*. 2021;16:2461.
30. Ibrahim MM, Osman A, Helal AI, Faheem AM, El-Kattan MA, Ibrahim I, Elmetwally AA, Abubakr S, Badawy AM, Hussin E. Celastrol Mitigates Acetaminophen-Induced Nephrotoxicity in Rats via Targeting Renal Oxidative Stress, Inflammation, Apoptosis with Enhancement in Aquaporin 1 Level. *Rep Biochem Mol Biol*. 2024;13(2):204-217.
31. Ren S, Wei Y, Wang R, Wei S, Wen J, Yang T, et al. Rutaecarpine Ameliorates Ethanol-Induced Gastric Mucosal Injury in Mice by Modulating Genes Related to Inflammation, Oxidative Stress and Apoptosis. *Front Pharmacol*. 2020;11:600295.
32. Li Q, Hu X, Xuan Y, Ying J, Fei Y, Rong J, et al. Kaempferol protects ethanol-induced gastric ulcers in mice via pro-inflammatory cytokines and NO. *Acta biochimica et biophys Sin*. 2018;50(3):246-53.
33. de Veras BO, da Silva MV, Cabral Ribeiro PP. Tannic acid is a gastroprotective that regulates inflammation and oxidative stress. *Food Chem Toxicol*. 2021;156:112482.
34. Zhou D, Yang Q, Tian T, Chang Y, Li Y, Duan LR, et al. Gastroprotective effect of gallic acid against ethanol-induced gastric ulcer in rats: Involvement of the Nrf2/HO-1 signaling and anti-apoptosis role. *Biomed Pharmacother*. 2020;126:110075.
35. Armah FA, Henneh IT, Alake J, Ahlidja W, Amoani B, Ofori EG, et al. *Allanblackia floribunda* Seed Extract Attenuates the Ethanol-Induced Gastric Ulcer in Rats via the Inhibition of TNF- α and INF- γ Levels and

Modulation in the Expression of Ki67 Protein. Biomed Res Int. 2021;2021:6694572. d

36. Fahmy HM, Salah Eldin RE, Abu Serea ES, Gomaa NM, AboElmagd GM, Salem SA, et al. Advances in nanotechnology and antibacterial properties of biodegradable food packaging materials. RSC Adv. 2020;10(35):20467-20484.

37. Rahman Z, Dwivedi DK, Jena GB. The intervention of *tert*-butylhydroquinone protects ethanol-induced gastric ulcer in type II diabetic rats: the role of Nrf2 pathway. Can J Physiol Pharmacol. 2021;99(5):522-35.

38. Mahapatro M, Erkert L, Becker C. Cytokine-mediated crosstalk between immune cells and epithelial cells in the gut. Cells. 2021;10(1):111.

39. Raish M, Shahid M, Bin Jordan YA, Ansari MA, Alkharfy KM, Ahad A, et al. Gastroprotective effect of sinapic acid on ethanol-induced gastric ulcers in rats: involvement of Nrf2/HO-1 and NF- κ B signaling and antiapoptotic role. Front Pharmacol. 2021;12:622815.