

# Gal-3 Expression in Oral and Lip SCC: Histopathological Correlation via Immunohistochemistry

Negin Alakhani<sup>#1</sup>, Farnaz Mohajertehran<sup>#2</sup>, Armaghan Salehi<sup>3</sup>,  
Nooshin Mohtasham<sup>4</sup>, Abdollah Javan-Rashid<sup>5</sup>, Kambiz Kamyab-Hesari<sup>\*6</sup>

## Abstract

**Background:** Oral and lip squamous cell carcinomas (OSCC) are malignancies among head and neck cancers. OSCC is characterized by aggressive behavior and poorer prognosis compared to other squamous cell carcinomas. Galectin-3 (Gal-3) is a multifunctional protein involved in processes such as cell proliferation, apoptosis, and metastasis. This study aims to evaluate and compare Gal-3 expression among groups to investigate its role in the biological behaviors of lip and oral SCCs.

**Methods:** Immunohistochemical analysis of Gal-3 was performed on OSCC and lip SCC samples, with oral and lip marginal tissues obtained as the control group. The clinicopathological parameters, including the invasive front (IF), depth of invasion (DOI), and muscular, neural, and vascular invasions, were assessed. The staining percentage, intensity, and cellular location of Gal-3 were compared between the study groups. A p-value of  $< 0.05$  was considered statistically significant.

**Results:** Gal-3 staining percentages were significantly higher in the SCC groups compared to control groups ( $P < 0.001$  for each). Staining intensity and nuclear staining were higher in OSCC than in lip SCC ( $P < 0.001$ ,  $P < 0.010$ , respectively). Nuclear Gal-3 was notably associated with the presence of muscle invasion in OSCC ( $P = 0.030$ ). High IF status was correlated with Gal-3 expression in lip SCC ( $P = 0.010$ ). Staining intensity was significantly higher in OSCC samples with vascular invasion compared to those without ( $P = 0.016$ ).

**Conclusion:** The higher Gal-3 expression and nuclear staining in OSCC may explain its aggressive nature. Gal-3 could be a diagnostic and prognostic biomarker due to its increased expression in cancerous tissues compared to normal samples.

**Keywords:** Depth of invasion, Galectin-3, Head and neck squamous cell carcinoma, Invasive front, Immunohistochemistry.

## Introduction

Oral squamous cell carcinoma (OSCC) is the most common malignancy in the field of head and neck cancers, accounting for approximately 90% of all oral cavity carcinomas (1, 2). According to the Global Cancer Statistics, in 2020, 377,713 new lip

and oral cavity cancers and 177,757 deaths were reported worldwide (3). Oral squamous cell carcinoma has been detected in the following areas: tongue (41.7%), lip and floor of the mouth (each 16.5%), gingiva (10.6%), buccal mucosa (6.7%), retromolar trigone

1: Oral and Dental Diseases Research Center, Kerman University of Medical Science, Kerman, Iran.

2: Dental Research Center, Mashhad University of Medical Sciences, Mashhad, Iran.

3: Student Research Committee, Faculty of Dentistry, Mashhad University of Medical Sciences, Mashhad, Iran.

4: Oral and Maxillofacial Diseases Research Center, Mashhad University of Medical Sciences, Mashhad, Iran.

5: School of Dentistry, Mashhad University of Medical Sciences, Mashhad, Iran.

6: Department of Dermatopathology, Razi Hospital, Tehran University of Medical Sciences, Tehran, Iran.

# This The two authors are considered as the first author.

\*Corresponding author: Kambiz Kamyab-Hesari; Tel: +98 21 55618989; E-mail: Kamyab@tums.ac.ir.

Received: 15 Mar, 2025; Accepted: 26 Apr, 2025

(5.6%), and hard palate (2.3%) (4). Between 23.6% and 30% of all oral cancers are lip squamous cell carcinoma (Lip SCC). In comparison with OSCC, lip SCC is less common, less aggressive and has a higher survival rate due to its diverse tumor behaviors and molecular biology (5, 6). OSCC risk factors, include smoked and non-smoked forms of tobacco, alcohol, and human papillomavirus (HPV) infections (7-9). In contrast, lip SCC is associated with ultraviolet (UV) radiation and fair skin types (10).

Staging and grading are two significant factors in determining the prognosis of oral cancer. The American Joint Committee on Cancer (AJCC) suggests the simultaneous use of biological factors and tumor-node-metastasis (TNM) system to enhance prognostic accuracy. Therefore, more personalized and effective treatment plans will be provided for patients (11).

Recently, there have been several studies on the influences of clinical and histopathological parameters on the prognosis and survival rates of OSCC. The TNM system doesn't consider the tumor's biological behavior such as invasive front (IF). Today, histopathological parameters such as invasive front, neural, lymphatic and vascular invasion and depth of invasion (DOI) are known as prognostic factors. Several studies have evaluated the relationship between these parameters and poorer survival rates (12, 13).

There are various biomarkers that affect oral cancer processes, such as galectin-3 (Gal-3), which is a multifunctional protein involved in a variety of biological processes, including cell proliferation, adhesion, differentiation, mRNA splicing, cell-cycle progression, immune system evasion, inflammation, angiogenesis, apoptosis, and metastasis (14).

Recently, Gal-3 expression levels in squamous cell carcinoma have attracted the attention of researchers; however, only a few studies have compared its expression with that in normal margins (15-18).

This study aims to analyze and compare Gal-3 expression levels among oral SCC, lip

SCC, and normal margin tissue samples using immunohistochemistry (IHC).

## Materials and Methods

### *Sample selection*

Considering that this study is being conducted for the first time, there are not directly comparable studies with this group of patients and controls to serve as a reference. Based on financial and time constraints, the following sample sizes were considered.

In this study, 27 paraffin blocks from oral SCC and 27 from normal oral margin tissue were gathered from the pathology lab archives at Mashhad Dental School. Furthermore, 25 paraffin blocks from lip SCC and 28 normal lip tissue samples for the the control group were collected from the archives of the pathology lab at Razi Skin Hospital, affiliated with Tehran University of Medical Sciences. The study was approved by the Ethics Committee of Mashhad University of Medical Sciences (IR.MUMS.DENTISTRY.REC. 1400.022) and conducted from September 2022 to May 2024. All study participants provided written informed consent and were free to withdraw at any point during the study.

The inclusion and exclusion criteria for this study were established based on the guidelines provided by the American Joint Committee on Cancer (AJCC). The inclusion criteria included high-quality paraffin blocks containing primary tumor specimens, specifically those obtained through excisional biopsies that included normal marginal tissues. Conversely, the exclusion criteria included paraffin blocks of poor quality, those with improper fixation, and specimens associated with recurrences, necrosis, or blood contamination. Additionally, patients who had received anti-tumoral treatments were excluded from the study. Medical history and demographic information were carefully documented to ensure comprehensive data analysis.

### *Tissue sample preparation*

All tissue samples were fixed in a 10% neutral-buffered formalin solution for 72 hours. The samples were then embedded in paraffin blocks.

Each paraffin-embedded specimens were sectioned into two 5- $\mu$ m thick sections using microtome blades (HM-325, POOYAN TEB, Iran) and subsequently stained with Hematoxylin and Eosin (H&E).

#### ***Immunohistochemically staining processes***

The sections were placed on glass slides coated with Poly-L-lysine. The tissue sections were then deparaffinized with xylene at 60°C for 30 to 40 minutes, and varying alcohol concentrations were used to rehydrate the sections. Antigen retrieval was performed by treating the specimens with Tris-ethylenediaminetetraacetic acid (EDTA) buffer (pH 8.0) at 98°C for 20 minutes. After cooling to room temperature for 20 minutes, the slides were washed with Tris-buffered saline (TBS). Endogenous peroxidase activity was blocked using a 3% hydrogen peroxide (H<sub>2</sub>O<sub>2</sub>) solution for 10 minutes. Then, the slides were rinsed once again with TBS. The sections were incubated with a primary antibody against Gal-3 (PA0238-U, ready to use, supplied by Novocastra) for 30 minutes, then washed again with TBS. The slides were incubated with post-primary blocking solution (Leica Co, United Kingdom) for 20 minutes. After this incubation, they were washed with TBS. Next, the slides were incubated with Novolink Polymer (DAB included, Germany) for 20 minutes. Following another wash with TBS, the slides were incubated with the diaminobenzidine peroxidase substrate (ref. MAD-021540Q-125). This was followed by washing the slides with tap water. Mayer's hematoxylin was applied for 3 minutes. A final wash with tap water and graded alcohol was performed. After all these steps, the slides were taken for microscopic examination.

#### ***Histopathological assessment***

A total of 107 slides were independently and double-blindly analyzed by two pathologists. For each tissue sample, five randomized, non-overlapping microscopic fields were observed using a LABOMED optical microscope at 100x magnification and TrueChrome Metrics (EX Fucos 0.5 X, USA). The pathologists confirmed

the histopathological diagnoses of OSCC and lip SCC.

According to the College of American Pathologists Cancer Protocols, the grading scores, intensity levels of the IF and DOI, as well as the absence or presence of muscular, neural, and vascular invasions, were recorded (19).

#### ***Analysis of staining Procedure***

In this study, the expression of Gal-3 was evaluated in both nuclear and cytoplasmic locations in epithelial tissue cells. Our professional pathologists established a scoring range for each tumor to describe the intensity of the staining: low intensity for light brown, moderate intensity for brown, and high intensity for dark brown. The percentage of stained cells was evaluated at 400x magnification. To investigate the expression level, staining intensity scores and staining percentages were reported separately.

#### ***Statistical analysis***

The patients' demographic information and the data from IHC were analyzed using SPSS software, version 23 (SPSS, Inc., Chicago, IL, USA). The Pearson Chi-squared test and Student's t-test were used to determine the association between Gal-3 expression in cancerous and healthy normal tissues. A p-value of less than 0.05 was considered statistically significant.

#### ***Results***

This study evaluated 27 cases of OSCC, including twelve (44.4%) women and fifteen (56.5%) men, with a mean  $\pm$ SD age of 54.41  $\pm$  12.57 years (range 31 to 75 years), and 27 cases of normal oral tissues including thirteen (48.1%) women and fourteen (51.9%) men, with a mean  $\pm$ SD age of 48 $\pm$ 13.01 years. Furthermore, 25 cases of lip SCC were evaluated, including fourteen (56%) women and eleven (44%) men, with a mean  $\pm$  standard deviation (SD) age of 52.12 $\pm$ 11.93 years (range 29 to 71 years), and 28 cases of normal lip tissues, including thirteen (46.4%) women and fifteen (53.6%) men, with a mean age of

### Galectin-3 Expression in Oral and Lip SCC

51.39±11.87. There was no statistically significant relationship between these groups in

terms of age or gender ( $P > 0.05$ ). Extra details are mentioned in Table 1.

**Table 1.** Histopathological and Immunohistochemical Characteristics of Oral and Lip Squamous Cell Carcinoma Samples.

Variant	Number of samples	Percentage of samples
Oral margin tissue	27	49
Lip margin tissue	28	51
Total	55	100
<b>OSCC</b>		
Grade I	15	55.5
Grade II	9	33.3
Grade III	3	11.1
Total	27	100
<b>Lip SCC</b>		
Grade I	17	68
Grade II	5	20
Grade III	3	12
Total	25	100
<b>IF</b>		
OSCC Low	22	68
OSCC High	5	32
Lip SCC Low	17	25.9
Lip SCC High	8	7.4
<b>DOI</b>		
OSCC Low	7	66.6
OSCC Moderate	2	68
OSCC High	18	0
Lip SCC Low	17	11.1
Lip SCC Moderate	0	88.8
Lip SCC High	8	48
<b>Vascular invasion</b>		
OSCC Absent	3	11.1
OSCC Present	24	88.8
Lip SCC Absent	12	48
Lip SCC Present	13	52
<b>Muscular invasion</b>		
OSCC Absent	9	33.3
OSCC Present	18	66.6
Lip SCC Absent	7	28
Lip SCC Present	18	72
<b>Neural invasion</b>		
OSCC Absent	16	59.3
OSCC Present	11	40.7
Lip SCC Absent	25	100
Lip SCC Present	0	0

Abbreviations: **IF**: Invasive front; **DOI**: depth of invasion; **Lip SCC**: Lip squamous cell carcinoma. **OSCC**: Oral squamous cell carcinoma.

### **Expression of Gal-3 in cancerous and margin groups**

The OSCC samples exhibited higher staining intensity compared to the lip SCC samples ( $p = 0.001$ ) (Table 2). Immunohistochemical staining grades of Gal-3 expression in OSCC samples are shown in Figure 1.

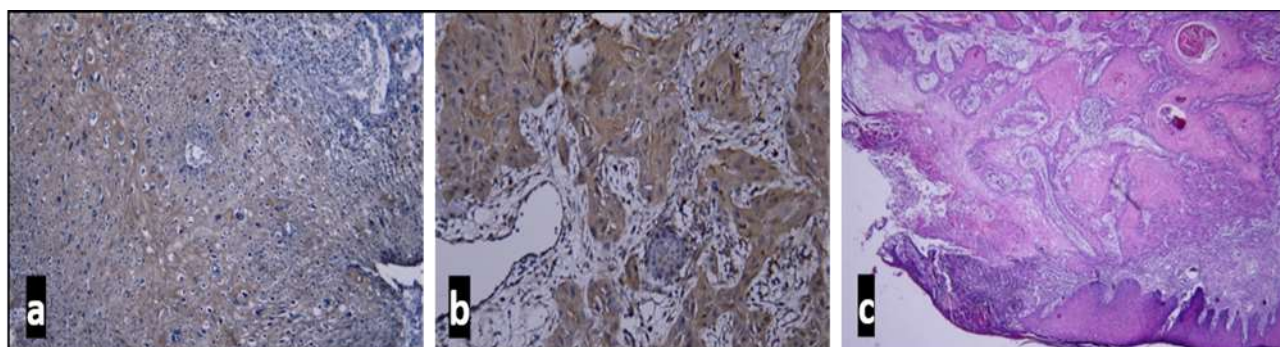
The IHC staining revealed that the staining intensity of Gal-3 was not significantly different between the control group and the SCC groups ( $P > 0.05$ ). Additionally, there was no correlation between staining intensity and tumor grade.

The IHC staining results showed that Gal-3 staining percentages were higher in SCC groups than in control groups ( $P < 0.001$ ) (Fig. 2) while they were not statistically different between lip SCC and OSCC groups ( $P = 0.069$ ). There was no statistically significant relationship for Gal-3 staining percentages between different grades of the OSCC group, as well as the lip SCC group. Additionally, oral SCC tissues showed nuclear staining, while oral margin tissues did not. Also, oral SCC samples exhibited a higher number of nuclear staining than lip SCC samples ( $P = 0.010$ ) (Table 3).

**Table 2.** Grades of staining intensity of galectin-3 for OSCC and lip SCC groups.

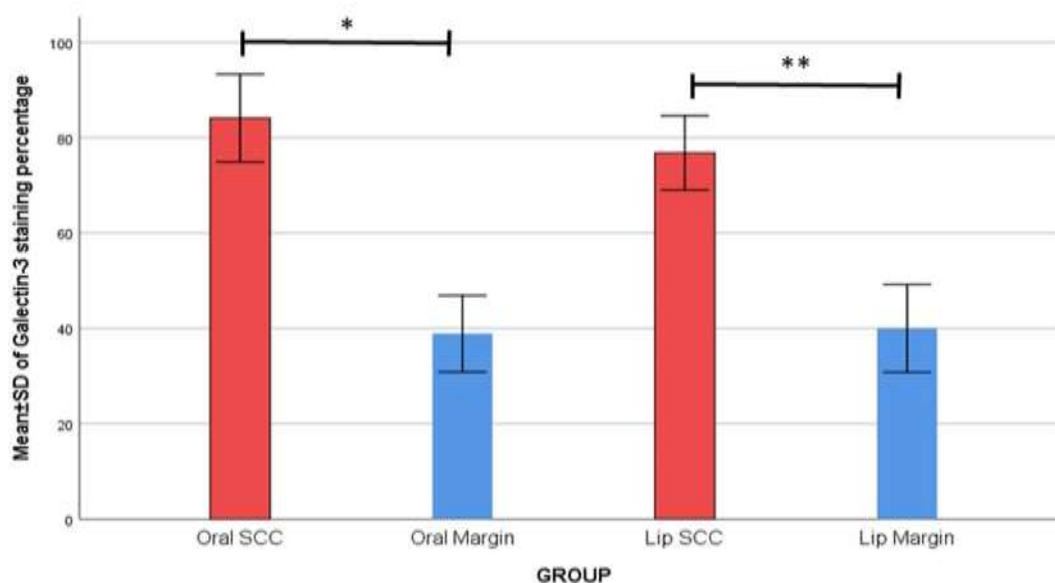
Gal-3 staining grades	Lip SCC n (%)	OSCC n (%)	Mann-Whitney U-Test
Low	18 (72.0)	7 (25.9)	
Moderate	7 (28.0)	19 (70.3)	Z=3.31 <b>0.001*</b>
High	0 (0)	1 (3.7)	
Mean Rank	20.14	32.39	

Abbreviations: **Lip SCC**: Lip squamous cell carcinoma; **OSCC**: Oral squamous cell carcinoma.



**Fig. 1.** Immunohistochemically staining of Gal-3 expression in OSCC samples. (a) Illustrates the moderate staining intensity of Gal-3 located in the cytoplasm of epithelial cells in an OSCC (grade III) sample (100× magnification). (b) Demonstrates the high invasive front of the OSCC (grade III) sample with high staining intensity of cytoplasmic galectin-3 (40× magnification). (c) Hematoxylin and eosin staining indicates the proliferation of OSCC (grade I) malignant cells in connective tissue (40× magnification).

## Galectin-3 Expression in Oral and Lip SCC



**Fig. 2.** The comparison of staining percentage of Gal-3 between cancerous groups and their normal tissues. The \* and \*\* indicate  $p < 0.01$  and  $p < 0.001$ .

**Table 3.** Gal-3 staining percentages and cytoplasmic-nuclear location for each grade of tumors.

Study group	Staining percentages (%)	Kruskal-Wallis Test (p-value)	Cytoplasmic staining n (%)	Nuclear staining n (%)	Chi-Square Test (p-value)
Oral margin	38.89	<b>&lt; 0.001*</b>	27 (100)	0 (0)	<b>0.005*</b>
<b>OSCC<sup>a</sup> (total)</b>	84.7		20 (74.1)	7 (25.9)	
Grade I	81.3		12 (80)	3 (20)	
Grade II	83.3		5 (55.6)	4 (44.4)	
Grade III	100		3 (100)	0 (0)	
Lip margin	40		26 (92.9)	2 (7.1)	
<b>Lip SCC<sup>b</sup> (total)</b>	76.8		25 (100)	0 (0)	
Grade I	75.9	<b>&lt; 0.001*</b>	17 (100)	0 (0)	0.603
Grade II	90		5 (100)	0 (0)	
Grade III	60		3 (100)	0 (0)	

Abbreviations: **Lip SCC**: Lip squamous cell carcinoma; **OSCC**: Oral squamous cell carcinoma Staining percentages; P-value<sup>a b</sup> = 0.069 cytoplasmic-nuclear staining; P-value<sup>a b</sup> = **0.010**

### *Evaluation of the relationship between galectin-3 expression with histopathological parameters*

The staining percentage and intensity of Gal-3 in lip SCC samples were lower in low IF

conditions compared to high IF conditions. IF status was associated with both Gal-3 staining percentage and intensity in lip tumors ( $P = 0.000$ ,  $P = 0.010$ , respectively). There was no

statistically significant relationship between the staining intensity or staining percentage of Gal-3 and IF status for OSCC samples. Staining intensity of Gal-3 was strongly associated with vascular invasion of OSCC tumors (P = 0.016). In samples without vascular invasion, Gal-3 staining intensity was lower. Other microscopic features were not statistically significant in relation to Gal-3 expression (Table 4).

Oral SCC specimens with muscle invasion showed higher nuclear staining percentages

compared to those without muscle invasion (P= **0.030**). There were no statistically significant differences between nuclear-cytoplasmic staining and other histopathological parameters of malignancies (Table 5). In low IF conditions, the staining percentage and intensity were higher in OSCC samples than in lip SCC tissues (respectively, P = 0.008 and P< 0.001). The staining intensity level of OSCC was higher than that of lip SCC under high DOI conditions (P = 0.016).

**Table 4.** Association between galectin-3 staining and histopathological parameters analyzed by Mann-Whitney U Test.

Histopathological parameters	Staining percentages				Staining intensity							
	OSCC n (%)	p-value	Lip SCC n (%)	p-value	OSCC n (%)				Lip SCC n (%)			
					Low	Moderate	High	P-value	Low	Moderate	High	P-value
<b>IF</b>	Low	84.9	67.65	<b>0.000*</b>	4	17	1	0.060	15	2	0	<b>0.010*</b>
	High	84	96.25		(14.8)	(62.9)	(3)		(60)	(8)	(0)	
<b>DOI</b>	Low	74.29	72.94	0.120	4	3	0	0.093	12	5	0	0.822
	Moderate	100	--		0	2	0		0	0	0	
	High	86.11	85		3	14	1		6	2	0	
<b>Vascular invasion</b>	Absent	66.67	89.17	0.052	14	3	0	<b>0.016*</b>	32	6	0	0.376
	Present	86.25	83.85		(82.4)	(17.6)	(0)		(84)	(15.8)	(0)	
<b>Muscular invasion</b>	Absent	81.11	75.71	0.883	11	3	0	0.141	25	2	0	0.212
	Present	85.56	77.22		(78.6)	(21.4)	(0)		(92)	(7.4)	(0)	
					(27)	(56.8)	(16)		(60)	(39.1)	(0)	
<b>Neural invasion</b>	Absent	82.50	76.80	0.342	18	13	1	0.368	39	11	0	--
	Present	86.36	--		(56.3)	(40.6)	(3.1)		(78)	(22)	(0)	
					3	11	5		0	0	0	
					(15.8)	(57.9)	(26)		(0)	(0)	(0)	

Abbreviations: **IF**: Invasive front; **DOI**: depth of invasion; **Lip SCC**: Lip squamous cell carcinoma; **OSCC**: Oral squamous cell carcinoma.

**Table 5.** Association between galectin-3 location and histopathological parameters analyzed by Mann-Whitney U Test.

Histopathological parameters	OSCC			Lip SCC			
		Cytoplasmic staining n (%)	Nuclear staining n (%)	p-value	Cytoplasmic staining n (%)	Nuclear staining n (%)	p-value
<b>IF</b>	Low	17(77.30)	5(22.7)	0.580	17(100)	0	0.580
	High	3(60)	2(40)		8(100)	0	
<b>DOI</b>	Low	7(100)	0	0.094	17(100)	0	---
	Moderate	2(100)	0		---	--	
	High	11(61.1)	7(38.9)		8(100)	0	
<b>Vascular invasion</b>	Absent	3(100)	0	0.545	12(100)	0	--
	Present	17(70.8)	7(29.2)		13(100)	0	
<b>Muscular invasion</b>	Absent	9(100)	0	<b>0.030*</b>	7(100)	0	--
	Present	11(61.1)	7(38.9)		18(100)	0	
<b>Neural invasion</b>	Absent	11(68.8)	5(31.3)	0.446	25(100)	0	---
	Present	9(81.8)	2(18.2)		0	0	

Abbreviations: **IF**: Invasive front; **DOI**: depth of invasion; **Lip SCC**: Lip squamous cell carcinoma; **OSCC**: Oral squamous cell carcinoma

### Discussion

The incidence rate of OSCC is increasing worldwide. Although several advancements in cancer management have occurred, the overall survival rate for OSCC is still less than 50% (20). Poor prognosis and high death rates are associated with late diagnosis, as most patients are diagnosed in advanced stages. A systematic review reported that whenever diagnosis is delayed, the cancer prognosis becomes poorer (21, 22). Therefore, the recent identification of potential biomarkers for OSCC has been highlighted (23, 24). A meta-analysis (25) found that Gal-3 played an oncogenic role in colorectal cancer, ovarian cancer and non-small cell lung cancer. Tumor Progression impact of Gal-3 in oral malignancies such as Head and neck squamous cell carcinoma (HNSCC), melanoma and oral squamous cell carcinoma has been recorded in several studies (26-29). Therefore, there has been increasing attention to targeting the Gal-3 for therapeutic approaches for oral carcinomas (30).

In this study, we evaluated the expression of Gal-3 in three groups: marginal tissue, OSCC, and lip SCC. Additionally, for the first time we compared the expression between lip SCC and oral SCC to identify biological mechanisms that could explain the differences in tumor behavior, such as the less aggressive nature, lower metastasis rates, and better prognosis observed in Lip SCC (31).

Our results show that Gal-3 expression was higher in OSCC and lip SCC groups compared to control group. Similarly, several studies have shown overexpression of Gal-3 in a variety of SCCs, including oral tongue squamous cell carcinoma (OTSCC), OSCC and HNSCC, compared to normal control groups (29, 32, 33). In contrast, Selvaraj FM found a higher level of Gal-3 in normal mucosa compared to OSCC tissues (34).

The current study found no relation between histopathological grades and staining percentages of Gal-3 in either carcinoma. A 2024 report similarly showed no association between Gal-3 and tumor grade in urinary

bladder cancer (35). Conversely, Tokmak S *et al.* and Weber *et al.*, reported the high-grade tumors have statistically higher total expression scores than low-grade tumors (36, 37). The conflict could be justified by differences in study groups and cancer behaviors.

In our study, the nuclear and cytoplasmic expression of Gal-3 was evaluated separately. Assessing the specimens, nuclear Gal-3 was observed in OSCC samples. However, Gal-3 was not located in the nucleus in lip SCC samples. This finding may help explain the more aggressive behavior of OSCC. A review reported the influence of nuclear Gal-3 in regulating the expression of cyclin D1 (CCND1) (ID:595), thyroid terminal factor 1 (TTF-1) (ID:7270), and mucin 2, oligomeric mucus/gel-forming (MUC2) (ID:4583) genes associated with oncogenic pathways (38). Similarly, in two studies—one on breast cancer (39) and the other on papillary thyroid cancer (40) persistent overexpression of nuclear Gal-3 promoted the upregulation of cyclin D1 gene expression (a critical molecule for cell cycle regulation) in cancerous breast cells and also enhanced the transcriptional activity of TTF-1, contributing to proliferation and tumor progression in thyroid cells.

Pătru A, *et al.* reported that in palate SCC cases, the maximum reactivity of Gal-3 was observed in the basaloid layer with the nuclear pattern (41). Selvaraj (34), observed a decrease of nuclear Gal-3 as the grade of OSCC increased. In contrast, Alves PM, *et al.* found that in tongue SCC Gal-3 has a crucial role in tumor progression when expressed in the cytoplasm (42). Additionally, Tokmak S showed that there was no statistically significant correlation between the clinicopathological parameters of OSCC patients and the location of Gal-3 expression (36).

Gal-3 IHC demonstrated a higher expression in Lip SCC samples which have a high invasive front (IF), in OSCC it was not statistically significant however it was close to significance ( $P=0.60$ ). In a same report, Pătru A, *et al.* (41), showed that the Gal-3 tumor

reactivity was higher at the invasion front of palate squamous cell carcinomas.

There was no relationship between DOI and Gal-3 amounts. Similarly, Cela I, *et al.* reported no association for level of Gal-3 expression and DOI (43).

The current analysis showed an association of higher Gal-3 expression for OSCC samples between higher Gal-3 expression and vascular invasion was present. However, it was very close to significance in lip SCC ( $P=0.052$ ). Additionally, there was a significant relationship between both muscular invasion and nuclear and cytoplasmic staining for OSCC samples. However, there were no associations were found between neural invasion and Gal-3 expression. In a previous study on palatal SCC patients, Gal-3 was overexpressed when muscle invasion was present (41). Tokmak S (36) reported no relationship between perineural invasion or vascular invasion and total, nuclear, or cytoplasmic Gal-3 expression.

In a comparison of lip and Oral tumoral tissues, OSCC samples showed higher Gal-3 expression than Lip SCC tissues. Most of the OSCC samples showed high intensity staining; however, most of the Lip SCC showed moderate intensity. Oral SCC exhibited more staining intensity than lip SCC in high DOI status. Staining intensity and percentage in low IF status were higher in oral SCC than lip SCC. This finding suggests that the more aggressive behavior of OSCC can be explained by overexpression of Gal-3 in cancerous cells. Further studies with an increased sample size and assessments of survival rates, could validate the prognostic value of Gal-3.

We highlight, for the first time, the differential expression levels of Gal-3 in lip SCC and OSCC. The nuclear localization and higher expression level of Gal-3 could explain the aggressive behavior and poor prognosis of OSCC. Our findings suggest that Gal-3 could be a prognostic biomarker and therapeutic target for OSCC. Furthermore, we found an increase in Gal-3 expression in cancerous cases. Therefore, this marker could be used as a diagnostic marker.

## Acknowledgments

We would like to express our gratitude to all the participants who took part in this research. The authors appreciate the Research Council of Mashhad University of Medical Sciences, Faculty of Dentistry, for their financial support. We sincerely thank Mona Abbasi Pirouz for the valuable support and cooperation in this research.

## Funding

This study was funded in full by Mashhad University of Medical Sciences, Faculty of Dentistry, grant number (992131). This article was extracted from a student thesis.

## References

1. Sharma A, Indu S, Gautami D, Sharma V. Oral squamous cell carcinoma (OSCC) in humans: Etiological Factors, diagnostic and therapeutic relevance. *Res J Biotechnol.* 2020;15:141-51.
2. Salah M, Rezaee M, Fattahi MJ, Ghaderi A, Khademi B, Mokhtari MJ. Association of lncRNA ANRIL rs10757278 A> G Variant, Tumor Size, Grading, Tumor Site, and Tumor Stage in Oral Squamous Cell Carcinoma Patients. *Rep Biochem Mol Biol.* 2024;13(1):59-66.
3. Sung H, Ferlay J, Siegel RL, Laversanne M, Soerjomataram I, Jemal A, Bray F. Global Cancer Statistics 2020: GLOBOCAN Estimates of Incidence and Mortality Worldwide for 36 Cancers in 185 Countries. *CA Cancer J Clin.* 2021;71(3):209-249.
4. Stepan KO, Mazul AL, Larson J, Shah P, Jackson RS, Pipkorn P, et al. Changing Epidemiology of Oral Cavity Cancer in the United States. *Otolaryngol Head Neck Surg.* 2023 Apr;168(4):761-768.
5. Alhabbab R, Johar R. Lip cancer prevalence, epidemiology, diagnosis, and management: A review of the literature. *Adv Oral Maxillofacial Surg.* 2022;6:100276.
6. Batista AC, Costa NL, Oton-Leite AF, Mendonça EF, Alencar Rde C, Silva TA. Distinctive clinical and microscopic features of

## Conflict of Interest

No conflict of interests.

## Author contribution

F.M. and N.M. conceived and designed the study. N.A. and A.S. performed the experiments, while K.K. and N.M collected and managed the data. A.J. carried out the formal analysis. N.A. and F.M. wrote the original draft of the manuscript. N.M. and K.K. contributed to reviewing and editing the manuscript. F.M. supervised the project. All authors have read and approved the final version of the manuscript.

- squamous cell carcinoma of oral cavity and lip. *Oral Surg Oral Med Oral Pathol Oral Radiol Endod.* 2010;109(3):e74-9.
7. Chamoli A, Gosavi AS, Shirwadkar UP, Wangdale KV, Behera SK, Kurrey NK, et al. Overview of oral cavity squamous cell carcinoma: Risk factors, mechanisms, and diagnostics. *Oral Oncol.* 2021 Oct;121:105451.
  8. Shahabinejad M, Zare R, Asadi Z, Mohajertehran F. LAMP3 (CD208) Expression in Squamous Cell Carcinoma and Epithelial Dysplasia of the Oral Cavity and Clinicopathological Characteristics of Unfavorable Prognosis. *Rep Biochem Mol Biol.* 2021;9(4):373-378.
  9. Bota JP, Lyons AB, Carroll BT. Squamous Cell Carcinoma of the Lip-A Review of Squamous Cell Carcinogenesis of the Mucosal and Cutaneous Junction. *Dermatol Surg.* 2017;43(4):494-506.
  10. Amin MB, Greene FL, Edge SB, Compton CC, Gershengwald JE, Brookland RK, et al. The Eighth Edition AJCC Cancer Staging Manual: Continuing to build a bridge from a population-based to a more "personalized" approach to cancer staging. *CA Cancer J Clin.* 2017;67(2):93-99.
  11. Majumdar B, Patil S, Sarode SC, Sarode GS, Rao RS. Clinico- pathological

prognosticators in oral squamous cell carcinoma: An update. *Transl Res Oral Oncol.* 2017;2:2057178X17738912.

12. Sandu K, Nisa L, Monnier P, Simon C, Andrejevic-Blant S, Bron L. Clinicobiological progression and prognosis of oral squamous cell carcinoma in relation to the tumor invasive front: impact on prognosis. *Acta Otolaryngol.* 2014;134(4):416-24.

13. Sciacchitano S, Lavra L, Morgante A, Ulivieri A, Magi F, De Francesco GP, et al. Galectin-3: One Molecule for an Alphabet of Diseases, from A to Z. *Int J Mol Sci.* 2018;19(2):379.

14. Endo H, Muramatsu T, Furuta M, Uzawa N, Pimkhaokham A, Amagasa T, et al. Potential of tumor-suppressive miR-596 targeting LGALS3BP as a therapeutic agent in oral cancer. *Carcinogenesis.* 2012;34(3):560-9.

15. Zhang X, Ding H, Lu Z, Ding L, Song Y, Jing Y, et al. Increased LGALS3BP promotes proliferation and migration of oral squamous cell carcinoma via PI3K/AKT pathway. *Cell Signal.* 2019;63:109359.

16. Fukamachi M, Kasamatsu A, Endo-Sakamoto Y, Fushimi K, Kasama H, Iyoda M, et al. Multiple coagulation factor deficiency protein 2 as a crucial component in metastasis of human oral cancer. *Exp Cell Res.* 2018;368(1):119-25.

17. Singh P, Verma JK, Singh JK. Validation of Salivary Markers, IL-1 $\beta$ , IL-8 and Lgals3bp for Detection of Oral Squamous Cell Carcinoma in an Indian Population. *Sci Rep.* 2020;10(1):7365.

18. Kim MJ, Ahn KM. Prognostic factors of oral squamous cell carcinoma: the importance of recurrence and pTNM stage. *Maxillofac Plast Reconstr Surg.* 2024;46(1):8.

19. González-Moles MÁ, Aguilar-Ruiz M, Ramos-García P. Challenges in the Early Diagnosis of Oral Cancer, Evidence Gaps and Strategies for Improvement: A Scoping Review of Systematic Reviews. *Cancers.* 2022;14(19):4967.

20. Seoane J, Alvarez–Novoa P, Gomez I, Takkouche B, Diz P, Warnakulasiruya S, et al. Early oral cancer diagnosis: The Aarhus statement perspective. A systematic review and

meta-analysis. *Head Neck.* 2016;38(S1):E2182-E9.

21. Rivera C, Oliveira AK, Costa RAP, De Rossi T, Paes Leme AF. Prognostic biomarkers in oral squamous cell carcinoma: A systematic review. *Oral Oncol.* 2017;72:38-47.

22. Wang Y, Liu S, Tian Y, Wang Y, Zhang Q, Zhou X, et al. Prognostic role of galectin-3 expression in patients with solid tumors: a meta-analysis of 36 eligible studies. *Cancer Cell Int.* 2018;18:172.

23. Coppock JD, Mills AM, Stelow EB. Galectin-3 Expression in High-Risk HPV-Positive and Negative Head & Neck Squamous Cell Carcinomas and Regional Lymph Node Metastases. *Head Neck Pathol.* 2021;15(1):163-8.

24. Delorge S, Saussez S, Pelc P, Devroede B, Marchant H, Burchert M, et al. Correlation of galectin-3/galectin-3-binding sites with low differentiation status in head and neck squamous cell carcinomas. *Otolaryngol Head Neck Surg.* 2000;122(6):834-41.

25. Braeuer RR, Zigler M, Kamiya T, Dobroff AS, Huang L, Choi W, et al. Galectin-3 contributes to melanoma growth and metastasis via regulation of NFAT1 and autotaxin. *Cancer Res.* 2012;72(22):5757-66.

26. Aggarwal S, Sharma SC, Das SN. Galectin-1 and galectin-3: Plausible tumour markers for oral squamous cell carcinoma and suitable targets for screening high-risk population. *Clin Chim Acta.* 2015;442:13-21.

27. Scafetta G, D'Alessandria C, Bartolazzi A. Galectin-3 and cancer immunotherapy: a glycobiological rationale to overcome tumor immune escape. *Journal of Experimental & Clinical Cancer Research.* 2024;43(1):41.

28. Bota JP, Lyons AB, Carroll BT. Squamous Cell Carcinoma of the Lip-A Review of Squamous Cell Carcinogenesis of the Mucosal and Cutaneous Junction. *Dermatol Surg.* 2017;43(4):494-506.

29. Wang LP, Chen SW, Zhuang SM, Li H, Song M. Galectin-3 accelerates the progression of oral tongue squamous cell carcinoma via a Wnt/ $\beta$ -catenin-dependent pathway. *Pathol Oncol Res.* 2013;19(3):461-74.

30. Saussez S, Lorfevre F, Lequeux T, Laurent G, Chantrain G, Vertongen F, et al. The determination of the levels of circulating galectin-1 and -3 in HNSCC patients could be used to monitor tumor progression and/or responses to therapy. *Oral Oncol.* 2008;44(1):86-93.
31. Selvaraj FM, Joseph AP, Varun BR, Mony V, Siva Kumar TT. Immunohistochemical Evaluation of Galectin-3 Expression in Oral Squamous Cell Carcinoma, Oral Leukoplakia and Normal Mucosa. *Indian J Dent Res.* 2022;33(3):282–6.
32. Al-Maghrabi JA, Khabaz MN. Clinical significance of galectin-3 expression in urinary bladder carcinoma. *J Int Med Res.* 2023;51(2):3000605231153323.
33. Tokmak S, Arık D, Pınarbaşı Ö, Gürbüz MK, Açıkalm MF. Evaluation and Prognostic Significance of Galectin-3 Expression in Oral Squamous Cell Carcinoma. *Ear Nose Throat J.* 2019;100(5 Suppl):578S–83S.
34. Weber M, Büttner-Herold M, Distel L, Ries J, Moebius P, Preidl R, et al. Galectin 3 expression in primary oral squamous cell carcinomas. *BMC Cancer.* 2017;17(1):906.
35. Nakahara S, Raz A. Regulation of cancer-related gene expression by galectin-3 and the molecular mechanism of its nuclear import pathway. *Cancer Metastasis Rev.* 2007;26(3-4):605-10.
36. Lin HM, Pestell RG, Raz A, Kim HR. Galectin-3 enhances cyclin D(1) promoter activity through SP1 and a cAMP-responsive element in human breast epithelial cells. *Oncogene.* 2002;21(52):8001-10.
37. Paron I, Scaloni A, Pines A, Bachi A, Liu FT, Puppini C, et al. Nuclear localization of Galectin-3 in transformed thyroid cells: a role in transcriptional regulation. *Biochem Biophys Res Commun.* 2003;302(3):545-53.
38. Pătru A, Şurlin V, Mărgăritescu C, Ciucă EM, Matei M, Dumitrescu D, et al. Immunohistochemical evaluation of D2-40, Galectin-3, Maspin and MCM7 expression in palate squamous cell carcinomas. *Rom J Morphol Embryol.* 2021;62(1):133-49.
39. Alves PM, Godoy GP, Gomes DQ, Medeiros AMC, de Souza LB, da Silveira EJD, et al. Significance of galectins-1, -3, -4 and -7 in the progression of squamous cell carcinoma of the tongue. *Pathol Res Pract.* 2011;207(4):236–40.
40. Cela I, Caponio VCA, Capone E, Pinti M, Mascitti M, Togni L, et al. LGALS3BP is a potential target of antibody-drug conjugates in oral squamous cell carcinoma. *Oral Dis.* 2024;30(4):2039-50.
41. Pătru A, Şurlin V, Mărgăritescu C, Ciucă EM, Matei M, Dumitrescu D, Camen A. Immunohistochemical evaluation of D2-40, Galectin-3, Maspin and MCM7 expression in palate squamous cell carcinomas. *Rom J Morphol Embryol.* 2021;62(1):133-149.
42. Alves PM, Godoy GP, Gomes DQ, Medeiros AM, de Souza LB, da Silveira EJ, et al. Significance of galectins-1, -3, -4 and -7 in the progression of squamous cell carcinoma of the tongue. *Pathol Res Pract.* 2011;207(4):236-40.
43. Cela I, Capone E, Pece A, Lovato G, Simeone P, Colasante M, et al. LGALS3BP antibody-drug conjugate enhances tumor-infiltrating lymphocytes and synergizes with immunotherapy to restrain neuroblastoma growth. *J Transl Med.* 2025;23(1):431.