

The bFGF Can Improve Angiogenesis in Oral Mucosa and Accelerate Wound Healing

Reza Zare¹, Hamidreza Abdolsamadi², Sara Soleimani Asl³, Shahrbanoo Radi⁴, Hossein Bahrami⁵, Shokoofeh Jamshidi*⁶

Abstract

Background: The role of the basic fibroblast growth factor (bFGF) has well known in the angiogenesis and ulcer healing. In this study, we aimed to evaluate the effects of bFGF on tissue repair in a rat oral mucosal wound.

Methods: Musosal wound induced on the lip mucosa of rats and bFGF was injected along the edge of the mucosal defect immediately after surgery. The tissues were collected on days 3, 7 and 14 after the wound induction. The micro vessel density (MVD) and CD34 expression were done by histochemical studies.

Results: The bFGF significantly accelerated granulation tissue formation and MVD was increased three days after ulcer induction but decreased 14 days after surgery. The MVD was significantly higher in the bFGF-treated group. The wound area was decreased in all groups time-dependently and a statistically significant difference (p value?) was observed between the bFGF-treated group and untreated group. The wound area was smaller in the bFGF-treated group compared to the untreated group.

Conclusions: Our data demonstrated that bFGF can accelerated and facilitated wound healing.

Keywords: bFGF, Healing, Angiogenesis, Wound, Micro Vessel Density.

Introduction

Oral ulcer is one of the most common and painful oral diseases that develops following inflammation in tissue necrosis (1). The inflammatory cascade, immunological factors, infectious agents, and systemic conditions are the key causes that lead to expansion of oral ulcer (2). Stress oxidative following inflammatory cascade activation plays important role in the pathogenesis of oral ulcers (3).

The inflammatory response is active following the injury which is necessary in

healing process. In proliferation stage, the epithelial cells migrate upwards and regenerate the epidermis within 2-3 days and triggers by growth factors such as fibroblast growth factors (FGF) and transforming Growth Factor (TGF) (4). The FGFs constitute a family of cell signaling proteins that contains more than 10 members.

The FGFs are involved during migration of macrophages, fibroblasts, and endothelial cells to damaged tissues and also participate in the migration of epithelial cells for

1: Dental Research Center, Mashhad University of Medical Sciences, Mashhad, Iran.

2: Dental Research Center, Department of Oral Medicine, Hamadan University of Medical Sciences, Hamadan, Iran.

3: Department of Anatomy, School of Medicine, Hamadan University of Medical Sciences, Hamadan, Iran; Endometrium and Endometriosis Research Centre, Hamadan University of Medical Sciences, Hamadan, Iran.

4: Department of Oral Medicine, Hamedan University of Medical Sciences, Hamedan, Iran.

5: General Dentist, Private Practice, Hamadan, Iran.

6: Department of Oral and Maxillofacial Pathology, School of Dentistry, Dental Research Center, Hamadan University of Medical Sciences, Hamadan, Iran.

*Corresponding author: Shokoofeh Jamshidi; Tel: +98 8131310000; Email: dr.jamshidi39@gmail.com.

Received: 25 Apr, 2022; Accepted: 3 May, 2022

constituting a new epidermis (5, 6). The FGFs, especially FGF-2, able to induce the angiogenesis as *in vitro* and *in vivo* (6, 7). Furthermore, the effects of FGFs have been reported in the proliferation of angioblast in embryos, development of bone marrow and differentiation of myeloid cells (8). Therefore, in this study, we aimed to evaluate the effects of bFGF on angiogenesis in healing of oral ulcers in a rat wound model.

Materials and Methods

Twenty-seven adult Wistar male rats (250-300 g) were obtained from the animal facility of Hamadan University of Medical Sciences and kept under the standard condition ($55\pm 1\%$ humidity, 25 ± 1 °C, and with free access to food and water *ad libitum*). The animals were randomly divided into three groups ($n=9$, for each group): Intact control, oral ulcer, and bFGF-treated oral ulcer groups.

To provide an oral ulcer model, the rats were anesthetized by using pentobarbital (50 mg/kg) and an ulcer was induced at mandibular labial mucosa. A Whatman filter paper with 6 mm diameter was immersed in 50% acetic acid and pressed, then kept on the target area for 60 seconds to provide the ulcer. Following ulcer induction, the bFGF-treated group received a single submucosal injection of bFGF (Kaken, Japan), 3 µg in 6 µl normal saline).

To assess the ulcer healing, dimension of wound area was measured on days 0, 3, 7, and 14 by a ruler with an accuracy of 0.01 mm (9).

Histological studies

The animals were euthanized using phenobarbital and the tissues collected and were fixed in 10% formalin. After embedding the tissues in paraffin, they cut off into 4 µm sections. To assess the expression of CD34, five sections of each sample were evaluated by immunohistochemistry staining. Briefly, the sections were blocked in 30% H₂O₂-methanol solution for 5 min and incubated with the rabbit anti CD34 antibody (1:50) overnight at 4 °C, then incubated with the HRP-conjugated anti rabbit secondary antibody for 30 min. Next, the

slides were incubated with DAB chromogenic substrate and counterstained with Gill's hematoxylin. The stained sections were assessed by light microscope (Olympus BX41) and photographed by a digital camera attached to the microscope at a magnification of 40X.

A protocol described by Fox *et al.* was applied to assess the micro vessel density and the numbers of CD34⁺ micro vessels were counted by Analysis LS Starter software (10).

Statistical analysis

The data were presented as means \pm Standard deviation and analyzed by SPSS software (Version 20). The Nested Analysis of Variance and Bonferroni's multiple comparison test was used to compare the mean area of the ulcer and CD34⁺ cells between the different groups. The $p\leq 0.05$ was considered statistically significance.

Results

Effects of bEGF on the wound area in oral ulcer

The data analysis showed a reduction in the wound area time-dependently, with the highest area on day 3 (54.0 ± 52.14) and the lowest on day 14 (09.1 ± 99.5). There were significant differences between days 3, 7, and 14 ($p<0.001$). Administration of bEGF caused significant reduction in the dimension of wound area when compared to the ulcer group ($p<0.001$, Table 1). Like the ulcer group, the diminishing of wound area in the bFGF group was time-dependently, so the highest mean (22.11 ± 32.2) was related to day 3 and the lowest (51 ± 44) was in day 14. Administration of bFGF caused a remarkable reduction in the wound area compared to the untreated group ($p<0.001$) (Table 1).

The Nested Analysis of Variance of CD34⁺ cells revealed that the number of blood vessels increased at day 3 and then decreased at day 14 in both ulcer and bFGF groups (Fig. 1, Table 2). Injection of bFGF resulted in a remarkable increasing in average of CD34⁺ cells compared to the ulcer group ($p<0.001$). The highest expression of CD34 was on day 3 following administration of bFGF ($p<0.001$ compared to other days). There was a significant difference between day 0 of treatment compared to days 7 and 14 ($p<0.05$). Ultimately, the further analysis showed significant expression of CD34 in the bFGF-treated in compared to the un-treated ulcer group.

The bFGF Accelerates Wound Healing

Table 1. Comparison of the size of the wound area (mean±S.D) on days 0,3,7, and 14.

Groups	days	mean±SD
Ulcer	0	28.26±00
	3	14.52±0.54
	7	10.52±0.64
	14	5.99±1.09
bFGF- treated	0	28.26±00
	3	11.22±2.32
	7	4.34±1.32
	14	0.51±0.44

Table 2. Comparison the mean of CD34+ cell in the different groups.

Groups	days	Mean±SD	p value
Control	0	5.1±00	P<0.001
Ulcer	0	5.1±00	P<0.001
	3	9±37.21	
	7	7±27.15	
	14	7±7.21	
bFGF- treated	0	5.1±00	P<0.001
	3	14±23.25	
	7	10±70.36	
	14	10±57.51	

(a; p<0.001 vs. days 0, 7, and 14, b; p<0.001 vs. day 0 of ulcer group, c; P<0.001 vs. days 0, 7, and 14, d; p<0.05 vs. day 0 of bFgf- treated group).

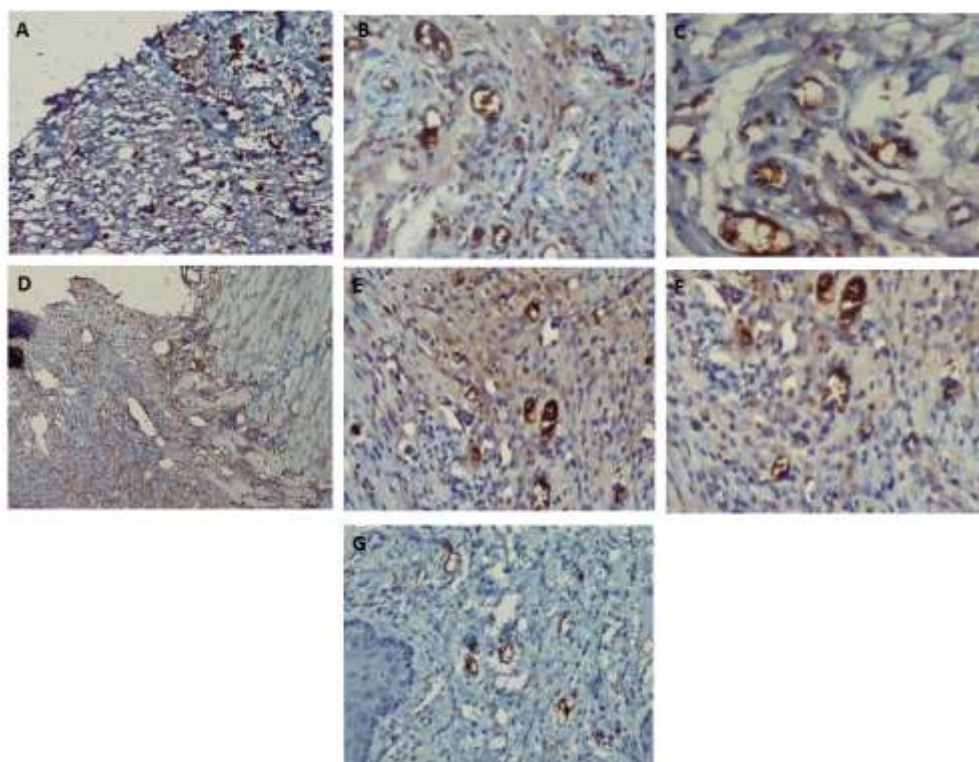


Fig. 1. Detection of CD34-positive cells in the oral mucosa of the 3rd (A), 7th (B), 14th (C) days after wound induction, 3rd (D), 7th (E), 14th (F) days of bFGF- treated, and control group (G) using immunohistochemical staining.

Discussion

In the present study, the formation of blood vessels increased until the third day but then decreased in both ulcer and bFGF- treated groups.

The wound healing process begins immediately after injury with various growth factors and cytokines and the granulation tissue develops progressively (11). This tissue is characterized by the formation of new and small blood vessels (angiogenesis) and the proliferation of fibroblasts on day 3 that confirms the results of this study for overexpression of CD34 until day 3. During the second week, the proliferation of fibroblasts occurred and the infiltration of leukocytes and blood vessels is significantly reduced, and resulted in the accumulation of the collagen (12). The FGFs stimulated the proliferation of mesodermal, ectodermal, and endodermal cells and are mitogenic for keratinocytes and fibroblasts (11). The bFGF involved in the formation of granulation tissue and angiogenesis, and increased the blood supply to the wound area, and played an important role in its healing (13). Kibe *et al.* reported that bFGF is involved in the proliferation, differentiation, and migration of keratinocytes into scar areas, causing neovascularization of granulation tissues in wound healing (14). In another study, the administration of bFGF in the infectious wounds of diabetic rats resulted in a significant angiogenesis, fibroblast proliferation, and collagen formation in compare to the un-treated group (15).

A study by Chakrabarti *et al.* showed that bFGF and collagen matrix hydrogel attenuated inflammation of burn wound, accelerated wound closure, and increased re-epithelialization and granulation tissue formation through activation of ERK and TRK pathway (16) that is consistent with the results of our study.

Hata *et al.* reported that the injection of bFGF into the palatal wounds improved the blood supply to the operated mucosa and underlying bone, result in tissue remodeling of the palate during growth (17). A study by Oda

et al. revealed that the effective concentration of bFGF varied in different tissues (9). For example, bFGF with both doses of 0.72 and 4.05 μg are effective on the skin lesion of mice (18). However, a dose of 4 μg bFGF has been reported to be effective on the ischemic liver and intestinal lesions (19) while a dose of 5 μg is sufficient for rabbit skin lesions (20).

A study by Ohshima *et al.* examined the healing effects of bFGF on oral ulcers and simultaneously wound healing process and caused the formation of granulation and improved the ulcer healing (21). Results of previous oral studies have shown that bFGF is effective in improving the proliferation of human PDL cells (22). The healing effect of bFGF was evaluated on dogs and found the formation of new cementum in these animals (23). Furthermore, the injection of bFGF resulted in an improvement in the tissue regeneration of atrophied salivary glands (24). Medeiros *et al.* reported that the local application of bFGF stimulated the proliferation of fibroblasts and lymphocytes, increased collagen synthesis in the rat model of skin wounds, and also improved wound tensile strength. The collagen fibers are important components in the extracellular matrices that are responsible for the tensile strength of wounds (25). The biological mechanism of bFGF in wound healing is not still clear but this growth factor seems to protect cell survival during stressful conditions (26), regulates migration and differentiation of target cells, and participate in angiogenesis (27).

In conclusion, the results of this study indicated that bFGF can increase the angiogenesis in the oral mucosa and thus facilitate and accelerate wound healing.

Acknowledgments

Acknowledgment: This manuscript is based on a research project approved by the Faculty of Dentistry, Hamedan University of Medical Sciences.

Conflict of Interest

None to declare.

References

1. Muñoz-Corcuera M, Esparza-Gómez G, González-Moles MA, Bascones-Martínez A. Oral ulcers: clinical aspects. A tool for dermatologists. Part I. Acute ulcers. *Clin Exp Dermatol.* 2009;34(3):289-94.
2. Ernawati DS, Surboyo MDC, Ayuningtyas NF, Nagoro AAB. Role of Inflammatory Cell Responses in Stimulating Fibroblasts in Diabetic Oral Ulcer after Treatment with Liquid Smoke of Coconut Endocarp: A Histological Assessment. *Eur J Dent.* 2021;15(1):71-76.
3. Yu Z, Jin C, Xin M, JianMin H. Effect of Aloe vera polysaccharides on immunity and antioxidant activities in oral ulcer animal models. *Carbohydrate Polymers.* 2009;75(2):307-11.
4. Woodley DT, O'Keefe EJ, Prunieras M. Cutaneous wound healing: a model for cell-matrix interactions. *J Am Acad Dermatol.* 1985;12(2 Pt 2):420-33.
5. Boilly B, Vercoutter-Edouart AS, Hondermarck H, Nurcombe V, Le Bourhis X. FGF signals for cell proliferation and migration through different pathways. *Cytokine Growth Factor Rev.* 2000;11(4):295-302.
6. Presta M, Andrés G, Leali D, Dell'Era P, Ronca R. Inflammatory cells and chemokines sustain FGF2-induced angiogenesis. *Eur Cytokine Netw.* 2009;20(2):39-50.
7. Zhu X-J, Liu Y, Dai Z-M, Zhang X, Yang X, Li Y, et al. BMP-FGF signaling axis mediates Wnt-induced epidermal stratification in developing mammalian skin. *PLoS Genet.* 2014;10(10):e1004687.
8. Shimabukuro Y, Ichikawa T, Takayama S, Yamada S, Takedachi M, Terakura M, et al. Fibroblast growth factor-2 regulates the synthesis of hyaluronan by human periodontal ligament cells. *J Cell Physiol.* 2005;203(3):557-63.
9. Oda Y, Kagami H, Ueda M. Accelerating effects of basic fibroblast growth factor on wound healing of rat palatal mucosa. *J Oral Maxillofac Surg.* 2004;62(1):73-80.
10. Fox SB, Harris AL. Markers of tumor angiogenesis: clinical applications in prognosis and anti-angiogenic therapy. *Invest New Drugs.* 1997;15(1):15-28.
11. Dantas Filho AM, Aguiar JLda, Rocha LsRdM, Azevedo ÂtM, Ramalho E, Medeiros AC. Effects of the basic fibroblast growth factor and its anti-factor in the healing and collagen maturation of infected skin wound. *Acta Cir Bras.* 2007;22:64-71.
12. Kumar V, Abbas Abul K, Fausto N, Mitchell R. *Robbins Basic Pathology.* 8th Edition, Saunders Elsevier. Philadelphia; 2010.
13. Matsumoto S, Tanaka R, Okada K, Arita K, Hyakusoku H, Miyamoto M, et al. The effect of control-released basic fibroblast growth factor in wound healing: histological analyses and clinical application. *Plast Reconstr Surg Glob Open.* 2013;1(6):e44.
14. Kibe Y, Takenaka H, Kishimoto S. Spatial and temporal expression of basic fibroblast growth factor protein during wound healing of rat skin. *Br J Dermatol.* 2000;143(4):720-7.
15. Broadley KN, Aquino AM, Hicks B, Ditesheim JA, McGee GS, Demetriou AA, et al. Growth factors bFGF and TGB beta accelerate the rate of wound repair in normal and in diabetic rats. *Int J Tissue React.* 1988;10(6):345-53.
16. Chakrabarti S, Mazumder B, Rajkonwar J, Pathak MP, Patowary P, Chattopadhyay P. bFGF and collagen matrix hydrogel attenuates burn wound inflammation through activation of ERK and TRK pathway. *Sci Rep.* 2021;11(1):3357.
17. Hata Y, Kawanabe H, Hisanaga Y, Taniguchi K, Ishikawa H. Effects of basic fibroblast growth factor administration on vascular changes in wound healing of rat palates. *Cleft Palate Craniofac J.* 2008;45(1):63-72.
18. Uhl E, Barker JH, Bondar I, Galla TJ, Leiderer R, Lehr HA, Messmer K. Basic fibroblast growth factor accelerates wound healing in chronically ischaemic tissue. *Br J Surg.* 1993;80(8):977-80.

19. Fu X, Sheng Z, Wang Y, Ye Y, Xu M, Sun T, et al. Basic fibroblast growth factor reduces the gut and liver morphologic and functional injuries after ischemia and reperfusion. *J Trauma*. 1997;42(6):1080-5.
20. Mustoe TA, Pierce GF, Morishima C, Deuel TF. Growth factor-induced acceleration of tissue repair through direct and inductive activities in a rabbit dermal ulcer model. *J Clin Invest*. 1991;87(2):694-703.
21. Ohshima M, Sato M, Ishikawa M, Maeno M, Otsuka K. Physiologic levels of epidermal growth factor in saliva stimulate cell migration of an oral epithelial cell line, HO-1-N-1. *Eur J Oral Sci*. 2002;110(2):130-6.
22. Takayama S, Murakami S, Miki Y, Ikezawa K, Tasaka S, Terashima A, et al. Effects of basic fibroblast growth factor on human periodontal ligament cells. *J Periodontal Res*. 1997;32(8):667-75.
23. Murakami S, Takayama S, Ikezawa K, Sltimabukuro Y, Kitamura M, Nozaki T, et al. Regeneration of periodontal tissues by basic fibroblast growth factor. *J Periodontal Res*. 1999;34(7):425-30.
24. Van Setten GB. Basic fibroblast growth factor in human saliva: detection and physiological implications. *Laryngoscope*. 1995;105(6):610-2.
25. Stenberg BD, Phillips LG, Hokanson JA, Heggors JP, Robson MC. Effect of bFGF on the inhibition of contraction caused by bacteria. *J Surg Res*. 1991;50(1):47-50.
26. Arundina I, Diyatri I, Surboyo MDC, Monica E, Afanda NM. Growth factor stimulation for the healing of traumatic ulcers with liquid rice hull smoke. *J Taibah Univ Med Sci*. 2021;16(3):431-439.
27. Kottakis F, Polytaichou C, Foltopoulou P, Sanidas I, Kampranis SC, Tsihchlis PN. FGF-2 regulates cell proliferation, migration, and angiogenesis through an NDY1/KDM2B-miR-101-EZH2 pathway. *Mol Cell*. 2011;43(2):285-98.