

The Pro-Oxidant, Apoptotic and Anti-Angiogenic Effects of Selenium Supplementation on Colorectal Tumors Induced by 1,2-Dimethylhydrazine in BALB/C Mice

Mohammed Saeed Ali*¹, Rasha Mohamed Hussein*^{1,2},
Mohamed Ahmed Kandeil³

Abstract

Background: Selenium is a mineral that showed both pro- and anti-oxidant activities in various disease models. In this study, we evaluated the anti-tumor effect of selenium against 1,2-dimethylhydrazine (DMH)-induced colorectal cancer in BALB/C mice and its effect on apoptosis and angiogenesis.

Methods: Colorectal cancer was induced by subcutaneous injection of DMH (20 mg/kg body weight) in BALB/C mice once weekly for 20 weeks. Selenium (200 mg/L) was given to DMH plus selenium-treated group in the drinking water for the next 3 months.

Results: The DMH plus selenium-treated group exhibited significantly lower expression of cloned caudal-type homeobox gene -2 (CDX-2) and vascular endothelial growth factor (VEGF) but higher caspase-3 expression level at $p < 0.001$ compared to the DMH-treated group. Moreover, a decrease in the reduced glutathione content and glutathione peroxidase activity but an increase in the malondialdehyde content were observed at $p < 0.001$. Both macroscopic and microscopic examination of the colorectal tissues confirmed the results.

Conclusions: The anti-tumor effect of selenium against an induced colorectal cancer in mice is attributed to its pro-oxidant, anti-angiogenic and apoptotic effects.

Keywords: Angiogenesis, Apoptosis, Cancer, Mineral, Oxidative Stress.

Introduction

Colorectal cancer (CRC) represents the third prevalent cancer in the world after breast and lung cancers (1). CRC occurs as a result of changes in both environmental and genetic factors that convert the normal mucosa of the colon to dysplasia and eventually to invasive colon cancer (2). CDX2 is a recently identified cloned caudal-type homeobox gene, encoding a transcription factor that plays an important role in differentiation and proliferation of the intestinal epithelial cells. It is viewed as a sensitive marker of gastrointestinal tract tumors with high expression level in 55% of cases with intestinal adenocarcinoma (3).

1,2-dimethylhydrazine (DMH) is a pro-carcinogen of the colon that causes DNA methylation, mismatch, and mutation (4). 1,2-dimethylhydrazine (DMH) is a pro-carcinogen of the colon. It undergoes a series of activation reactions in the liver to form azoxymethane and methylazoxymethanol which are eventually converted to the active metabolite, methyl diazonium ions that cause DNA methylation, mismatch, and mutation (4, 5). Importantly, DMH produces histopathological and molecular characteristics similar to that of the human colon cancer (4). Therefore, it is widely used to induce colorectal cancer experimentally (6, 7).

1: Department of Biochemistry, Faculty of Pharmacy, Beni-Suef University, 62514, Beni-Suef, Egypt.

2: Department of Pharmaceutics and Pharmaceutical Technology, College of Pharmacy, Mutah University, 61710, Al-Karak, Jordan.

3: Department of Biochemistry, Faculty of Veterinary Medicine, Beni-Suef University, Egypt.

*Corresponding author: Mohammed Saeed Ali; Tel: +98 0201146714125, Fax: +98 0201146714125, E-mail: mohamedali@pharmbsu.edu.eg & Rasha Mohamed Hussein; Tel: +98 0201200136515; Fax: +98 0201200136515; E-mail: rasha.hussein@pharm.bsueg.edu.eg

Received: 1 Aug, 2019; Accepted: 6 Aug, 2019

Selenium is one of the trace elements that is found in many dietary products such as cereals, meat, fish and milk (8). Selenium exhibits antioxidant activity and shows a protective effect against colorectal, prostate and lung cancers (9). Interestingly, selenium also exhibits a pro-oxidant effect by oxidizing thiols and generation of ROS causing cytotoxicity to cells (10). Hence, administration of selenium showed an anti-tumor activity against thyroid, head and neck cancers as well as melanoma cell metastasis (11).

Angiogenesis and apoptosis are two essential processes involved in tumor growth and metastasis. Vascular endothelial growth factor (VEGF) is an angiogenic molecule responsible for tumor progression (12). It plays a significant role in all steps of angiogenesis starting from matrix dissolution, proliferation of endothelial cells, shaping into tubes until the formation of a vascular lumen (13). Therefore, various drugs had been developed to inhibit angiogenesis through targeting VEGF and hence affecting the tumor growth (14). Apoptosis or the programmed cell death is responsible for the deletion of unwanted, damaged or infected cells from the body (15). It is a highly conserved and regulated process that maintains the normal homeostasis of cells. The apoptotic pathways usually lead to activation of a group of proteases called caspases. In this process, caspase-3 is the effector protease which catalyzes the cleavage of many cellular proteins (16).

In the current study, we investigated the pro-oxidant activity of selenium as well as its effect on angiogenesis and apoptosis processes in a mouse model of DMH- induced colorectal cancer.

Materials and methods

Chemicals

1,2 dimethylhydrazine dihydrochloride ($C_2H_{10}Cl_2N_2$) was purchased from Acros Organics, Thermo Fisher Scientific, Belgium. Selenium (Cat No: 229865) was supplied from Sigma Aldrich, St. Louis, USA.

DNA Extraction and Methylation-Specific PCR (MSP)

Fifteen Male BALB/c mice (4 weeks old, approximately 18 g body weight) were obtained from Animal House Colony, Pharmacology and Chemistry Research Center, Misr University and

Technology Park. Animals were housed in plastic cages five animal per cage in a room free from chemical contamination, illuminated artificially (12-h dark/ 12 light cycle) and controlled thermally (25 ± 2 °C) at the Animal House Lab., Faculty of Pharmacy, Beni-Suef University. Animals were fed with standard pellet diet and had free access to water. This study was approved by the Animal Ethics Committee of Beni-Suef University (permit number: 018-56). Animals were treated in accordance with the Guide for the Care and Use of Laboratory Animals (8th edition, National Academies Press).

Experimental design

After 1 week of acclimatization period, animals were divided into 3 groups (5 mice each) as follows:

(1) Control group: received subcutaneous (SC.) injection of 1 mM EDTA solution once weekly for 20 weeks.

(2) DMH-induced group: animals received SC. injection of DMH (20 mg/kg.b wt.) dissolved in 1 mM EDTA at pH 6.5 once weekly for 20 weeks as the dose mentioned previously in (17).

(3) DMH + Selenium treated group: animal received SC. injection of DMH once weekly for 20 weeks then treated with selenium for the next 3 months in a dose of 200 mg/L (equivalent to 50 mg/100 g B.wt.) supplied in the drinking water as was previously mentioned in (9).

At the end of the experiment, animals were sacrificed by cervical decapitation under anesthesia and the whole colon was dissected, opened longitudinally and washed with saline to remove feces. A part of the colon was used for histopathological examination and immunohistochemistry analysis while the rest of it was homogenized in phosphate buffered saline (PBS), centrifuged at 336 RCF for 20 min and the supernatants were collected and stored at -80 °C freezer for the biochemical measurements.

Histopathological examination

Macroscopic examination

The dissected colons were examined for the presence of tumor plaques and tumor size was measured by a skilled pathologist as described previously (18).

Microscopic examination

Colon tissues underwent an automated tissue processing to prepare them for staining with Hematoxylin and Eosin (H&E) and examination for any pathological changes (19).

Immunohistochemical analysis of CDX-2, VEGF and caspase 3

For immunohistochemical examination, paraffin-embedded sections were first dewaxed, followed by an antigen-retrieval process and a series of blocking steps. After that, the sections were incubated separately overnight with the following primary antibodies:

CDX-2 monoclonal antibody (M3636, Dako Omnis, UK), VEGF polyclonal antibody (RB-222-R7, Thermo Fisher Scientific, USA), caspase-3 polyclonal antibody (PA1-29157, Thermo Fisher Scientific, USA). The slides were washed thoroughly and then incubated with secondary antibody: (HRP Envision kit, DAKO, Agilent, USA). Slides were then washed and incubated with 3, 3'-diaminobenzidine (DAB) for visualization. Finally, slides were viewed by using a light microscope (Labomed, Labo America Inc., USA) and images were captured by a digital camera under 400 X magnification. Quantification of CDX-2, VEGF, and caspase-3 signals was done on five independent fields per sample using Image J analysis software.

Estimation of the oxidative stress parameters

Malondialdehyde (MDA) was estimated as thiobarbituric acid reactive substances (TBARS) in colon tissue homogenates using the method of Mihara and Uchiyama (20). Reduced glutathione was estimated according to Sedlak and Lindsay method (21). Glutathione peroxidase activity was measured by GSH-PX ELISA Kit (Cat No: MBS032696) supplied from MyBioSource, Inc. San Diego, USA according to the provided instructions.

Statistical analysis

All data were analyzed by SPSS software version 22 (SPSS Inc., Chicago, Illinois). One Way Analysis of

Variance (ANOVA) followed by post hoc Tukey's test was used to compare the differences among groups. All data are represented as mean \pm SE. P value < 0.05 was considered as statistically significant.

Results

Effect of selenium on DMH- induced colorectal cancer

The macroscopic examination of colons showed that DMH-induced group exhibited multiple plaque masses with irregular shape and larger size (average size 0.3 cm) compared to normal control. However, the DMH + Selenium treated group showed a localized, decreased tumor size (average size 0.15 cm) without ulcer formation or hemorrhage (Fig. 1a). By histopathological examination of the colon tissues by H&E stain, we found a multifocal localization of tumors in DMH treated group compared to control group. Moreover, the DMH-induced group showed severe hyperplasia, dysplasia, nuclear atypia, hyperchromasia, nuclear vesicularity, mitotic figures, and basement membrane destruction compared to normal control group (Fig. 1b). Interestingly, administration of selenium resulted in a severe lymphoplasmocytic reaction, lymphoid hyperplasia, inflammatory reaction and necrosis with moderate hyperplasia compared to the DMH treated group (Table 1). These findings indicate that selenium increased necrosis of the tumor tissues that resulted in a decrease in the tumor size and severity.

Effect of selenium on CDX-2 expression

The colorectal tissues of mice were immunohistochemically stained with CDX-2 which is a highly expressed marker in colorectal adenocarcinoma (3). The results showed that CDX-2 was more expressed in the DMH-induced group by 6.5 fold compared to the control group at $p < 0.001$. Importantly, administration of selenium could effectively decrease the CDX-2 expression level by 36% compared to the DMH-induced group at $p < 0.001$ (Figs. 2a and 2b).

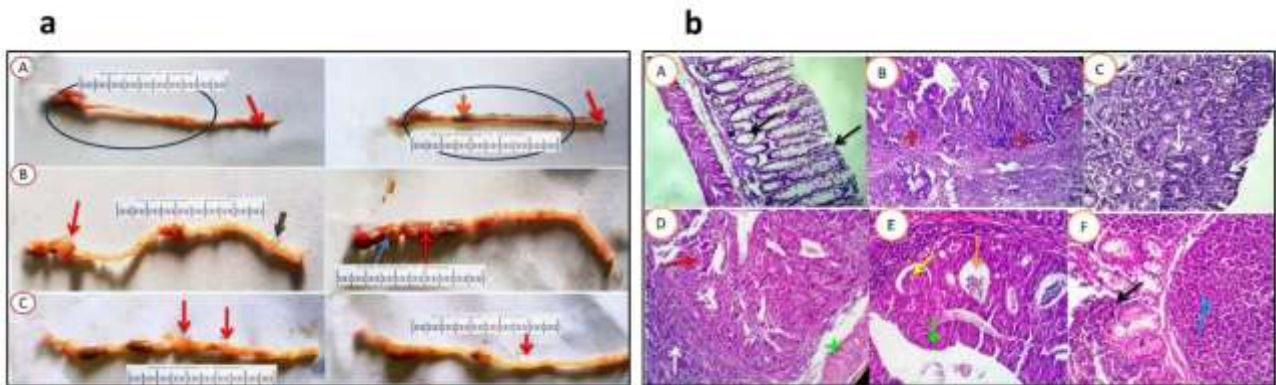


Fig. 1. Macroscopic and microscopic examination of colon tissues from the studied groups. **a:** Macroscopic examination of the colons **A:** Control group showing colon (Blue circle) and rectum (Red arrows) with a normal shape, size and contours. Brown ingestible materials are seen (Brown arrow). The serosal blood vessels are normal. **B:** DMH-induced group showing an increase in the size and contour of the colon. Multiple tumor masses at different locations are seen, they were large in size (0.2-0.4 cm), irregular in shape and plugging through the serosa with a glassing surface (Red arrows). Superficial hemorrhagic spots are observed (Blue arrow). The rectum shows a small nodule (black arrow). **C:** DMH + Selenium treated group showing localization and reduction in the size of the tumor masses (0.1- 0.2 cm) with a nearly complete resolution (Red arrows). Neither hemorrhages nor ulcers are seen.

b: Microscopic examination of colon tissues by H&E staining.

A: Control group showing normal histomorphological structures of the colon mucosal epithelial lining and glands (black arrows). **B and C:** DMH- treated group showing invasive adenocarcinoma grade II, with mucous cystic carcinomatous irregular glands having destructed basement membranes and invading the submucosa (B, red stars). Some glands are papillary or papillary cystic, other glands are tubular or acinar in shape with enlarged hyperchromatic nuclei having typical and atypical mitotic activities (C, white arrows). **D, E and F:** DMH + Selenium-treated group showing localized invasive adenocarcinoma (**D, red arrows**), a large proliferated lymphoid nodule (**D, white arrow**) is seen around the tumor mass completely replacing the mucosa and submucosa and it extends to compress the muscular coat (**D, green star**). The malignant cells present in trabecular, villous, acinar and cystic glandular forms (**E, green arrow**). The latter showing aggregations of necrotic debris (**E, yellow arrows**) and inflammatory cells (**E, brown arrows**). Some cases showed hyperplasia of lymphoid follicles with prominent germinal center (**F, blue arrows**) and focal submucosal round cell infiltration with superficial ulceration (**F, black arrow**). H&E X200.

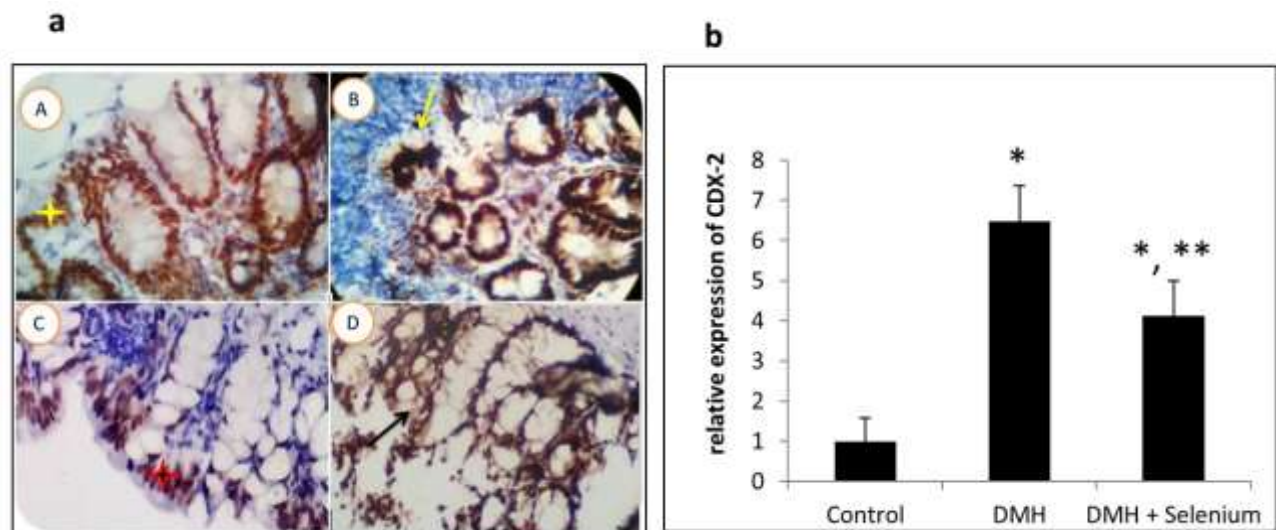


Fig. 2. The CDX-2 expression in colorectal tissues from the studied group. **a:** Photomicrograph of mice colon showing the expression level of CDX 2. **A:** Control group showing normal CDX-2 reactivity as a light brown color (A, yellow star). **B:** DMH-induced group showing an intense deep brown nuclear stainability. (B, yellow arrow). **C and D:** DMH + Selenium treated group showing normal mucosal and glandular epithelial nuclear reactivity to CDX-2 as a light brown stainability (C, red star and D, black arrow). X 400. **b:** Quantification of the expression level of CDX-2. Column figure shows the relative expression level of CDX-2 among groups. N=5/ group. Data are represented as mean ± SE. *significantly different from control group ($p < 0.001$), **significantly different from the DMH-treated group ($p < 0.001$).

Table 1. The scores of macroscopic and microscopic examination of colorectal tissues of control, DMH and DMH + Selenium treated groups:

Lesion	Control group	DMH group	DMH + Selenium treated group
Tumor localization	–	Multifocal	Focal
Average tumor size (cm)	-	0.3	0.15
Hyperplasia	-	+++	++
Metaplasia	-	-	-
Dysplasia	-	+++	+
Nuclear atypia	-	+++	+
Hyperchromacia	-	+++	+
Nuclear vesicularity	-	+++	+
Mitotic figures	-	+++	+
Broken basement membrane	-	+++	+
Lymphoplasmocytic reaction	-	+	+++
Lymphoid hyperplasia	+	+	+++
Inflammatory reaction		+	+++
Degenerative changes	-	++	+
Necrosis	-	+	+++

–: absent, +: mild, ++: moderate, +++: severe

Effect of selenium on the oxidative stress biomarkers

There was no statistically significant difference in GSH or MDA concentrations between DMH-treated group and the control group after administration of DMH for 20 weeks. However, administration of selenium significantly increased MDA concentration and decreased GSH concentrations in DMH + selenium-treated group compared to the DMH-treated group. There was a significant difference in MDA concentration between DMH + selenium treated group and the control group (Figs. 3A and 3B). Moreover, there was a statistically significant difference in glutathione peroxidase activity between the control group and DMH-induced group ($p < 0.05$). However, administration of selenium significantly decreased glutathione peroxidase activity in DMH + Selenium treated group compared to both the control and DMH-treated groups ($p < 0.05$) (Fig. 3C). These results suggest that selenium increased the oxidative stress via a pro-oxidant effect.

Effect of selenium on caspase-3 expression

We found that, caspase-3 expression was increased by eight folds in the DMH-induced group compared to the control group at $p < 0.001$. However, administration of selenium significantly increased the expression of caspase 3 by 2 folds compared to DMH-induced group and 16 folds compared to the control group at $p < 0.001$ (Figs. 4a and 4b). The results refer to the ability of selenium to induce apoptosis and tissue necrosis.

Effect of selenium on VEGF expression

We found that VEGF expression was increased in the DMH-induced group by 12 fold compared to the control group at $p < 0.001$. However, administration of selenium decreased the expression of VEGF by 63% compared to DMH-treated group at $p < 0.001$ (Figs. 5a and 5b). These results indicate that selenium has a significant anti-angiogenic effect that may also contribute to its anti-tumor activity.

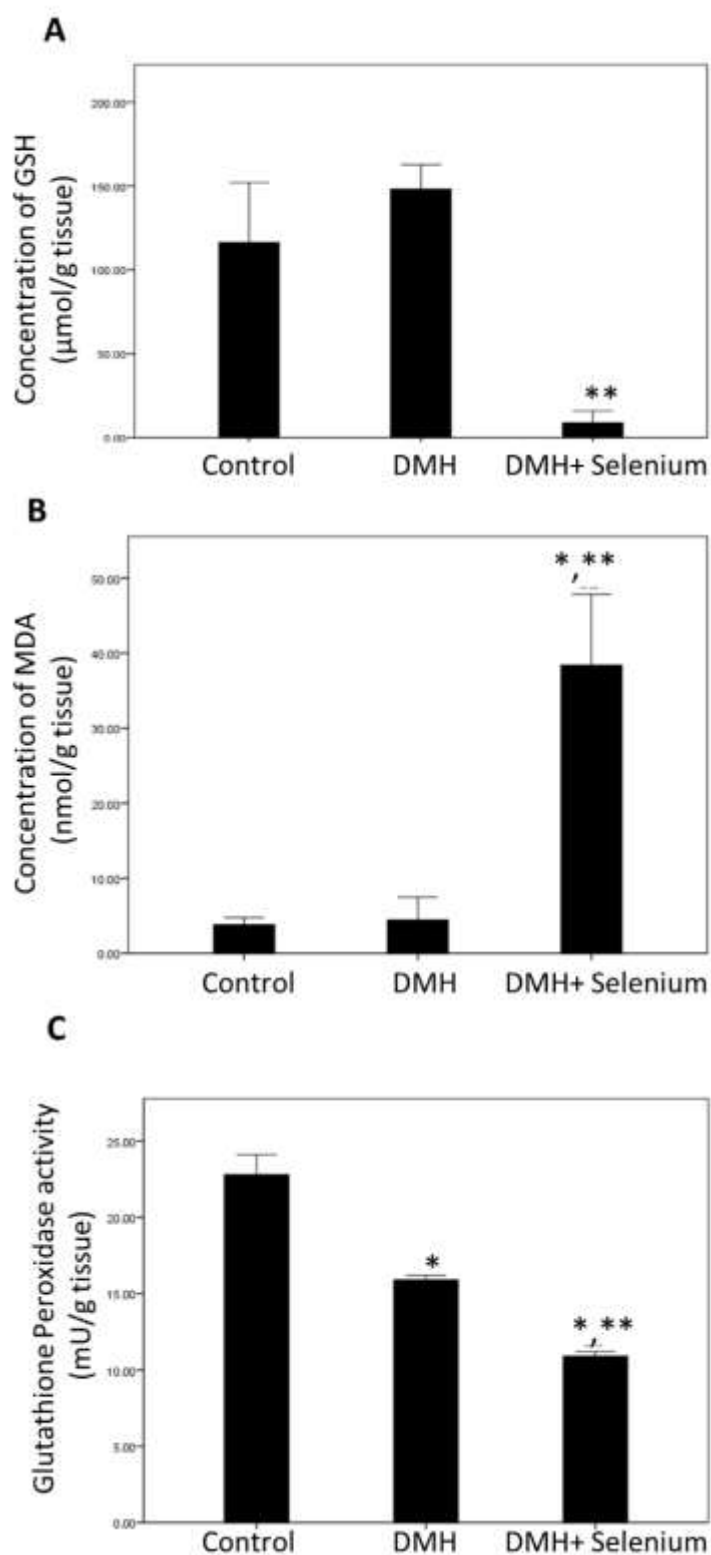


Fig. 3. Effect of selenium on oxidative stress parameters. (A): The concentration of GSH, (B): the concentration of MDA, (C): The Glutathione peroxidase activity among the control, DMH and DMH + Selenium -treated groups. N= 5/ group. Data are represented as mean ± SE. *significantly different from normal control (p< 0.05), **significantly different from DMH group (p< 0.05).

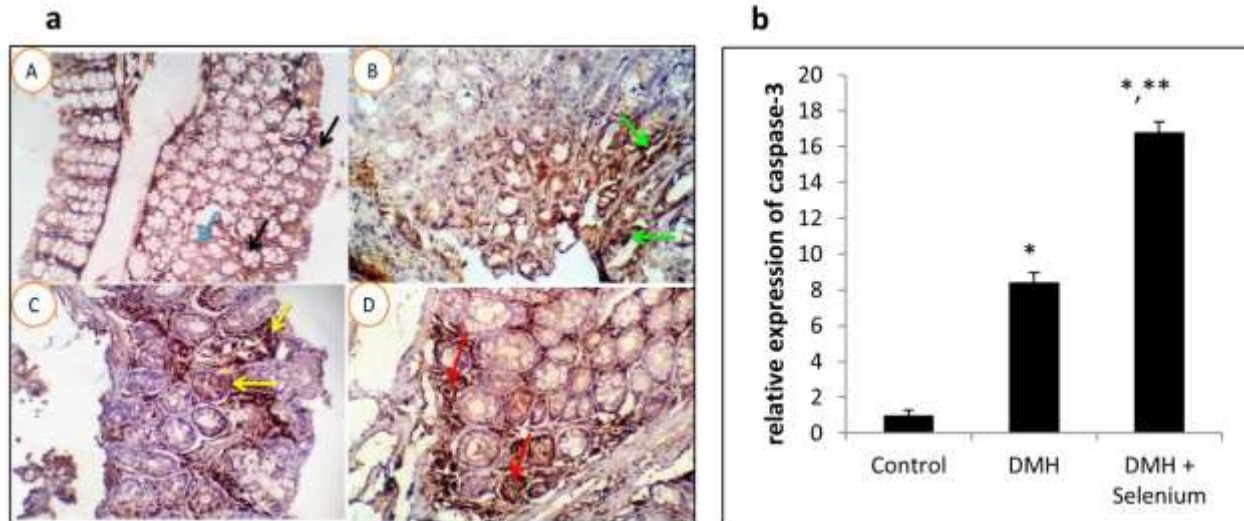


Fig. 4. Immunohistochemical analysis of caspase-3 in colon tissues. **a:** Photomicrograph of mice colons showing the expression level of Caspase-3. **A:** Control group showing normal colon epithelial lining with a light brown cytoplasmic and nuclear staining reactivity (Black arrows). However, a very few cells were positively stained (blue arrow) **B:** DMH-induced group showing the malignant cells with an intense deep brown nuclear and cytoplasmic stainability (green arrows). **C and D:** DMH + Selenium treated group showing comparatively higher expression of caspase 3 as shown in a moderate number of tumor transformed glandular cells (yellow and red arrows in C and D). X 400. **b:** Quantification of the expression level of caspase-3. Column figure shows the relative expression level of caspase-3 among groups. N= 5/ group. Data are represented as mean \pm SE. *significantly different from control group ($p < 0.001$), **significantly different from the DMH-treated group ($p < 0.001$).

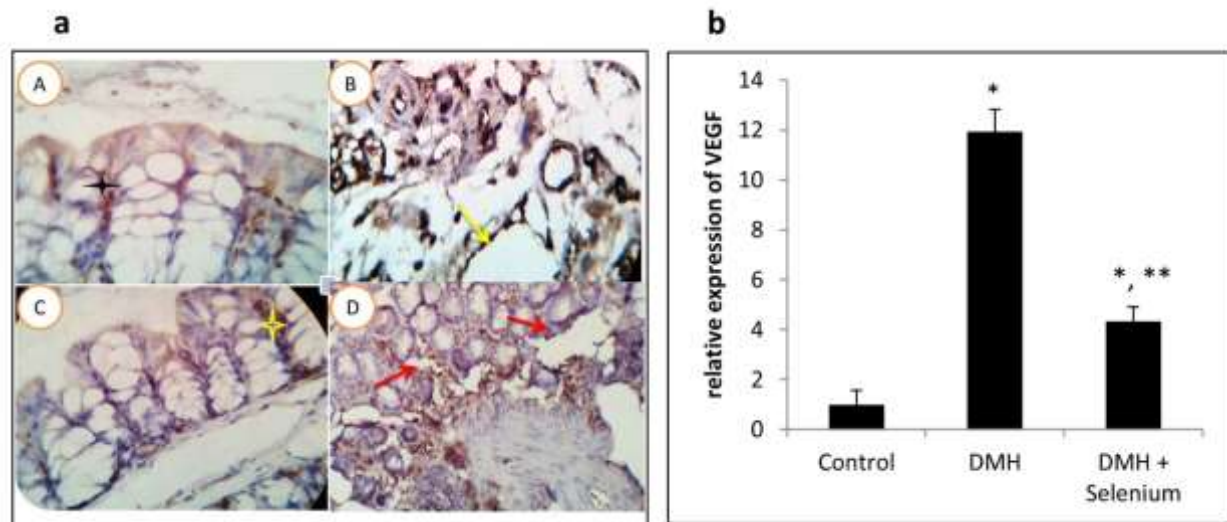


Fig. 5. Immunohistochemistry analysis of VEGF in colon tissues. **a:** Photomicrograph of mice colons showing the expression level of VEGF. **A:** Control group showing the VEGF expression as a light brown cytoplasmic reactivity in the colon mucosal and glandular epithelium (A, black star). **B:** DMH-induced group showing high expression (deep brown cytoplasmic stainability) in the mucosal malignant cells and in the stromal proliferated vascular endothelium (B, yellow arrow). **C and D:** DMH + Selenium -treated group showing very weak stromal cells reactivity to VEGF (C, yellow star) or weakly expressed in the mucosal, submucosal stromal cells and vascular endothelial cells (D, red arrows). X 400. **b:** Quantification of the expression level of VEGF. Column figure shows the relative expression level of VEGF among groups. N= 5/ group. Data are represented as mean \pm SE. *significantly different from control group ($p < 0.001$), **significantly different from the DMH-treated group ($p < 0.001$).

Discussion

Oxidative stress plays an important role in cancer progression (22). Specifically, it was found that DMH administration induced an oxidative imbalance in colorectal cancers (23). In our study, we observed no statistically significant difference in GSH and MDA contents (although tending to increase) between DMH-induced group and the control group. This is compatible with the previous findings that MDA level may not necessarily increase but rather it was decreased with increasing tumor progression and size in many cancer types (24, 25). Interestingly, this decreased lipid peroxidation was accompanied by an increased glutathione content in the intestinal cells to confer selective media for the neoplastic cells growth (25, 26). Moreover, the increased GSH content in cancer cells may be attributed to the increased cell proliferation, an essential step in the cancer pathogenesis (25, 26). These findings were observed previously in the distal part of the colon after 14 weeks of DMH injection (27). Glutathione peroxidase activity was decreased significantly in the DMH-induced group compared to the control group which is consistent with the previous finding in which the antioxidant enzymes such as catalase and superoxide dismutase were decreased after 14 weeks of DMH injection (26).

Remarkably, selenium acts as both an anti-oxidant and pro-oxidant agent in various experimental conditions (28). This effect is a concentration-dependent ranging from an anti-oxidant effect at micro molar concentrations to a pro-oxidant effect at higher concentrations (29). Selenium can produce an anti-oxidant effect through its incorporation into selenoenzymes such as glutathione peroxidase (9). Therefore, administration of selenium at micro doses resulted in an increased activity of the anti-oxidant enzymes such as superoxide dismutase in the liver cells and could protect against the hepatocellular carcinoma (30). On the other hand, selenium may exhibit a pro-oxidant effect through its reaction with thiols and generation of superoxides ($O_2^{\bullet-}$) especially at high doses (28). Therefore, selenium was proposed as a cancer chemotherapeutic agent both *in vitro* and *in vivo*

against many cancer types such as human prostate cancer cells, primary lymphoma cultures, HepG2 cells, pulmonary adenocarcinoma cells, brain tumor cell lines and colon cancer cell lines (31-33). In our study, administration of a large dose of selenium for long periods increased the oxidative stress in the colon cells and participated in the observed anti-tumor effect which is compatible with previous findings (34).

Interestingly, the high concentrations of selenium were found to increase the apoptosis in prostate cancer, osteosarcoma cells and human myeloid HL-60 cells (35) (36, 37). Compatible with this, we found that chronic administration of selenium increased caspase-3 and hence induction of apoptosis.

VEGF plays a crucial role in angiogenesis and cancer invasion (38). In the current study, we found that VEGF expression was increased after the chronic DMH administration. This can be explained as larger tumors produce more VEGF and since the tumor size in the DMH-induced group was larger than that of the DMH + Selenium treated group, lower expression of VEGF was observed in the DMH + Selenium treated group. It was found previously that sodium selenite decreased the angiogenesis in a chemically induced mammary gland cancer (39). Interestingly, there is an inverse relation between oxidative stress and angiogenesis since increasing H_2O_2 concentration in the pancreatic adenocarcinoma led to a decrease in VEGF expression via degradation of HIF 1 α and ultimately the angiogenesis process (40). Our results support this correlation since we found an increase in the oxidative stress accompanied by a significant decrease in VEGF expression in an attempt by selenium to combat the induced colorectal cancer. Our results are compatible with the previous study in which selenium based compounds increased apoptosis and decreased VEGF in breast cancer (41). The current study demonstrated that the anti-tumor effect of selenium against a DMH - induced colorectal cancer in mice is mediated via its effect on increasing the oxidative stress, apoptosis while decreasing the angiogenesis.

Acknowledgment

The authors would like to thank Dr. Sayed Elattar, Pathologist, for his help in histopathology and

immunohistochemistry. The authors declare that they have no conflict of interest.

References

1. Saleem T, Attya A, Ahmed E, Ragab S, Abdallah MA, Omar H. Possible protective effects of quercetin and sodium gluconate against colon cancer induction by dimethylhydrazine in mice. *Asian Pac J Cancer Prev.* 2015;16:5823-8.
2. Umesalma S, Sudhandiran G. Differential inhibitory effects of the polyphenol ellagic acid on inflammatory mediators NF- κ B, iNOS, COX-2, TNF- α , and IL-6 in 1, 2-dimethylhydrazine-induced rat colon carcinogenesis. *Basic & clinical pharmacology & toxicology.* 2010;107(2):650-5.
3. Werling RW, Yaziji H, Bacchi CE, Gown AM. CDX2, a highly sensitive and specific marker of adenocarcinomas of intestinal origin: an immunohistochemical survey of 476 primary and metastatic carcinomas. *The American journal of surgical pathology.* 2003;27(3):303-10.
4. Giftson JS, Jayanthi S, Nalini N. Chemopreventive efficacy of gallic acid, an antioxidant and anticarcinogenic polyphenol, against 1, 2-dimethyl hydrazine induced rat colon carcinogenesis. *Investigational new drugs.* 2010;28(3):251-9.
5. Aranganathan S, Nalini N. Efficacy of the potential chemopreventive agent, hesperetin (citrus flavanone), on 1,2-dimethylhydrazine induced colon carcinogenesis. *Food and chemical toxicology : an international journal published for the British Industrial Biological Research Association.* 2009;47(10):2594-600.
6. Bordini HP, Kremer JL, Fagundes TR, Melo GP, Conchon-Costa I, Da Silva SS, et al. Protective effect of metformin in an aberrant crypt foci model induced by 1, 2-dimethylhydrazine: Modulation of oxidative stress and inflammatory process. *Molecular Carcinogenesis.* 2016.
7. Sangeetha N, Aranganathan S, Nalini N. Silibinin ameliorates oxidative stress induced aberrant crypt foci and lipid peroxidation in 1, 2 dimethylhydrazine induced rat colon cancer. *Investigational new drugs.* 2010;28(3):225-33.
8. Filippini T, Cilloni S, Malavolti M, Violi F, Malagoli C, Tesaro M, et al. Dietary intake of cadmium, chromium, copper, manganese, selenium and zinc in a Northern Italy community. *Journal of Trace Elements in Medicine and Biology.* 2018.
9. Rohr-Udilova N, Sieghart W, Eferl R, Stoiber D, Björkhem-Bergman L, Eriksson LC, et al. Antagonistic effects of selenium and lipid peroxides on growth control in early hepatocellular carcinoma. *Hepatology.* 2012;55(4):1112-21.
10. Lee KH, Jeong D. Bimodal actions of selenium essential for antioxidant and toxic pro-oxidant activities: the selenium paradox. *Molecular medicine reports.* 2012;5(2):299-304.
11. Zeng H, Combs Jr GF. Selenium as an anticancer nutrient: roles in cell proliferation and tumor cell invasion. *The Journal of nutritional biochemistry.* 2008;19(1):1-7.
12. Verma S, Das P, Kumar VL. Chemoprevention by artesunate in a preclinical model of colorectal cancer involves down regulation of β -catenin, suppression of angiogenesis, cellular proliferation and induction of apoptosis. *Chemico-biological interactions.* 2017;278:84-91.
13. Liu J-G, Zhao H-J, Liu Y-J, Liu Y-w, Wang X-L. Effect of two selenium sources on hepatocarcinogenesis and several angiogenic cytokines in diethylnitrosamine-induced hepatocarcinoma rats. *Journal of Trace Elements in Medicine and Biology.* 2012;26(4):255-61.
14. Becherirat S, Valamanesh F, Karimi M, Faussat A-M, Launay J-M, Pimpie C, et al. Discontinuous Schedule of Bevacizumab in Colorectal Cancer Induces Accelerated Tumor Growth and Phenotypic Changes. *Translational oncology.* 2018;11(2):406-15.
15. Devarajan E, Sahin AA, Chen JS, Krishnamurthy RR, Aggarwal N, Brun A-M, et al. Down-regulation of caspase 3 in breast cancer: a possible mechanism for chemoresistance. *Oncogene.* 2002;21(57):8843.

16. Porter AG, Jänicke RU. Emerging roles of caspase-3 in apoptosis. Cell death and differentiation. 1999;6(2):99.
17. Svitina H, Kyryk V, Skrypkina I, Kuchma M, Bukreieva T, Areshkov P, et al. Placenta-derived multipotent cells have no effect on the size and number of DMH-induced colon tumors in rats. Experimental and therapeutic medicine. 2017;14(3):2135-47.
18. Tanaka T. Development of an inflammation-associated colorectal cancer model and its application for research on carcinogenesis and chemoprevention. International journal of inflammation. 2012;2012.
19. Bancroft JD, Floyd AD, Suvarna SK. Bancroft's Theory and Practice of Histological Techniques. 2013.
20. Uchiyama M, Mihara M. Determination of malonaldehyde precursor in tissues by thiobarbituric acid test. Analytical biochemistry. 1978;86(1):271-8.
21. Sedlak J, Lindsay RH. Estimation of total, protein-bound, and nonprotein sulfhydryl groups in tissue with Ellman's reagent. Analytical biochemistry. 1968;25:192-205.
22. Abass SA, El-Hamid NMA, Abouzed TK, El-Shishtawy MM. Chemosensitizing effect of *Alpinia officinarum* rhizome extract in cisplatin-treated rats with hepatocellular carcinoma. Biomedicine & Pharmacotherapy. 2018;101:710-8.
23. El-Khadragy MF, Nabil HM, Hassan BN, Tohamy AA, Waaer HF, Yehia HM, et al. Bone Marrow Cell Therapy on 1, 2-Dimethylhydrazine (DMH)-Induced Colon Cancer in Rats. Cellular Physiology and Biochemistry. 2018;45(3):1072-83.
24. Pillai MG, Thampi B, Menon VP, Leelamma S. Influence of dietary fiber from coconut kernel (*Cocos nucifera*) on the 1, 2-dimethylhydrazine-induced lipid peroxidation in rats. The Journal of nutritional biochemistry. 1999;10(9):555-60.
25. Dani V, Goel A, Vaiphei K, Dhawan D. Chemopreventive potential of zinc in experimentally induced colon carcinogenesis. Toxicology letters. 2007;171(1-2):10-8.
26. Moulahoum H, Nagy A-L, Djerdjouri B, Clichici S. Precancerous ACF induction affects their regional distribution forsaking oxidative stress implication in 1, 2-dimethylhydrazine-induced colon carcinogenesis model. Inflammopharmacology. 2017;1-12.
27. Moulahoum H, Boumaza BMA, Ferrat M, Nagy A-L, Olteanu DE, Bounaama A, et al. Aberrant crypt foci are regionally affected by zinc treatment in a 1, 2-dimethylhydrazine induced colon carcinogenesis model. Journal of Trace Elements in Medicine and Biology. 2018;47:21-30.
28. Collery P. Strategies for the Development of Selenium-based Anticancer Drugs. Journal of Trace Elements in Medicine and Biology. 2018.
29. Uğuz AC, Nazıroğlu M, Espino J, Bejarano I, González D, Rodríguez AB, et al. Selenium modulates oxidative stress-induced cell apoptosis in human myeloid HL-60 cells through regulation of calcium release and caspase-3 and-9 activities. Journal of Membrane Biology. 2009;232(1-3):15.
30. Wang H, Zhang J, Yu H. Elemental selenium at nano size possesses lower toxicity without compromising the fundamental effect on selenoenzymes: comparison with selenomethionine in mice. Free Radical Biology and Medicine. 2007;42(10):1524-33.
31. Valdiglesias V, Pásaro E, Méndez J, Laffon B. In vitro evaluation of selenium genotoxic, cytotoxic, and protective effects: a review. Archives of toxicology. 2010;84(5):337-51.
32. Wallenberg M, Misra S, Björnstedt M. Selenium cytotoxicity in cancer. Basic & clinical pharmacology & toxicology. 2014;114(5):377-86.
33. Fernandes AP, Gandin V. Selenium compounds as therapeutic agents in cancer. Biochimica et Biophysica Acta (BBA)-General Subjects. 2015;1850(8):1642-60.
34. Guo C-H, Hsia S, Hsiung D-Y, Chen P-C. Supplementation with Selenium yeast on the prooxidant-antioxidant activities and anti-tumor effects in breast tumor xenograft-bearing mice. The Journal of nutritional biochemistry. 2015;26(12):1568-79.
35. Khan S, Ullah MW, Siddique R, Liu Y, Ullah I, Xue M, et al. Catechins-Modified Selenium-Doped Hydroxyapatite Nanomaterials for Improved Osteosarcoma Therapy Through Generation of Reactive Oxygen Species. Frontiers in oncology. 2019;9:499.
36. Ghosh J. Rapid induction of apoptosis in prostate cancer cells by selenium: reversal by

metabolites of arachidonate 5-lipoxygenase. Biochemical and biophysical research communications. 2004;315(3):624-35.

37. Chen X-j, Duan F-d, Zhang H-h, Xiong Y, Wang J. Sodium selenite-induced apoptosis mediated by ROS attack in human osteosarcoma U2OS cells. Biological trace element research. 2012;145(1):1-9.

38. Lee S-y, Kim HJ, Oh SC, Lee D-H. Genipin inhibits the invasion and migration of colon cancer cells by the suppression of HIF-1 α accumulation and VEGF expression. Food and Chemical Toxicology. 2018.

39. Rayman MP. Selenium in cancer prevention: a review of the evidence and mechanism of action.

Proceedings of the Nutrition Society. 2005;64(4):527-42.

40. Wilkes JG, O'Leary BR, Du J, Klinger AR, Sibenaller ZA, Doskey CM, et al. Pharmacologic ascorbate (P-AscH⁻) suppresses hypoxia-inducible Factor-1 α (HIF-1 α) in pancreatic adenocarcinoma. Clinical & experimental metastasis. 2018:1-15.

41. Collery P, Veena V, Harikrishnan A, Desmaele D. The rhenium(I)-diselenoether anticancer drug targets ROS, TGF-beta1, VEGF-A, and IGF-1 in an in vitro experimental model of triple-negative breast cancers. Investigational new drugs. 2019.